**DATE**

10/12/21

**PRESENTING CLINICAL SIGNS**

History: **Presenting Complaint:** Vomiting, Bloody Diarrhea. **Date:** 10-10-2021 **Notes:** Was mom's cat; current owner has been taking care of for at least a year. Has history of eosinophilic granulomas (show up on mouth, lips, head, legs, belly) so has had extensive diet trials; currently on Rabbit; owner has also used Venison. About 4 days ago soft stool started; has been intermittently soft/loose/firm/ with some mucus and blood since then. Was eating ok until past 1-2 days and vomited today. Cat was found as kitten and taken into rescue; left hind limb appeared to have been previously fractured and was healing abnormally (possible joint fracture); surgical correction would have been too invasive, so no intervention done. Cat has managed well for past 2 years and is even able to jump small distances. Today though she has been more lethargic and not able to jump onto bed like she normally does. **Assessment:** r/o IBD, pancreatitis, gastroenteritis, neoplasia. **Plan:** Recommend to Owner Hospitalization, IV catheter, fluid therapy, bloodwork, and further treatment as needed. Also discussed abdominal ultrasound on Tuesday; recommended if no significant improvement tomorrow.

**PATIENT**

Peaches Swinson

**SPECIES**

Feline

**BREED**

Domestic Longhair

**SEX**

Spayed Female

Current Medications: Gabapentin, Buprenex, Vitamin B12, Metronidazole, Acepromazine, Cerenia.

Lab Results: Attached separately.

Radiographs: Xray Abdomen 2 View WNL. Attached separately.

Date of Previous IntraPet Ultrasound: No previous IntraPet scans.

Sedation: not needed

Stat Report: not requested

**AGE**

10/10/11

**ULTRASONOGRAPHIC EXAMINATION OF THE ABDOMEN****Urinary System**

The urinary bladder is moderately distended with anechoic urine. The Bladder wall, trigone, ureteral papillae and visible urethra (to a depth of 2cm) appear normal with no evidence of wall thickening, mucosal irregularities, masses or cystic calculi.

The left kidney has a normal shape and size (4.34 cm). Overall echogenicity is slightly hyperechoic with poor corticomedullary distinction and a typical 1:3 cortex:medulla ratio. There is no evidence of perinephric inflammation or effusion. Pyelectasia was noted and measured 0.39 cm. Small, non-obstructive nephroliths were noted. There is no evidence of infarcts or hydroureter. Renal vasculature is normal.

The right kidney has a normal shape and size (4.41 cm). Overall echogenicity is slightly hyperechoic with poor corticomedullary distinction and a typical 1:3 cortex:medulla ratio. There is no evidence of perinephric inflammation or effusion. Slight pyelectasia was noted and measured 0.13 cm. Small, non-obstructive nephroliths were noted. There is no evidence of infarcts or hydroureter. Renal vasculature is normal.

**WEIGHT**

10.8 lbs

**INTERPRETED BY**

Kathleen Sennello  
DVM, MS, Diplomate  
ACVIM (Small Animal  
Internal Medicine)

**HOSPITAL NAME**

Animal Emergency  
Hospital

**Adrenal Glands**

The left adrenal gland is normal in size measuring 0.3 cm at the caudal pole. It is observed in its normal position cranial to the left renal artery. It is normal in appearance (uniformly hypoechoic) and shape with no evidence of a mass effect.

**REFERRING VET**

Dr. Martinoli

The region of the right adrenal (between right cranial kidney and vena cava) is unremarkable, but the adrenal is not distinctly visualized. No evidence of a mass effect.

**INVOICE**

92346

**Spleen**

The spleen is subjectively normal in size, echotexture is homogenous, and the splenic capsule is smooth with no irregularities. The blood flow through the hilus and splenic parenchyma appears normal. No focal parenchymal abnormalities are visualized.

### **Liver**

The liver is subjectively normal in size, and echogenicity with smooth peripheral margins. The parenchyma is homogenous echotexture. The visible portions of the vasculature and biliary tract appear normal. No focal nodules or cystic lesions are observed. The gallbladder lumen is moderately distended. The wall of the gallbladder is not thickened and has a smooth mucosal surface. Luminal contents are primarily anechoic. The cystic and common bile ducts are normal/not visible.

### **Gastrointestinal**

The stomach is significantly dilated with ingesta minimal luminal contents. It measures at a normal thickness of <0.36cm with some variability due to the presence of rugal folds. The distinction of the gastric wall layers is adequate and there is no impression of reduced peristaltic activity. No masses or focal lesions were observed.

The visualized areas of duodenum, jejunum and ileum have a relatively uniform diameter with minimal fluid distension. Wall thickness is normal. Bowel loops follow a curvilinear path with distinct wall layering maintaining the typical 1:3 muscularis:mucosa layer ratio. The duodenum measured as normal and the jejunum measured as normal (0.21 cm). Visualized peristalsis appears appropriate. There were no focal lesions consistent with obstruction or a mass effect observed.

The ileocecal junction was visualized and exhibited normal intact wall layering and is subjectively of normal thickness. Sections of colon are visualized with formed fecal material and gas shadowing distally. There is no observed focal or generalized colon wall thickening or loss of layering.

### **Pancreas**

The pancreas is prominent and mottled compared to the surrounding isoechoic mesentery. There is no evidence of nodules or cystic lesions. There is no evidence of regional mesenteric inflammation or fluid.

### **Free Abdomen**

Evaluation of the peritoneal cavity did not reveal any evidence of effusion. There is a lymphadenomegaly present. The mesenteric lymph nodes measured 0.29 cm and 0.1 cm. There was no evidence of a caudal aortic thrombus at the bifurcation. The omentum is hyperechoic around the prominent lymph nodes.

## **ULTRASONOGRAPHIC FINDINGS**

### **PRIMARY FINDINGS:**

- Dilated stomach with shadowing ingesta. Correlate with feeding history. If the patient was fasted then consider the possibility of foreign material such as hairball, etc., delayed gastric emptying or less likely a partial obstruction.
- Prominent, mottled pancreas. The pancreatic changes are most consistent with moderate pancreatitis/pancreatic infiltration. I recommend fPLI testing and continued monitoring for improvement or possible development of a pancreatic abscess. Consider FNA if not improving.
- Prominent mesenteric lymph nodes. The prominent abdominal lymph nodes are most consistent with reactive lymphadenitis or lymphoid hyperplasia. Neoplastic infiltration is considered less likely.

### **SECONDARY FINDINGS:**

- Mildly decreased corticomedullary distinction in both kidneys with mild pyelectasia and pinpoint, non-obstructive nephroliths. Mild loss of corticomedullary distinction in both kidneys could be consistent with chronic degenerative disease or interstitial nephrosis.

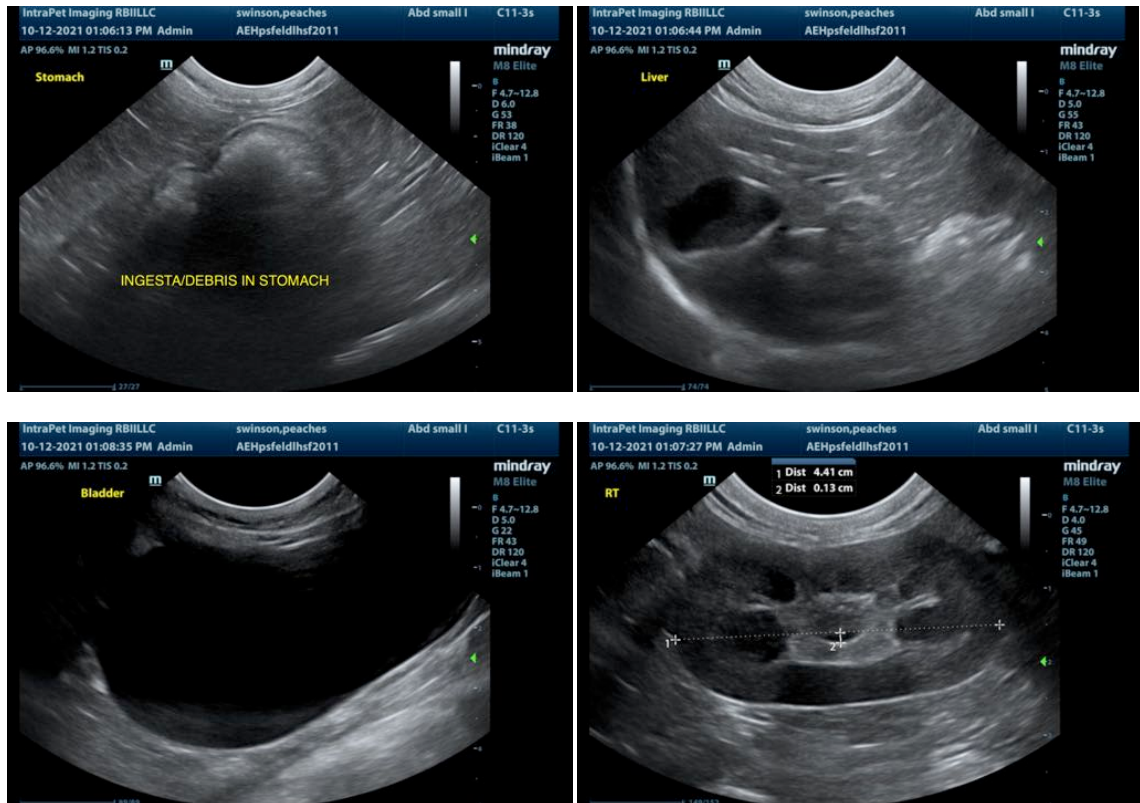
## INTERPRETATION OF THE FINDINGS & FURTHER RECOMMENDATIONS

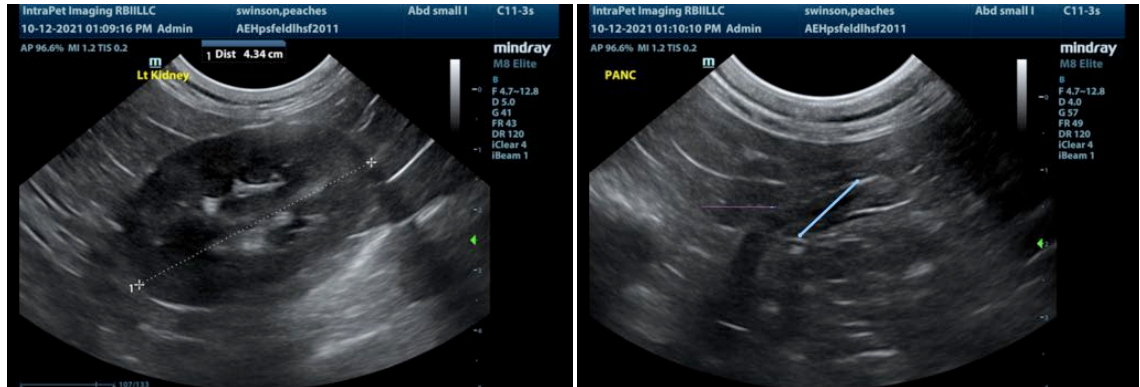
A focal lesion causing the reported vomiting and diarrhea is not observed. The pancreas appears prominent and is consistent with mild inflammation or previous inflammation. Additionally the stomach is somewhat dilated with shadowing material that could be normal for this individual or consistent with gastric foreign material.

The bowel appears relatively normal, but there are many causes for vomiting and diarrhea that cannot be diagnosed by ultrasound alone. If metabolic disease testing (including thyroid evaluation) make metabolic disease unlikely then consider primary causes of GI upset such as GI parasitism, dietary indiscretion, mild pancreatitis, bacterial dysbiosis, food allergy, IBD or less likely intestinal neoplasia.

In older patients with more chronic symptoms, I would most strongly consider food allergy, IBD, and intestinal neoplasia.

- Recommend diet trial with a novel protein/hydrolyzed prescription diet
- Recommend GI panel (PLI, TLI, cobalamin and folate) to further evaluate for pancreatitis/small intestinal disease.
- I recommend starting a probiotic
- If symptoms are progressing consider obtaining GI biopsies





The information and recommendations provided are based on the images presented by the referring veterinarian. No evaluation can be communicated regarding pathology that was not visible in the image/video clips provided.

Thank you for this referral. If the clinical or image interpretation does not parallel your findings or if I can be of any further assistance please contact me.

Kathleen Sennello DVM,MS, Diplomate ACVIM (Small animal Internal Medicine)  
kathleen.sennello@sonopath.com