



PATIENT

Otis Croxon

PRESENTING CLINICAL SIGNS

Current Problem List: Splenic Mass (found on rads 9/27/21) Presenting Complaint: Patient presented 9/27/21 for vomiting and diarrhea. Abdominal radiographs and labwork were obtained. Labwork (Chem, CBC) were unremarkable. Radiographs of the abdomen noted that the splenic tail margins are irregular and there is a round mass lesion measuring approximately 3.4 cm in diameter. Patient presenting for AUS today for further staging. Pertinent Diagnostic Results: Chemistry / CBC performed 9/27/21 within normal limits

SPECIES

Canine

BREED

Boston Terrier

ULTRASONOGRAPHIC EXAMINATION OF THE ABDOMEN

Urinary System

SEX

Neutered Male

The urinary bladder is moderately distended with anechoic urine. The Bladder wall, trigone, ureteral papillae and visible urethra (to a depth of 2cm) appear normal with no evidence of wall thickening, mucosal irregularities, masses or cystic calculi.

AGE

10.9 Years

The prostate is normal in size (0.47 cm) and shape for this neutered male dog. The parenchyma is homogenous and the external margins are smooth. The prostatic urethra appears normal with no evidence of irregularity, invasion, mass effect or calculi.

WEIGHT

24 Pounds

The left kidney has a normal shape and size (5.0 cm). Overall echogenicity is normal with adequate corticomedullary distinction and a typical 1:3 cortex:medulla ratio. There is no evidence of perinephric inflammation or effusion. There is no evidence of pyelectasia, nephroliths, infarcts or hydroureter. Renal vasculature is normal.

The right kidney has a normal shape and size (4.84 cm). Overall echogenicity is normal with adequate corticomedullary distinction and a typical 1:3 cortex:medulla ratio. There is no evidence of perinephric inflammation or effusion. There is no evidence of pyelectasia, nephroliths, infarcts or hydroureter. Renal vasculature is normal.

INTERPRETED BY

Kathleen Sennello DVM,
MS, Diplomate ACVIM
(Small Animal Internal
Medicine)

Adrenal Glands

IMAGING PERFORMED BY

Loetitia Saint-Jacques, RVT

The left adrenal gland is normal in size measuring 0.48 cm at the caudal pole. It is observed in its normal position cranial to the left renal artery. It is normal in appearance (uniformly hypoechoic) and shape with no evidence of a mass effect.

HOSPITAL NAME

Truckee Meadows VH

The right adrenal gland is normal in size measuring 0.78 cm at the caudal pole. It is observed in its normal position between the cranial aspect of the right kidney and the caudal vena cava. It is normal in appearance (uniformly hypoechoic) and shape with no evidence of a mass effect.

Spleen

REFERRING VET

Dr. Rachel Kuester

The spleen is large in size. The spleen echotexture is heterogenous and mottled, the splenic capsule is smooth with no irregularities. The blood flow through the hilus and splenic parenchyma appears normal. There are numerous moderate sized, irregular, hyperechoic foci throughout the splenic parenchyma with a concentration in the cranial aspect of the spleen. No discreet mass effects are visualized, but the parenchyma is irregular. The splenic capsule is slightly bulging and irregular in some areas, and there are numerous irregular hyperechoic foci.

INVOICE

26229

Liver

DATE

10/12/21

The liver is subjectively normal in size, and echogenicity with smooth peripheral margins. The parenchyma is heterogenous in echotexture with subtle, indistinct focal mottling. The visible portions of



PATIENT

Otis Croxon the vasculature and biliary tract appear normal. There are too numerous to count hypoechoic foci visualized within the hepatic parenchyma. They are small, varying in size from 0.15-0.30 cm. Findings could be consistent with severe mottling or even hypoechoic nodules.

SPECIES

Canine The gallbladder lumen is moderately distended. The wall of the gall bladder is not thickened and has a smooth mucosal surface. Luminal contents are primarily anechoic. The cystic and common bile ducts are normal/not visible.

BREED

Gastrointestinal

Boston Terrier The stomach contains minimal luminal contents. It measures at a normal thickness of <0.7cm with some variability due to the presence of rugal folds. The distinction of the gastric wall layers is adequate and there is no impression of reduced peristaltic activity. No masses or focal lesions were observed.

SEX

Neutered Male The visualized areas of duodenum, jejunum and ileum have a relatively uniform diameter with minimal fluid distension. Wall thickness is normal. Bowel loops follow a curvilinear path with distinct wall layering maintaining the typical 1:3 muscularis:mucosa layer ratio. Duodenum wall measured 0.44 cm. Jejunum wall measured 0.39 cm. Visualized peristalsis appears appropriate. There were no focal lesions consistent with obstruction or a mass effect observed.

AGE

10.9 Years The ileocecal junction was visualized and exhibited normal intact wall layering and is subjectively of normal thickness. Sections of colon are visualized with formed fecal material and gas shadowing distally. There is no observed focal or generalized colon wall thickening or loss of layering.

WEIGHT

24 Pounds **Pancreas**

The pancreas is prominent and mottled compared to the surrounding isoechoic mesentery. There is no evidence of nodules or cystic lesions. There is no evidence of regional mesenteric inflammation or fluid.

INTERPRETED BY

Kathleen Sennello DVM,
MS, Diplomate ACVIM
(Small Animal Internal
Medicine)

Free Abdomen

Evaluation of the peritoneal cavity did not reveal any evidence of effusion. Mild lymphadenomegaly is present with a prominent gastric lymph node at 0.70 cm. The Medial iliac nodes appear normal and there was no evidence of a caudal aortic thrombus at the bifurcation. The omentum is generally of normal uniform echogenicity.

IMAGING PERFORMED BY

Loetitia Saint-Jacques, RVT

Other

A brief view of the heart was submitted. No significant pericardial effusion was seen.

HOSPITAL NAME

Truckee Meadows VH

PRIMARY FINDINGS

REFERRING VET

Dr. Rachel Kuester

- Large, mottled, irregular spleen with numerous hyperechoic foci – The diffuse splenic changes are non-specific and could be consistent with lymphoid hyperplasia, extramedullary hematopoiesis, infiltrative neoplasia, inflammation, other. Cytology or histopathology would be necessary to get a definitive diagnosis. In general, hyperechoic foci are thought to be less worrisome for an underlying neoplastic condition. This could be benign change and would need sampling to confirm.

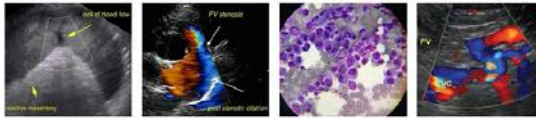
INVOICE

26229

- Prominent pancreas with mottled parenchyma – The pancreatic changes are most consistent with age-related parenchymal remodeling, potentially secondary to a prior inflammatory episode, early fibrosis or chronic pancreatitis.

DATE

10/12/21



PATIENT

Otis Croxon

- Heterogeneous liver with numerous small, hypoechoic foci – These changes could be consistent with severe mottling, but small metastatic lesions cannot be excluded as a possibility.

SPECIES

Canine

SECONDARY FINDINGS

- Mild mesenteric lymphadenopathy – The prominent abdominal lymph nodes are most consistent with reactive lymphadenitis or lymphoid hyperplasia. Neoplastic infiltration is considered less likely.

BREED

Boston Terrier

INTERPRETATION OF THE FINDINGS & FURTHER RECOMMENDATIONS

A large, isolated, focal splenic mass is not observed, but the parenchyma is uniformly mottled, and there are hyperechoic foci. This trends towards a benign process, but this cannot be definitively confirmed without histopathology (cytology may be useful, but not the gold standard). Options moving forward include splenectomy with histopathology or fine needle aspirate and continued monitoring if changes appear most consistent with a benign process. Additionally, there are numerous hypoechoic foci in the liver. This is most likely severe mottled, but small neoplastic foci cannot be excluded as a possibility. Consider fine needle aspirate of the liver to try to obtain more information. Recommend 3-view thoracic radiographs.

SEX

Neutered Male

AGE

10.9 Years

WEIGHT

24 Pounds

INTERPRETED BY

Kathleen Sennello DVM,
MS, Diplomate ACVIM
(Small Animal Internal
Medicine)

IMAGING PERFORMED BY

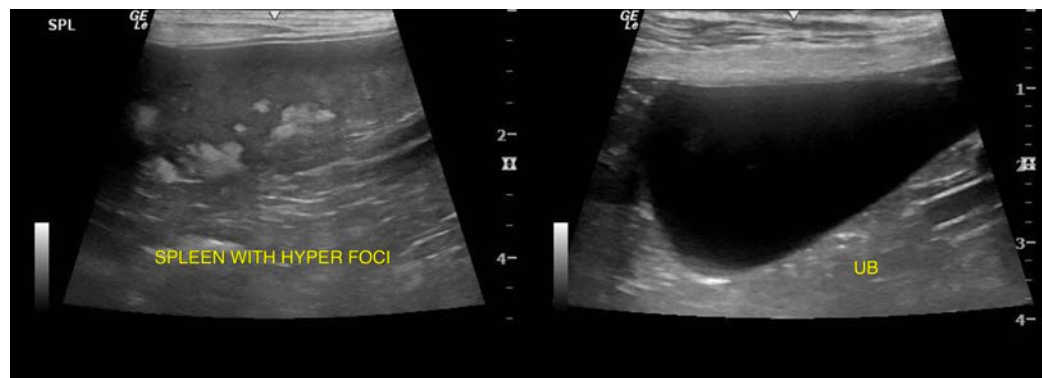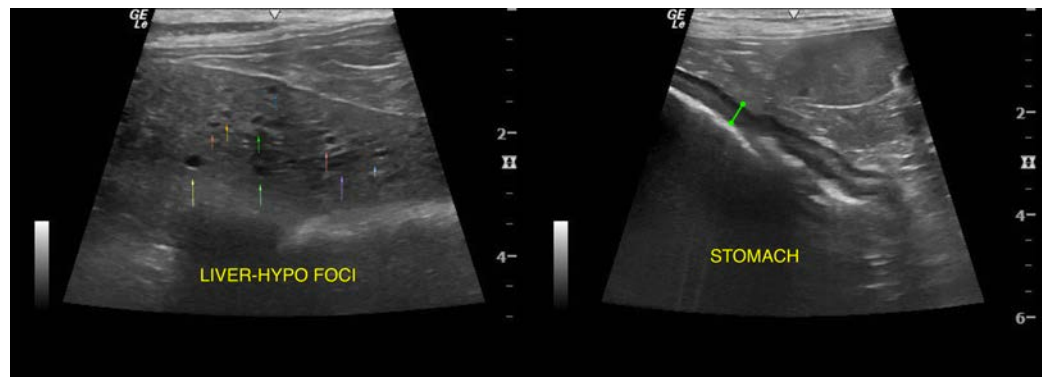
Loetitia Saint-Jacques, RVT

HOSPITAL NAME

Truckee Meadows VH

REFERRING VET

Dr. Rachel Kuester



INVOICE

26229

DATE

10/12/21



PATIENT

Otis Croxon

SPECIES

Canine

BREED

Boston Terrier

SEX

Neutered Male

AGE

10.9 Years

WEIGHT

24 Pounds

INTERPRETED BY

Kathleen Sennello DVM,
MS, Diplomate ACVIM
(Small Animal Internal
Medicine)

IMAGING PERFORMED BY

Loetitia Saint-Jacques, RVT

HOSPITAL NAME

Truckee Meadows VH

REFERRING VET

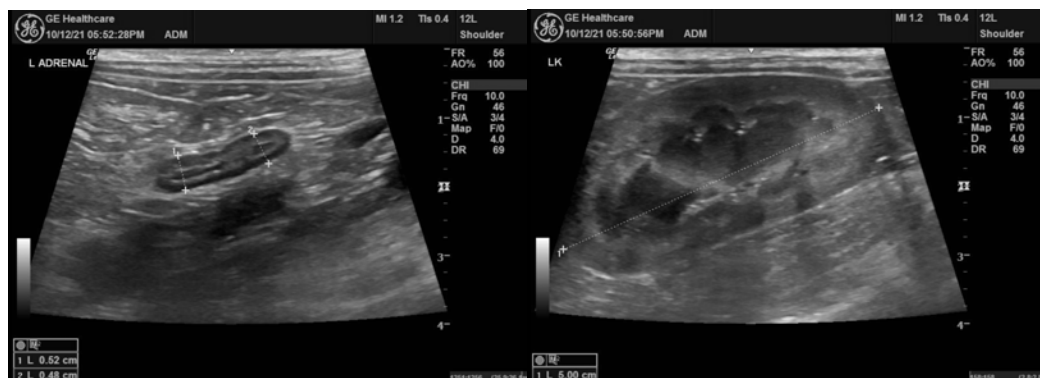
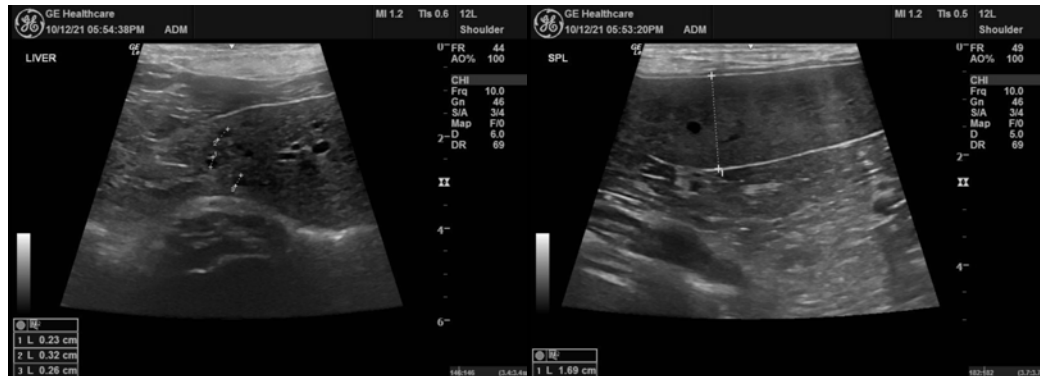
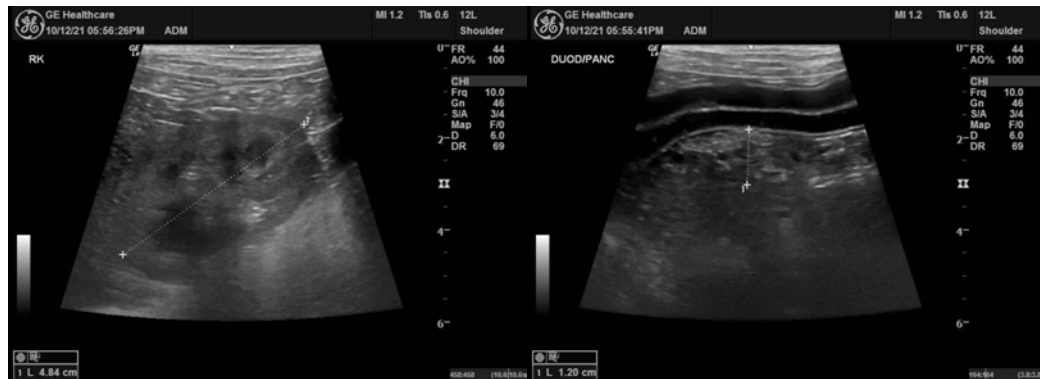
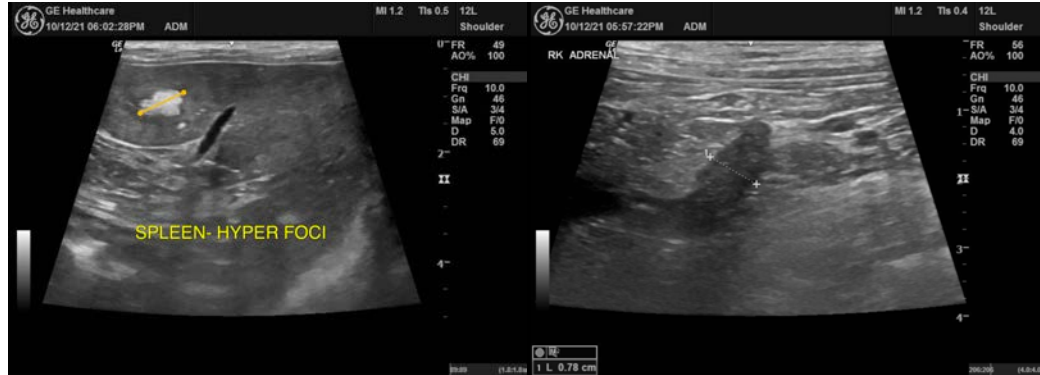
Dr. Rachel Kuester

INVOICE

26229

DATE

10/12/21





PATIENT

Otis Croxon

The information and recommendations provided are based on the images presented by the referring veterinarian. No evaluation can be communicated regarding pathology that was not visible in the image/video clips provided.

SPECIES

Canine

Thank you for this referral. If the clinical or image interpretation does not parallel your findings or if I can be of any further assistance please contact me.

BREED

Boston Terrier

Kathleen Sennello DVM,MS, Diplomate ACVIM (Small animal Internal Medicine)

kathleen.sennello@sonopath.com

SEX

Neutered Male

AGE

10.9 Years

WEIGHT

24 Pounds

INTERPRETED BY

Kathleen Sennello DVM,
MS, Diplomate ACVIM
(Small Animal Internal
Medicine)

**IMAGING PERFORMED
BY**

Loetitia Saint-Jacques, RVT

HOSPITAL NAME

Truckee Meadows VH

REFERRING VET

Dr. Rachel Kuester

INVOICE

26229

DATE

10/12/21