



PATIENT

Benny Pierce

SPECIES

Canine

BREED

Shih Tzu

SEX

Neutered Male

AGE

11 Years

WEIGHT

14.9 Pounds

INTERPRETED BY

Kathleen Sennello DVM,
MS, Diplomate ACVIM
(Small Animal Internal
Medicine)

**IMAGING
PERFORMED BY**

Dr. Tam Mengine

HOSPITAL NAME

Stoney Creek VH

REFERRING VET

Dr. Tam Mengine

INVOICE

26208

DATE

10/12/21

PRESENTING CLINICAL SIGNS

Acute onset of vomiting and diarrhea yesterday, bloodwork showed neutrophilia (21.5k), ALT 240, ALP 634, CPL abnormal. ALT and ALP normal at time of last bloodwork (8/20). Minimal reaction to probe pressure today, though patient had buprenorphine on board.

ULTRASONOGRAPHIC EXAMINATION OF THE ABDOMEN

Urinary System

The urinary bladder is moderately distended with anechoic urine. The Bladder wall appears mildly thickened and irregular with small pile of shadowing debris in the dependent portion of the urinary bladder, most consistent with several small stones or a pile of mineralized sandy debris. Correlate with abdominal radiographs. The area of the trigone, ureteral papillae and proximal urethra (to a depth of 2cm) appear normal with no evidence of mass effects.

The prostate is normal in size (0.58 cm) and shape for this neutered male dog. The parenchyma is homogenous and the external margins are smooth. The prostatic urethra appears normal with no evidence of irregularity, invasion, mass effect or calculi.

The left kidney has a normal shape and size (4.29 cm) with many large, non-obstructive stones measuring 0.39, 0.30, 0.62 cm. Overall echogenicity is slightly hyperechoic with poor corticomedullary distinction and a typical 1:3 cortex:medulla ratio. There is no evidence of perinephric inflammation or effusion. There is no evidence of pyelectasia, infarcts or hydroureter. Renal vasculature is normal.

The right kidney has a normal shape and size (4.43 cm) with numerous small, non-obstructive nephroliths, the largest measuring approximately 0.32 cm. Overall echogenicity is slightly hyperechoic with poor corticomedullary distinction and a typical 1:3 cortex:medulla ratio. There is no evidence of perinephric inflammation or effusion. There is no evidence of pyelectasia, infarcts or hydroureter. Renal vasculature is normal.

Adrenal Glands

The left adrenal gland is normal in size measuring 0.64 cm at the caudal pole. It is observed in its normal position cranial to the left renal artery. It is normal in appearance (uniformly hypoechoic) and shape with no evidence of a mass effect.

The right adrenal gland is normal in size measuring 0.41 cm at the caudal pole. It is observed in its normal position between the cranial aspect of the right kidney and the caudal vena cava. It is normal in appearance (uniformly hypoechoic) and shape with no evidence of a mass effect.

Spleen

The spleen is subjectively normal in size, echotexture is homogenous, and the splenic capsule is smooth with no irregularities. The blood flow through the hilus and splenic parenchyma appears normal. No focal parenchymal abnormalities are visualized.

Liver

The liver is subjectively normal in size, and echogenicity with smooth peripheral margins. The parenchyma is heterogenous in echotexture with subtle, indistinct focal mottling. The visible portions of the vasculature and biliary tract appear normal. No focal nodules or cystic lesions are observed.

The gall bladder lumen is moderately distended. The wall of the gall bladder is not thickened and has a smooth mucosal surface. There is a moderate amount of non-organized echogenic debris. The cystic and common bile ducts are normal/not visible.



PATIENT

Gastrointestinal

Benny Pierce

The stomach contains minimal luminal contents. It measures at a normal thickness of <0.7cm with some variability due to the presence of rugal folds. The distinction of the gastric wall layers is adequate and there is no impression of reduced peristaltic activity. No masses or focal lesions were observed.

SPECIES

Canine

The visualized areas of duodenum, jejunum and ileum have a relatively uniform diameter with minimal fluid distension. Wall thickness is normal. Bowel loops follow a curvilinear path with distinct wall layering maintaining the typical 1:3 muscularis:mucosa layer ratio. The duodenum measured as normal (between 0.3-0.5cm in wall thickness) and the jejunum measured as normal (between 0.2-0.47cm.)

BREED

Shih Tzu

Visualized peristalsis appears appropriate. There were no focal lesions consistent with obstruction or a mass effect observed. Duodenum wall measured 0.47 cm. Jejunum wall measured 0.24 cm.

SEX

Neutered Male

The large intestine exhibited slightly prominent wall at 0.28 cm with intact wall layering. Sections of colon are visualized with formed fecal material and gas shadowing distally. There is no observed focal or generalized colon wall thickening or loss of layering.

Pancreas

AGE

11 Years

The pancreas is prominent and hypoechoic as compared to the surrounding isoechoic mesentery. There is no evidence of nodules or cystic lesions. There is no evidence of regional mesenteric inflammation or fluid.

Free Abdomen

WEIGHT

14.9 Pounds

Evaluation of the peritoneal cavity did not reveal any evidence of effusion. Prominent, but not enlarged mesenteric lymph nodes noted. Medial iliac nodes appear normal and there was no evidence of a caudal aortic thrombus at the bifurcation. The omentum appears hyperechoic in the region caudal to the stomach in the area of the pancreas.

INTERPRETED BY

Kathleen Sennello DVM,
MS, Diplomate ACVIM
(Small Animal Internal
Medicine)

PRIMARY FINDINGS

IMAGING PERFORMED BY

Dr. Tam Mengine

- Dependent mineralized debris in the urinary bladder – most consistent with bladder stones. Recommend urinalysis and culture.
- Prominent, hyperechoic pancreas – The pancreatic changes are most consistent with mild pancreatitis/pancreatic inflammation. Recommend fPLI testing and continued monitoring for improvement or possible development of a pancreatic abscess. Consider fine needle aspirate if not improving.
- Heterogeneous liver – The diffuse hepatic changes are non-specific and could be consistent with vacuolar hepatopathy, nodular hyperplasia, inflammatory/immune-mediated disease, fibrosis, extramedullary hematopoiesis, toxic hepatopathy (e.g., copper), infiltrative neoplasia (less likely) or other hepatopathy.
- Mild gallbladder debris – The gastric distension and hypomotility could be consistent with focal ileus or a proximal duodenal obstruction.

HOSPITAL NAME

Stoney Creek VH

REFERRING VET

Dr. Tam Mengine

INVOICE

26208

SECONDARY FINDINGS

DATE

10/12/21

- Non-obstructive nephroliths observed in both kidneys – The hyperechoic mineralized foci observed at the corticomedullary junction of the left/right kidney are consistent with small, non-obstructive nephroliths.
- Prominent colon wall – most consistent with colitis, no focal lesions observed.



PATIENT

Benny Pierce

SPECIES

Canine

BREED

Shih Tzu

SEX

Neutered Male

AGE

11 Years

WEIGHT

14.9 Pounds

INTERPRETED BY

Kathleen Sennello DVM,
MS, Diplomate ACVIM
(Small Animal Internal
Medicine)

**IMAGING
PERFORMED BY**

Dr. Tam Mengine

HOSPITAL NAME

Stoney Creek VH

REFERRING VET

Dr. Tam Mengine

INVOICE

26208

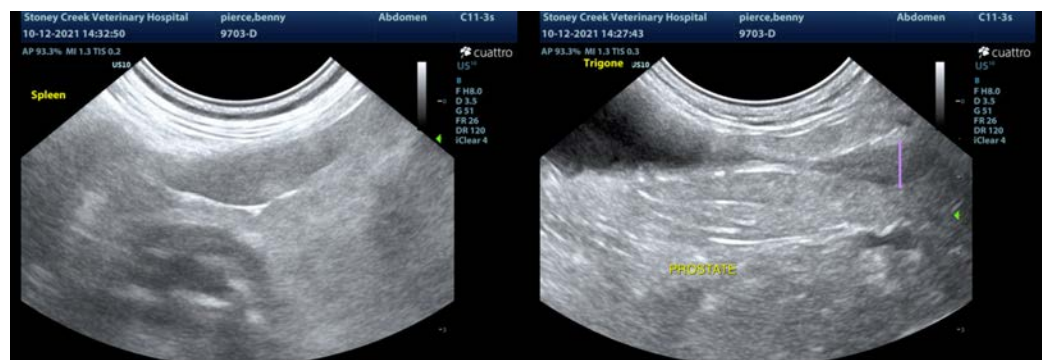
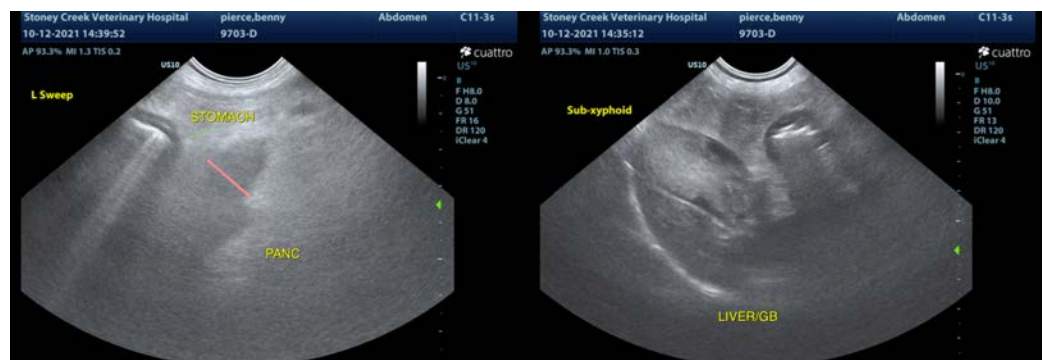
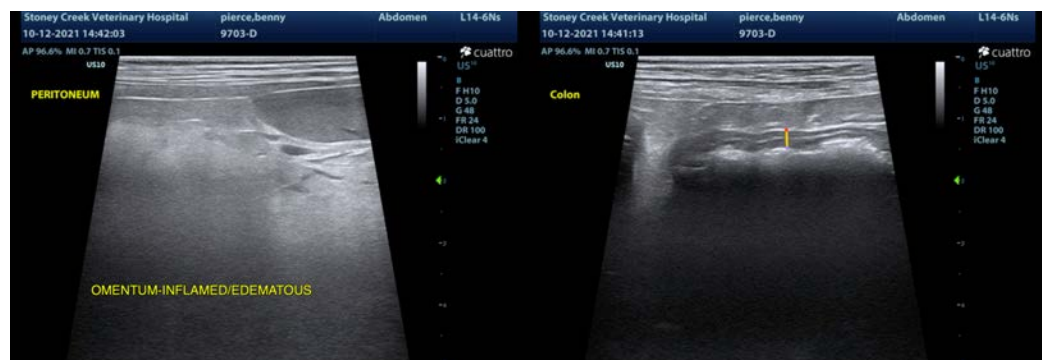DATE

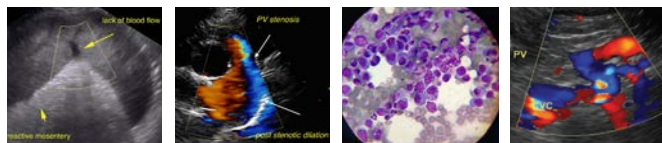
10/12/21

INTERPRETATION OF THE FINDINGS & FURTHER RECOMMENDATIONS

No focal lesions are observed associated with the GI tract. There is a lot of omental inflammation in the cranial left abdomen most consistent with pancreatic inflammation, and a prominent hypoechoic pancreas is visualized, but not clearly. Recommend a quantitative PLI, B12 and folate to better assess the pancreas and its degree of inflammation as well as the GI tract for underlying disease. Recommend symptomatic therapy for gastroenteritis/pancreatitis, but if symptoms are not resolving, reimaging may be necessary and further evaluation/diagnostics. Correlate these findings along with the mineralized debris in the urinary bladder with abdominal radiographs (serial if necessary), as GI foreign material can sometimes be missed on ultrasound.

Additionally, there are kidney and bladder stones present. At this time the kidney stones are likely incidental. Recommend urinalysis and culture and consider cystotomy in the future if this patient is feeling better. Liver enzymes may be reactive secondary to GI inflammation, or they can be primary. If the patient is not responding to symptomatic therapy, consider a fine needle aspirate of the liver and liver function testing for further evaluation.





PATIENT

Benny Pierce

SPECIES

Canine

BREED

Shih Tzu

SEX

Neutered Male

AGE

11 Years

WEIGHT

14.9 Pounds

INTERPRETED BY

Kathleen Sennello DVM,
MS, Diplomate ACVIM
(Small Animal Internal
Medicine)

**IMAGING
PERFORMED BY**

Dr. Tam Mengine

HOSPITAL NAME

Stoney Creek VH

REFERRING VET

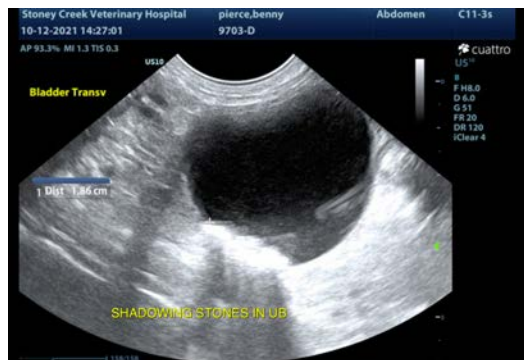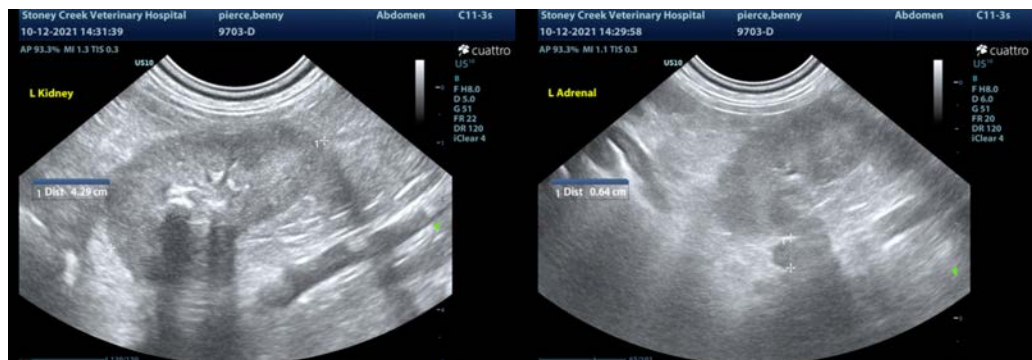
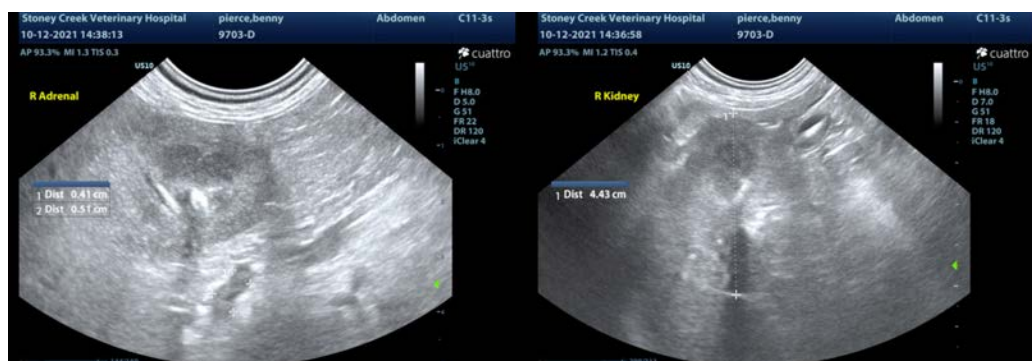
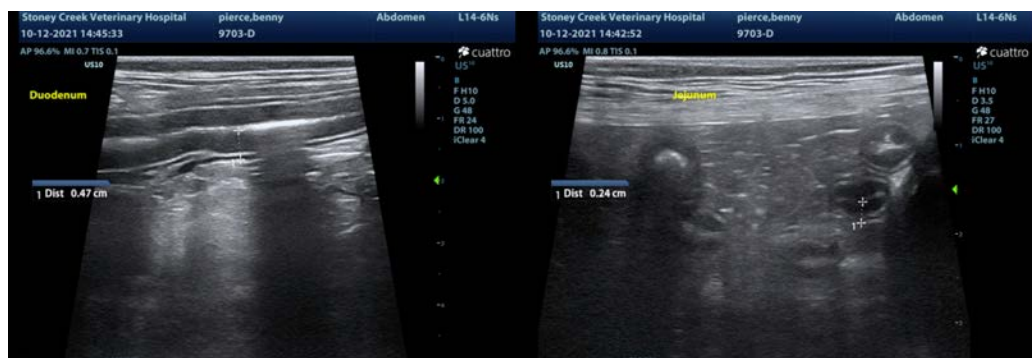Dr. Tam Mengine

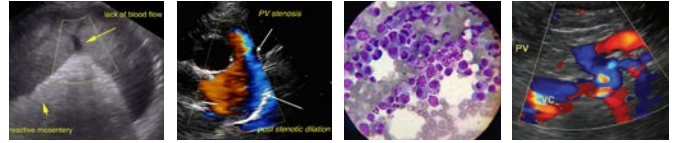
INVOICE

26208

DATE

10/12/21





PATIENT

Benny Pierce

The information and recommendations provided are based on the images presented by the referring veterinarian. No evaluation can be communicated regarding pathology that was not visible in the image/video clips provided.

SPECIES

Canine

Thank you for this referral. If the clinical or image interpretation does not parallel your findings or if I can be of any further assistance please contact me.

BREED

Shih Tzu

Kathleen Sennello DVM,MS, Diplomate ACVIM (Small animal Internal Medicine)
kathleen.sennello@sonopath.com

SEX

Neutered Male

AGE

11 Years

WEIGHT

14.9 Pounds

INTERPRETED BY

Kathleen Sennello DVM,
MS, Diplomate ACVIM
(Small Animal Internal
Medicine)

**IMAGING
PERFORMED BY**

Dr. Tam Mengine

HOSPITAL NAME

Stoney Creek VH

REFERRING VET

Dr. Tam Mengine

INVOICE

26208

DATE

10/12/21