

**DATE PRESENTING CLINICAL SIGNS**

10/11/22

Josie is a 7 y/o FS boxer who was referred for anemia - was seen at RDVM on Thursday had PCV/TP 11% started on prednisone, IM dexamethasone - was eating less, O noticed pale gums - O was giving her Vtit c, liquid iron, feeding liver - more lethargic, not eating since Thursday, will go from room to room - last ate yesterday 1/4 cup fresh pet - No C/S/V/D - Toxin - no known toxins - FB - no history of getting into things, started eating paper - Hx - heartworm, was treated, tested for HW negative, O have had for 3 years - housemates are not effected - Vx - due for rabies Medications: - prednisone 1.5 tablets (15mg?) BID last dose this AM - preventatives

PATIENT

Josie Thomas

SPECIES

Canine

Current Medications: Buprenorphine, Cerenia, Mycophenolate, Clopidogrel.
Lab Results: See attached.

BREED

Boxer

Date of Previous IntraPet Ultrasound: No previous.
Sedation: Not required to complete full diagnostic ultrasound.
Stat Report: Not requested.

SEX

Spayed Female

ULTRASONOGRAPHIC EXAMINATION OF THE ABDOMEN**AGE**

10/10/15

Urinary System

The urinary bladder is moderately distended with anechoic urine. The Bladder wall, trigone, ureteral papillae and visible urethra (to a depth of 2cm) appear normal with no evidence of wall thickening, mucosal irregularities, masses or cystic calculi.

WEIGHT

59.6 Pounds

The left kidney has a normal shape and size (6.74 cm). Overall echogenicity is normal with adequate corticomedullary distinction and a typical 1:3 cortex:medulla ratio. There is no evidence of focal perinephric inflammation or effusion. There is no evidence of pyelectasia, nephroliths, infarcts or hydroureter. Renal vasculature is normal.

INTERPRETED BY

Kathleen Sennello DVM,
MS, Diplomate ACVIM
(Small Animal Internal
Medicine)

The right kidney has a normal shape and size (7.6 cm). Overall echogenicity is normal with adequate corticomedullary distinction and a typical 1:3 cortex:medulla ratio. There is no evidence of focal perinephric inflammation or effusion. There is no evidence of pyelectasia, nephroliths, infarcts or hydroureter. Renal vasculature is normal.

IMAGING PERFORMED BY

Andi Parkinson RDMS

Adrenal Glands

The left adrenal gland is normal in size measuring 0.53 cm at the caudal pole. It is observed in its normal position cranial to the left renal artery. It is normal in appearance (uniformly hypoechoic) and shape with no evidence of a mass effect.

HOSPITAL NAME

Animal Emergency
Hospital

The right adrenal gland is normal in size measuring 0.63 cm at the caudal pole. It is observed in its normal position between the cranial aspect of the right kidney and the caudal vena cava. It is normal in appearance (uniformly hypoechoic) and shape with no evidence of a mass effect.

REFERRING VET

Dr. Thompson

Spleen

The spleen is subjectively normal in size, echotexture is homogenous, and the splenic capsule is smooth with no irregularities. The blood flow through the hilus and splenic parenchyma appears normal. No focal parenchymal abnormalities are visualized.

INVOICE

41971

Liver

The liver is subjectively normal in size, and echogenicity with smooth peripheral margins. The parenchyma is homogenous echotexture. The visible portions of the vasculature and biliary tract appear normal. No focal nodules or cystic lesions are observed.

The gall bladder lumen is moderately distended. The wall of the gall bladder is not thickened and has a smooth mucosal surface. There is a moderate amount of non-organized echogenic debris. The cystic and common bile ducts are normal/not visible.

Gastrointestinal

The stomach contains minimal luminal contents. It measures at a slightly increased thickness of approximately 0.90 cm with some variability due to the presence of rugal folds. The distinction of the gastric wall layers is adequate and there is no impression of reduced peristaltic activity. No masses or focal lesions were observed. There is some hyperechoic mesentery surrounding the stomach. Findings could be consistent with gastritis.

The visualized areas of duodenum, jejunum and ileum have a relatively uniform diameter with minimal fluid distension. Wall thickness is normal. Bowel loops follow a curvilinear path with distinct wall layering maintaining the typical 1:3 muscularis:mucosa layer ratio. Jejunum wall measures 0.38 cm. Visualized peristalsis appears appropriate. There were no focal lesions consistent with obstruction or a mass effect observed.

The ileocecal junction was visualized and exhibited normal intact wall layering and is subjectively of normal thickness. Sections of colon are visualized with formed fecal material and gas shadowing distally. There is no observed focal or generalized colon wall thickening or loss of layering.

Pancreas

The pancreas is normal and isoechoic to surrounding mesentery. There is no evidence of nodules or cystic lesions. There is no evidence of regional mesenteric inflammation or fluid.

Free Abdomen

There is a scant amount of free abdominal fluid. No lymphadenopathy. The omentum is generally of normal echogenicity, but slightly increased in the region of the stomach.

Other

A brief view of the heart was submitted. No significant pericardial effusion was seen.

ULTRASONOGRAPHIC FINDINGS

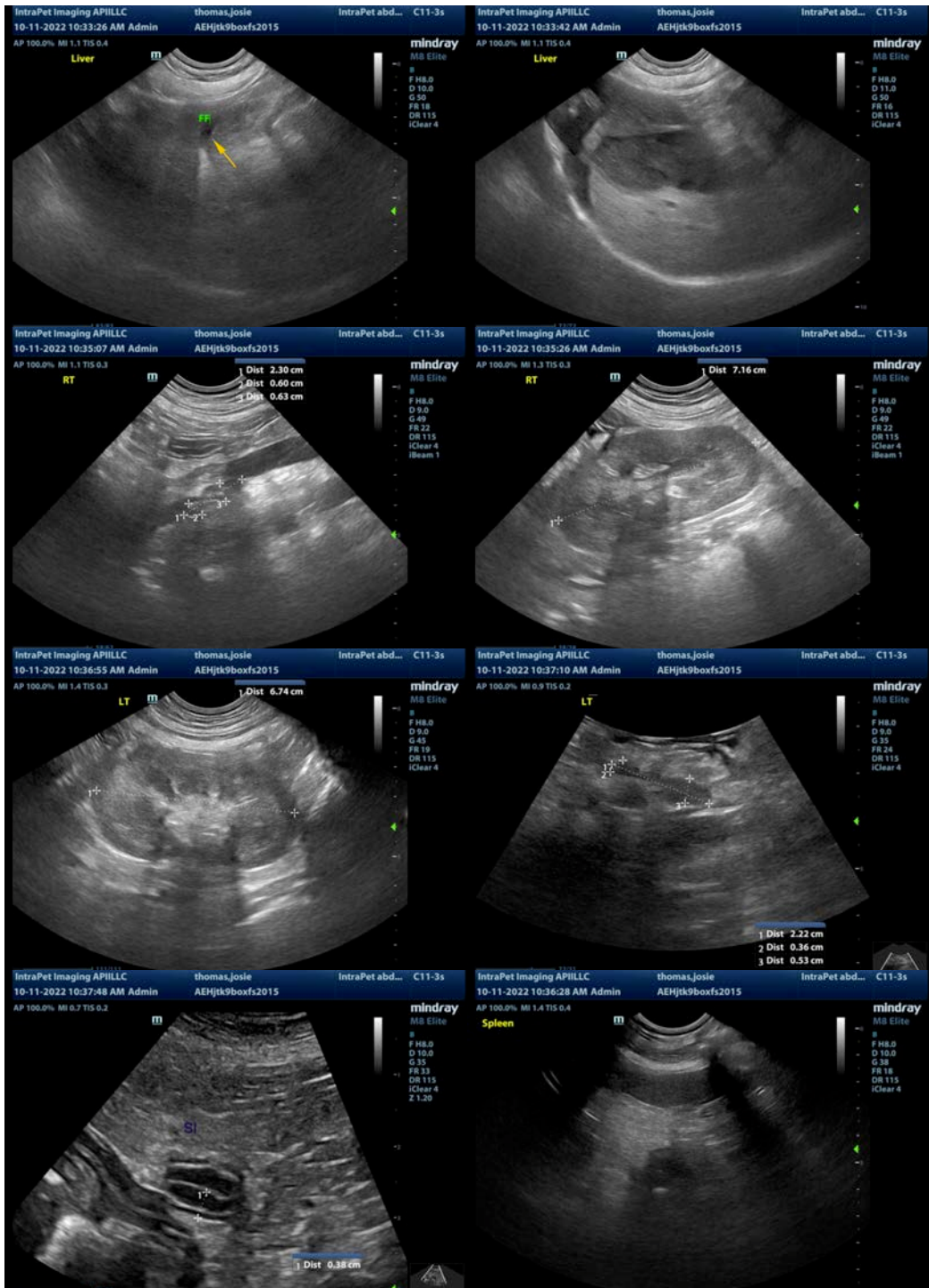
- Subjectively mildly thickened gastric wall with intact wall layering – Findings could be consistent with gastritis. Consider anti-ulcer therapy.
- Scant free abdominal fluid

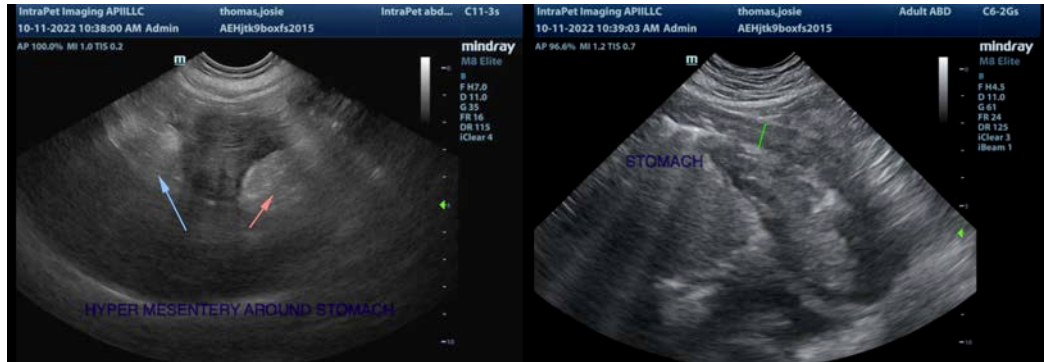
INTERPRETATION OF THE FINDINGS & FURTHER RECOMMENDATIONS

No specific lesions are visualized to be responsible or associated with the anemia reported. In some views, the stomach wall appears somewhat prominent, but layering is intact. This could be normal anatomic variation or mild gastritis. Monitor for any melena. You could consider anti-ulcer therapy and continued monitoring.

If this is a classic regenerative anemia with hemolysis and spherocytes, consider treatment for IMHA. If it is not a “classic” IMHA or is non regenerative recommend a reticulocyte count +/- pathologist review of the blood smear, a bone marrow aspirate and infectious disease testing. I like the canine comprehensive panel through NC State’s vector borne disease lab.

Recommend three view thoracic radiographs to evaluate for possible concurrent thoracic disease/involvement.





The information and recommendations provided are based on the images presented by the referring veterinarian/sonographer. No evaluation can be communicated regarding pathology that was not visible in the image/video clips provided.

Thank you for this referral. If the clinical or image interpretation does not parallel your findings or if I can be of any further assistance please contact me.

Kathleen Sennello DVM,MS, Diplomate ACVIM (Small animal Internal Medicine)
kathleen.sennello@sonopath.com