



PATIENT

Tonky Arroyo

SPECIES

Canine

BREED

Dachshund

SEX

Spayed Female

AGE

11 Years

WEIGHT

16.8 lbs

INTERPRETED BY

Kathleen Sennello DVM,
MS, Diplomate ACVIM
(Small Animal Internal
Medicine)

IMAGING PERFORMED BY

Gabriel Ferrer, DVM

HOSPITAL NAME

Pulse: Pet Ultrasound

REFERRING VET

Dr. Michelle Trappler

INVOICE

72042

DATE

1/7/26

PRESENTING CLINICAL SIGNS

Presented as a referral for an abdominal ultrasound for metastasis check and staging. Pt was diagnosed with a right anal gland carcinoma and wanted for check for evidence of metastasis prior to surgery especially on the sub-lumbar lymph nodes.

Abnormal PE/Chem/CBC/UA Results: FNA of Medial iliac/Lumbar LNs: Declined

ULTRASONOGRAPHIC EXAMINATION OF THE ABDOMEN

Urinary System

The urinary bladder is moderately distended with anechoic urine. The Bladder wall, trigone, ureteral papillae and visible urethra (to a depth of 2cm) appear normal with no evidence of wall thickening, mucosal irregularities, masses or cystic calculi.

The left kidney has a normal shape and size (4.75 cm). Overall echogenicity is normal with adequate corticomedullary distinction and a typical 1:3 cortex:medulla ratio. There is no evidence of focal perinephric inflammation or effusion. There is no evidence of pyelectasia, nephroliths, infarcts or hydroureter. Renal vasculature is normal.

The right kidney has a normal shape and size (4.96 cm). Overall echogenicity is normal with adequate corticomedullary distinction and a typical 1:3 cortex:medulla ratio. There is no evidence of focal perinephric inflammation or effusion. There is no evidence of pyelectasia, nephroliths, infarcts or hydroureter. Renal vasculature is normal.

Adrenal Glands

The left adrenal gland is normal in size measuring 0.49 cm at the cranial pole and 0.55 cm at the caudal pole. It is observed in its normal position cranial to the left renal artery. It is normal in appearance (uniformly hypoechoic) and shape with no evidence of a mass effect.

The right adrenal gland is normal in size measuring 0.53 cm at the cranial pole and 0.55 cm at the caudal pole. It is observed in its normal position between the cranial aspect of the right kidney and the caudal vena cava. It is normal in appearance (uniformly hypoechoic) and shape with no evidence of a mass effect.

Spleen

The spleen is subjectively normal in size (1.19 cm), echotexture is homogenous, and the splenic capsule is smooth with no irregularities. The blood flow through the hilus and splenic parenchyma appears normal. No focal parenchymal abnormalities are visualized.

Liver

The liver is borderline large in size, and normal in echogenicity with smooth peripheral margins. The parenchyma is mildly heterogenous in echotexture with subtle, indistinct focal mottling. The visible portions of the vasculature and biliary tract appear normal. No focal nodules or cystic lesions are observed.

The gall bladder lumen is significantly distended. Some areas of the wall appear mildly thickened with adherent debris. There is a large amount of primarily non-organized echogenic debris. Some of the



PATIENT

Tonky Arroyo

SPECIES

Canine

BREED

Dachshund

SEX

Spayed Female

AGE

11 Years

WEIGHT

16.8 lbs

INTERPRETED BY

Kathleen Sennello DVM,
MS, Diplomate ACVIM
(Small Animal Internal
Medicine)

IMAGING PERFORMED BY

Gabriel Ferrer, DVM

HOSPITAL NAME

Pulse: Pet Ultrasound

REFERRING VET

Dr. Michelle Trappler

INVOICE

72042

DATE

1/7/26

debris appears adhered to the gallbladder wall, measuring at 0.24 cm. There is no evidence of bile duct dilation.

Gastrointestinal

The stomach contains minimal luminal contents. It measures at a normal thickness of <0.7cm with some variability due to the presence of rugal folds. The distinction of the gastric wall layers is adequate and there is no impression of reduced peristaltic activity. No masses or focal lesions were observed.

The visualized areas of duodenum, jejunum and ileum have a relatively uniform diameter with minimal fluid distension. Wall thickness is normal. Bowel loops follow a curvilinear path with distinct wall layering maintaining the typical 1:3 muscularis:mucosa layer ratio. Duodenum wall measures 0.45 cm. Jejunum wall measures 0.28 cm. Visualized peristalsis appears appropriate. There were no focal lesions consistent with obstruction or a mass effect observed.

The ileocecal junction was visualized and exhibited normal intact wall layering and is subjectively of normal thickness. Sections of colon are visualized with formed fecal material and gas shadowing distally. Descending colon wall is prominent, measuring at 0.24 cm, with intact wall layering.

Pancreas

The pancreas is visible/mildly mottled in the right limb. There is no evidence of nodules or cystic lesions. There is no evidence of regional mesenteric inflammation or fluid.

Free Abdomen

Evaluation of the peritoneal cavity did not reveal any evidence of effusion. The iliac lymph nodes are slightly prominent and mildly hypoechoic. The right iliac measures 0.72 cm x 1.89 cm. The left measures 0.64 cm x 1.58 cm. Additionally, there is a somewhat poorly defined, hypoechoic lymph node near the descending colon measuring 0.36 cm x 1.69 cm. A mesenteric lymph node is visualized measuring 0.28 cm x 2.36 cm. The omentum is normal in echogenicity.

ULTRASONOGRAPHIC FINDINGS

- Borderline large, mildly heterogeneous liver – The diffuse hepatic changes are non-specific and could be consistent with vacuolar hepatopathy, nodular hyperplasia, inflammatory/immune-mediated disease, fibrosis, extramedullary hematopoiesis, toxic hepatopathy (e.g., copper), infiltrative neoplasia (less likely) or other hepatopathy.
- Large gallbladder debris with some gallbladder debris adhered to the gallbladder wall – A large amount of debris is evident in the gall bladder with no evidence of a mucocele or associated inflammation at this time. This could represent an early mucocele or cholestasis, with minimal evidence of associated inflammation at this time. Continued monitoring of labwork and ultrasound are warranted for progression of this lesion. Ursodiol therapy could be considered.
- Prominent, slightly hypoechoic iliac and sublumbar/colonic lymph nodes – The general appearance is most consistent with reactive lymph nodes, although early metastatic disease cannot be ruled out.



PATIENT

Tonky Arroyo

SPECIES

Canine

BREED

Dachshund

SEX

Spayed Female

AGE

11 Years

WEIGHT

16.8 lbs

INTERPRETED BY

Kathleen Sennello DVM,
MS, Diplomate ACVIM
(Small Animal Internal
Medicine)

IMAGING PERFORMED BY

Gabriel Ferrer, DVM

HOSPITAL NAME

Pulse: Pet Ultrasound

REFERRING VET

Dr. Michelle Trappler

INVOICE

72042

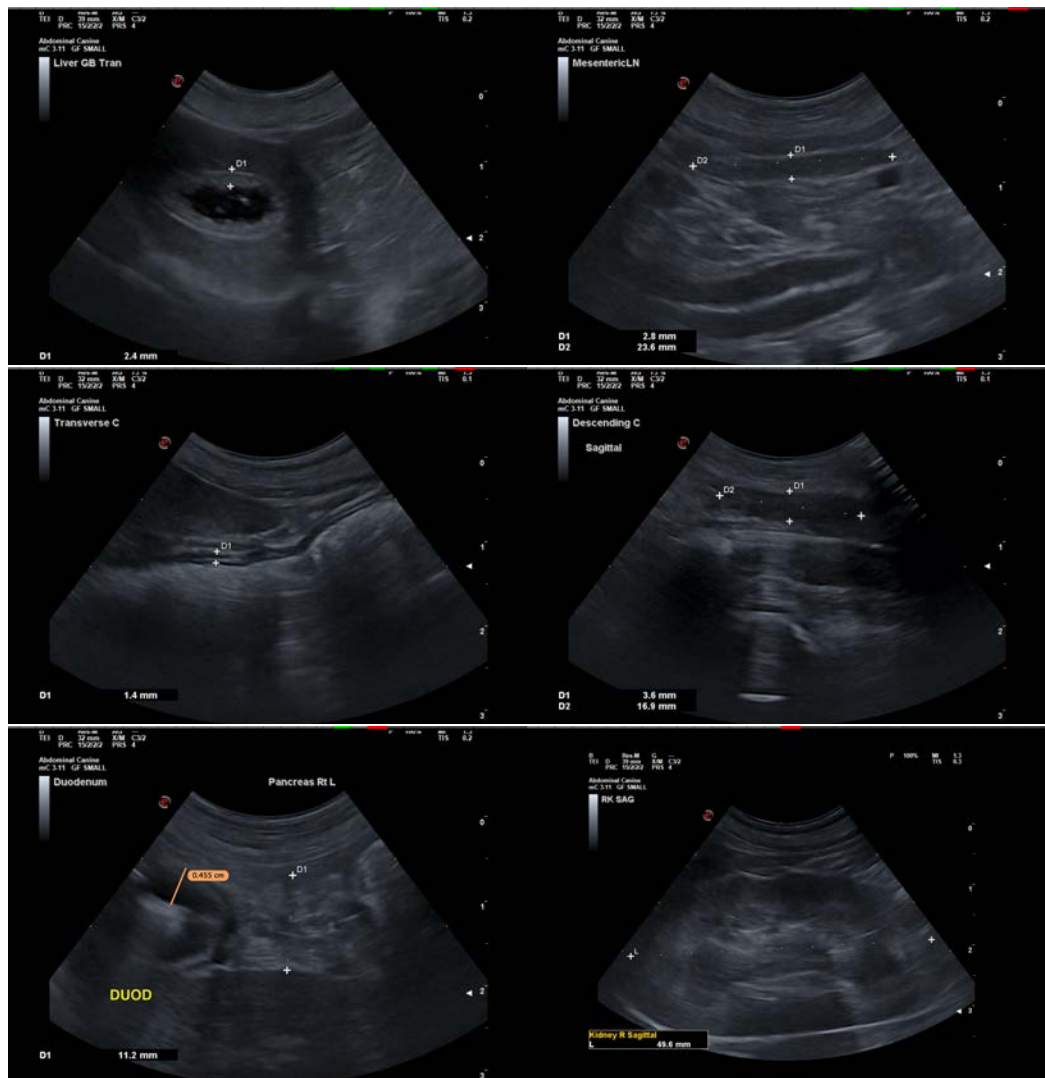
DATE

1/7/26

INTERPRETATION OF THE FINDINGS & FURTHER RECOMMENDATIONS

The iliac, sublumbar, and a colic lymph node are slightly prominent. At this time, the appearance of these lymph nodes is most consistent with reactive lymph nodes. Early neoplastic change cannot be definitively ruled out. Consider a fine needle aspirate or continued monitoring with ultrasound over time to look for progressive enlargement. No other lesions suspicious for metastatic disease are observed at this time.

The liver is mildly heterogeneous. This is a non-specific finding. Correlate with current lab work and clinical presentation. Additionally, the gallbladder has a large amount of debris, and a mild amount of debris adhered to the gallbladder wall. No evidence of significant inflammation is noted at this time.





PATIENT

Tonky Arroyo

SPECIES

Canine

BREED

Dachshund

SEX

Spayed Female

AGE

11 Years

WEIGHT

16.8 lbs

INTERPRETED BY

Kathleen Sennello DVM,
MS, Diplomate ACVIM
(Small Animal Internal
Medicine)

IMAGING PERFORMED BY

Gabriel Ferrer, DVM

HOSPITAL NAME

Pulse: Pet Ultrasound

REFERRING VET

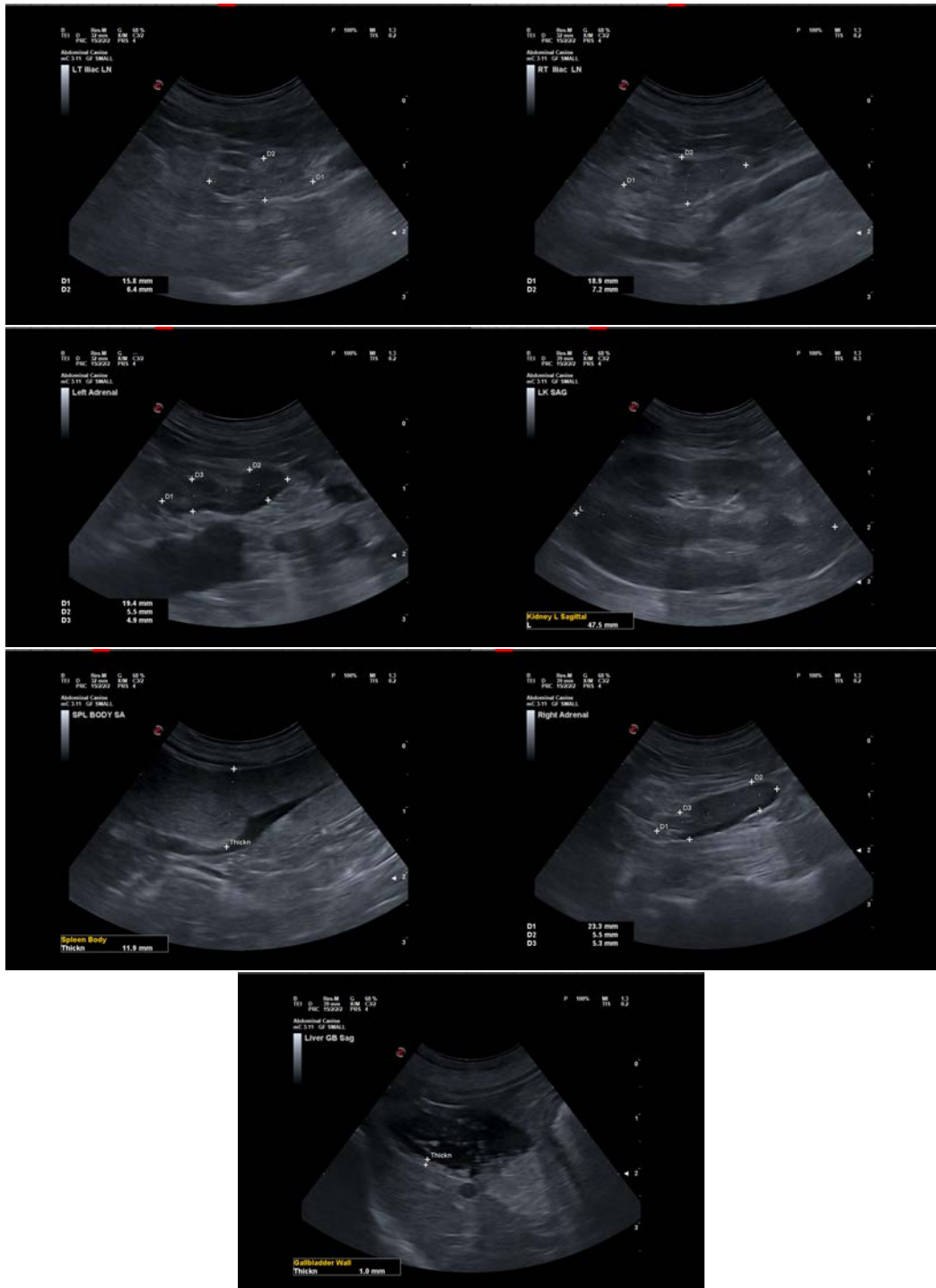
Dr. Michelle Trappler

INVOICE

72042

DATE

1/7/26





PATIENT

Tonky Arroyo

SPECIES

Canine

BREED

Dachshund

SEX

Spayed Female

AGE

11 Years

WEIGHT

16.8 lbs

INTERPRETED BY

Kathleen Sennello DVM,
MS, Diplomate ACVIM
(Small Animal Internal
Medicine)

IMAGING PERFORMED BY

Gabriel Ferrer, DVM

HOSPITAL NAME

Pulse: Pet Ultrasound

REFERRING VET

Dr. Michelle Trappler

INVOICE

72042

DATE

1/7/26

The information and recommendations provided are based on the images presented by the referring veterinarian/sonographer. No evaluation can be communicated regarding pathology that was not visible in the image/video clips provided.

Thank you for this referral. If the clinical or image interpretation does not parallel your findings or if I can be of any further assistance please contact me.

Kathleen Sennello DVM,MS, Diplomate ACVIM (Small animal Internal Medicine)

info@sonopath.com