



**PATIENT**

Milo Williams

**SPECIES**

Feline

**BREED**

DLH

**SEX**

Neutered Male

**AGE**

12 Years

**WEIGHT**

5.61 kg

**INTERPRETED BY**

Kathleen Sennello DVM,  
 MS, Diplomate ACVIM  
 (Small Animal Internal  
 Medicine)

**IMAGING PERFORMED BY**

Amanda Stewart

**HOSPITAL NAME**

Buck Animal Hospital

**REFERRING VET**

Dr. Armstrong

**INVOICE**

72014

**DATE**

1/7/26

**PRESENTING CLINICAL SIGNS**

Findings: weight gain, overgrooming Current Medications omegas and gabapentin for vet visits  
 Abnormal PE/Chem/CBC/UA Results: Primary Question to Be Answered in This Exam unexplained weight gain

**ULTRASONOGRAPHIC EXAMINATION OF THE ABDOMEN**

**Urinary System**

The urinary bladder is moderately distended with mild primarily suspended echogenic debris present. The Bladder wall, trigone, ureteral papillae and visible urethra (to a depth of 2cm) appear normal with no evidence of wall thickening, mucosal irregularities, masses or calculi. Echogenic debris of this type can be associated with small crystals, cellular debris and proteinaceous debris.

The left kidney has a normal shape and size (4.1 cm). Overall echogenicity is slightly hyperechoic with mildly reduced corticomedullary distinction and a typical 1:3 cortex:medulla ratio. There is no evidence of focal perinephric inflammation or effusion. There is no evidence of pyelectasia, nephroliths, infarcts or hydroureter. Renal vasculature is normal.

The right kidney has a normal shape and size (4.06 cm). Overall echogenicity is slightly hyperechoic with mildly reduced corticomedullary distinction and a typical 1:3 cortex:medulla ratio. There is no evidence of focal perinephric inflammation or effusion. There is no evidence of pyelectasia, nephroliths, infarcts or hydroureter. Renal vasculature is normal.

**Adrenal Glands**

The left adrenal gland is normal in size measuring 0.34 cm at the caudal pole. It is observed in its normal position cranial to the left renal artery. It is normal in appearance (uniformly hypoechoic) and shape with no evidence of a mass effect.

The right adrenal gland is normal in size measuring 0.36 cm at the caudal pole. It is observed in its normal position between the cranial aspect of the right kidney and the caudal vena cava. It is normal in appearance (uniformly hypoechoic) and shape with no evidence of a mass effect.

**Spleen**

The spleen is subjectively normal in size (0.98 cm), echotexture is homogenous, and the splenic capsule is smooth with no irregularities. The blood flow through the hilus and splenic parenchyma appears normal. No focal parenchymal abnormalities are visualized.

**Liver**

The liver is subjectively normal in size, and echogenicity with smooth peripheral margins. The parenchyma is homogenous echotexture. The visible portions of the vasculature and biliary tract appear normal. No focal nodules or cystic lesions are observed.

The gall bladder lumen is moderately distended. The wall of the gall bladder is not thickened and has a smooth mucosal surface. Luminal contents are mild and likely incidental at this time. The cystic and common bile ducts are normal/not visible.



**PATIENT**

Milo Williams

**SPECIES**

Feline

**BREED**

DLH

**SEX**

Neutered Male

**AGE**

12 Years

**WEIGHT**

5.61 kg

**INTERPRETED BY**

Kathleen Sennello DVM,  
 MS, Diplomate ACVIM  
 (Small Animal Internal  
 Medicine)

**IMAGING PERFORMED BY**

Amanda Stewart

**HOSPITAL NAME**

Buck Animal Hospital

**REFERRING VET**

Dr. Armstrong

**INVOICE**

72014

**DATE**

1/7/26

***Gastrointestinal***

The stomach contains minimal luminal contents. It measures at a normal thickness of <0.36cm with some variability due to the presence of rugal folds. The distinction of the gastric wall layers is adequate and there is no impression of reduced peristaltic activity. No masses or focal lesions were observed.

The visualized areas of duodenum, jejunum and ileum have a uniform diameter with minimal fluid distension. Wall thickness is normal to slightly increased. Bowel loops follow a typical curvilinear path with distinct wall layering, but some areas display a prominent muscularis layer which does not display the typical 1:3 muscularis:mucosa layer ratio. Jejunum wall measures 0.21 cm. Visualized peristalsis appears appropriate. There were no focal lesions consistent with obstruction or a mass effect observed.

Sections of colon are visualized with formed fecal material and gas shadowing distally. There is no observed focal or generalized colon wall thickening or loss of layering.

***Pancreas***

The area of the pancreas is normal and isoechoic to surrounding mesentery. There is no evidence of nodules or cystic lesions. There is no evidence of regional mesenteric inflammation or fluid.

***Free Abdomen***

Evaluation of the peritoneal cavity did not reveal any evidence of effusion, or subjective lymphadenomegaly. The Medial iliac nodes appear normal and there was no evidence of a caudal aortic thrombus at the bifurcation. The omentum is of normal uniform echogenicity.

**ULTRASONOGRAPHIC FINDINGS**

- Suspended echogenic debris in the urinary bladder – The echogenic debris in the bladder lumen could be consistent with cells, crystals, and/or mucus.
- Mild age related changes visualized associated with both kidneys.
- Prominent muscularis layer visualized associated with some areas of the small intestine – This could be associated with inflammatory type change, although the significance of these changes in the absence of GI signs is uncertain.

**INTERPRETATION OF THE FINDINGS & FURTHER RECOMMENDATIONS**

No obvious causes for the weight gain reported are observed. The significance of the changes observed are uncertain, as most of these would cause weight loss if significant. Recommend a urinalysis +/- culture to further evaluate the renal change and the bladder changes.

Other than inactivity and too high of caloric intake, medical differentials could include hypothyroidism (rare), acromegaly (rare), Cushing's disease, etc. Many of these differentials would be associated with diabetes.



**PATIENT**

Milo Williams

**SPECIES**

Feline

**BREED**

DLH

**SEX**

Neutered Male

**AGE**

12 Years

**WEIGHT**

5.61 kg

**INTERPRETED BY**

Kathleen Sennello DVM,  
 MS, Diplomate ACVIM  
 (Small Animal Internal  
 Medicine)

**IMAGING PERFORMED BY**

Amanda Stewart

**HOSPITAL NAME**

Buck Animal Hospital

**REFERRING VET**

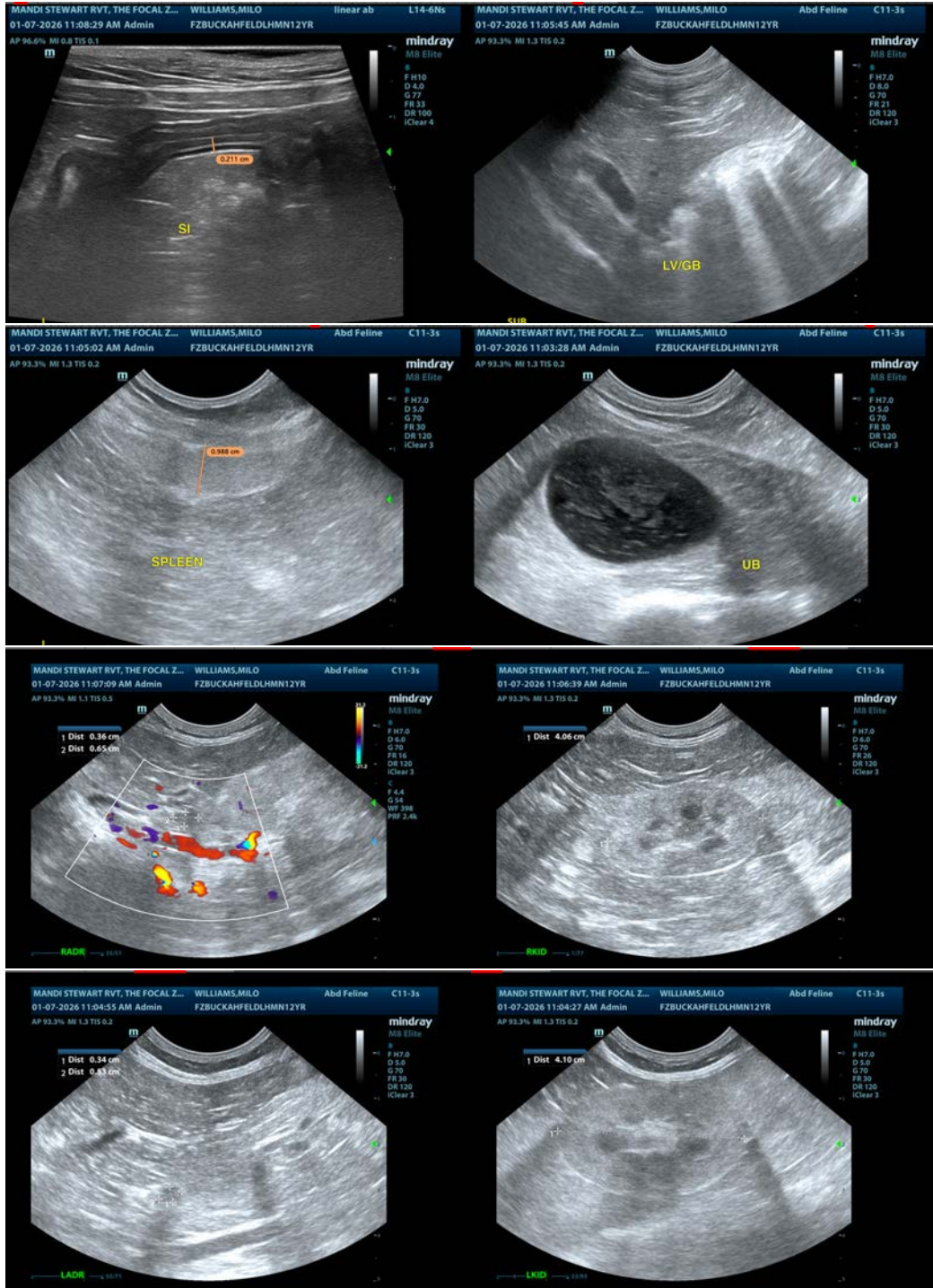
Dr. Armstrong

**INVOICE**

72014

**DATE**

1/7/26





**PATIENT**

Milo Williams

The information and recommendations provided are based on the images presented by the referring veterinarian/sonographer. No evaluation can be communicated regarding pathology that was not visible in the image/video clips provided.

**SPECIES**

Feline

Thank you for this referral. If the clinical or image interpretation does not parallel your findings or if I can be of any further assistance please contact me.

Kathleen Sennello DVM,MS, Diplomate ACVIM (Small animal Internal Medicine)

**BREED**

DLH

[info@sonopath.com](mailto:info@sonopath.com)

**SEX**

Neutered Male

**AGE**

12 Years

**WEIGHT**

5.61 kg

**INTERPRETED BY**

Kathleen Sennello DVM,  
MS, Diplomate ACVIM  
(Small Animal Internal  
Medicine)

**IMAGING  
PERFORMED BY**

Amanda Stewart

**HOSPITAL NAME**

Buck Animal Hospital

**REFERRING VET**

Dr. Armstrong

**INVOICE**

72014

**DATE**

1/7/26