



## PATIENT

Karma Deitrich

## SPECIES

Feline

## BREED

Oriental Shorthair x

## SEX

Spayed Female

## AGE

13 Years

## WEIGHT

9.24 lbs

## INTERPRETED BY

Kathleen Sennello DVM,  
MS, Diplomate ACVIM  
(Small Animal Internal  
Medicine)

## IMAGING PERFORMED BY

Dr. Elaina Petrone

## HOSPITAL NAME

Long Branch Animal  
Hospital

## REFERRING VET

Dr. Elaina Petrone

## INVOICE

72038

## DATE

1/7/26

## PRESENTING CLINICAL SIGNS

History of decreased appetite for approx. 1 week, hx of chronic rhinitis. Blood work NSF

## ULTRASONOGRAPHIC EXAMINATION OF THE ABDOMEN

### *Urinary System*

The urinary bladder is moderately distended with mild primarily suspended echogenic debris present. The Bladder wall, trigone, ureteral papillae and visible urethra (to a depth of 2cm) appear normal with no evidence of wall thickening, mucosal irregularities, masses or calculi. Echogenic debris of this type can be associated with small crystals, cellular debris and proteinaceous debris.

The left kidney is slightly irregular in shape, measuring 3.95 cm. Overall echogenicity is slightly hyperechoic with mildly reduced corticomedullary distinction and a typical 1:3 cortex:medulla ratio. There is no evidence of focal perinephric inflammation or effusion. There is no evidence of pyelectasia, nephroliths, infarcts or hydroureter. Renal vasculature is normal.

The right kidney has a normal shape and size (3.7 cm). Overall echogenicity is slightly hyperechoic with mildly reduced corticomedullary distinction and a typical 1:3 cortex:medulla ratio. There is no evidence of focal perinephric inflammation or effusion. There is no evidence of pyelectasia, nephroliths, infarcts or hydroureter. Renal vasculature is normal.

### *Adrenal Glands*

The left adrenal gland is normal in size measuring 0.31 cm at the caudal pole. It is observed in its normal position cranial to the left renal artery. It is normal in appearance (uniformly hypoechoic) and shape with no evidence of a mass effect.

The region of the right adrenal (between right cranial kidney and vena cava) is unremarkable, but the adrenal is not distinctly visualized. No evidence of a mass effect is visualized.

### *Spleen*

The spleen is subjectively normal in size (0.78 cm), echotexture is homogenous, and the splenic capsule is smooth with no irregularities. The blood flow through the hilus and splenic parenchyma appears normal. No focal parenchymal abnormalities are visualized.

### *Liver*

The liver is subjectively normal in size, and echogenicity with smooth peripheral margins. The parenchyma is homogenous echotexture. The visible portions of the vasculature and biliary tract appear normal. No focal nodules or cystic lesions are observed.

The gall bladder lumen is moderately distended. The wall of the gall bladder is not thickened and has a smooth mucosal surface. Luminal contents are mild and likely incidental at this time. The cystic and common bile ducts are normal/not visible.

### *Gastrointestinal*

The stomach contains minimal luminal contents. It measures at a normal thickness of <0.36cm with some variability due to the presence of rugal folds. The distinction of the gastric wall layers is adequate and there is no impression of reduced peristaltic activity. No masses or focal lesions were observed.



## PATIENT

Karma Deitrich

## SPECIES

Feline

## BREED

Oriental Shorthair x

## SEX

Spayed Female

## AGE

13 Years

## WEIGHT

9.24 lbs

## INTERPRETED BY

Kathleen Sennello DVM,  
MS, Diplomate ACVIM  
(Small Animal Internal  
Medicine)

## IMAGING PERFORMED BY

Dr. Elaina Petrone

## HOSPITAL NAME

Long Branch Animal  
Hospital

## REFERRING VET

Dr. Elaina Petrone

## INVOICE

72038

## DATE

1/7/26

The visualized areas of duodenum, jejunum and ileum have a relatively uniform diameter with minimal fluid distension. Wall thickness is normal. Bowel loops follow a curvilinear path with distinct wall layering maintaining the typical 1:3 muscularis:mucosa layer ratio. Jejunum wall measures 0.21 cm. Visualized peristalsis appears appropriate. There were no focal lesions consistent with obstruction or a mass effect observed.

Sections of colon are visualized with formed fecal material and gas shadowing distally. There is no observed focal or generalized colon wall thickening or loss of layering.

### Pancreas

The area of the pancreas is normal and isoechoic to surrounding mesentery. There is no evidence of nodules or cystic lesions. There is no evidence of regional mesenteric inflammation or fluid.

### Free Abdomen

Evaluation of the peritoneal cavity did not reveal any evidence of effusion, or subjective lymphadenomegaly. The Medial iliac nodes appear normal and there was no evidence of a caudal aortic thrombus at the bifurcation. The omentum is of normal uniform echogenicity.

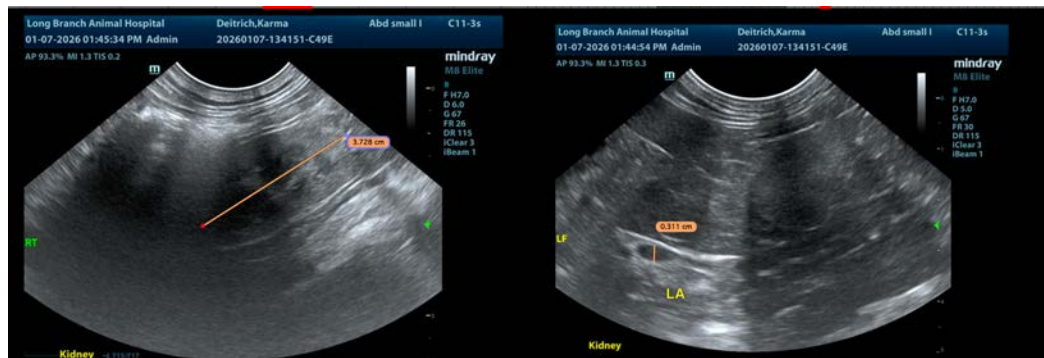
## ULTRASONOGRAPHIC FINDINGS


- Mild suspended echogenic debris in the urinary bladder – The echogenic debris in the bladder lumen could be consistent with cells, crystals, and/or mucus.
- Age related changes visualized associated with both kidneys.

## INTERPRETATION OF THE FINDINGS & FURTHER RECOMMENDATIONS

An obvious cause for the decrease in appetite is not clearly visualized on today's exam. This does not rule out the possibility of underlying gastrointestinal disease. If this is strongly suspected you could consider a GI panel to Texas A&M for a qualitative fPLI, TLI, cobalamin and folate to try to obtain additional information.

There is also the possibility that the rhinitis has had a recent exacerbation, causing a reduction in appetite(?). Correlate with clinical assessment, and if symptoms are progressing, consider repeat imaging in the future, looking for the development of new lesions or the progression of today's lesions.





## PATIENT

Karma Deitrich

## SPECIES

Feline

## BREED

Oriental Shorthair x

## SEX

Spayed Female

## AGE

13 Years

## WEIGHT

9.24 lbs

## INTERPRETED BY

Kathleen Sennello DVM,  
MS, Diplomate ACVIM  
(Small Animal Internal  
Medicine)

## IMAGING PERFORMED BY

Dr. Elaina Petrone

## HOSPITAL NAME

Long Branch Animal  
Hospital

## REFERRING VET

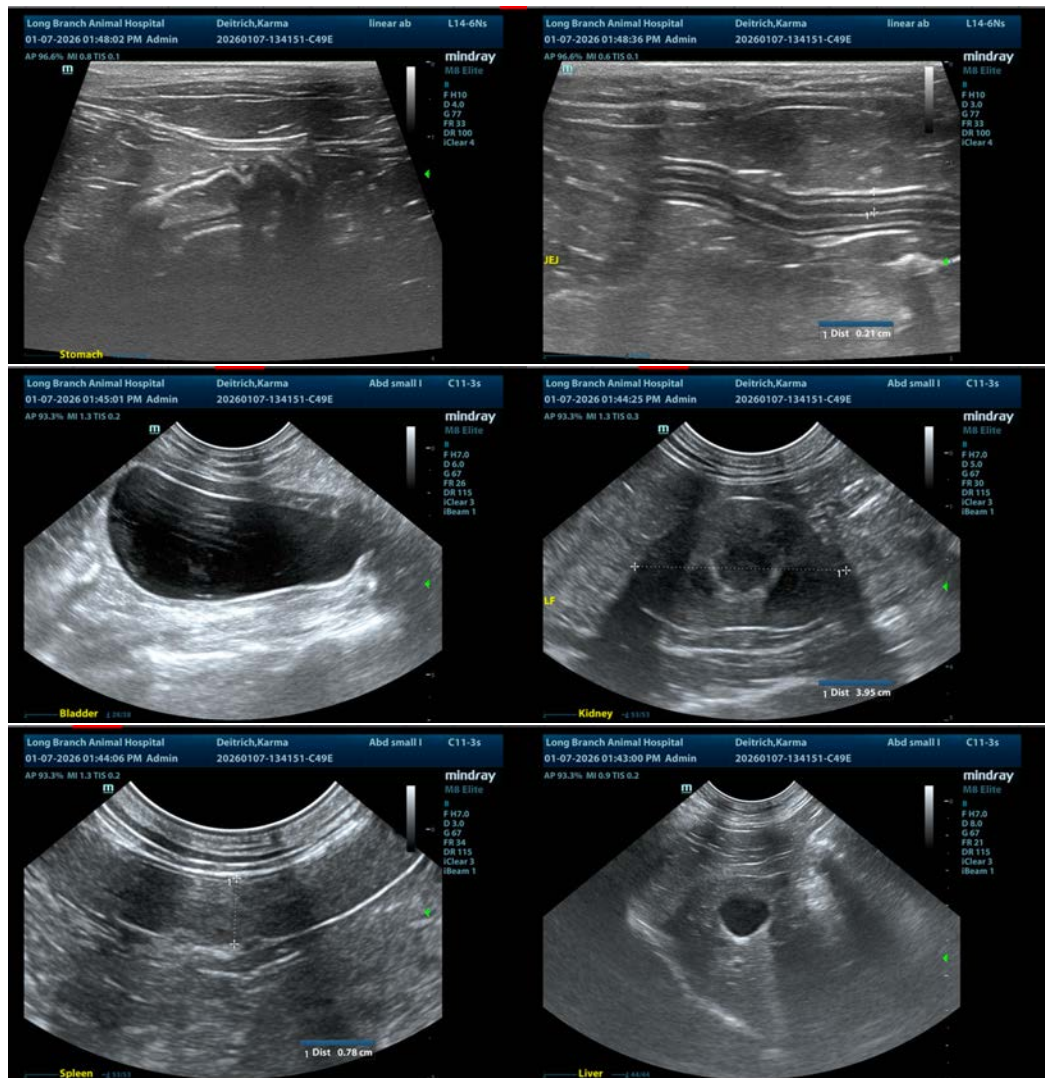
Dr. Elaina Petrone

## INVOICE

72038

## DATE

1/7/26



The information and recommendations provided are based on the images presented by the referring veterinarian/sonographer. No evaluation can be communicated regarding pathology that was not visible in the image/video clips provided.

Thank you for this referral. If the clinical or image interpretation does not parallel your findings or if I can be of any further assistance please contact me.

Kathleen Sennello DVM,MS, Diplomate ACVIM (Small animal Internal Medicine)

info@sonopath.com