SonoPath
Clinical Sonography & Telecytology

EDUCATIONAL TELECONSULTATION SERVICES™

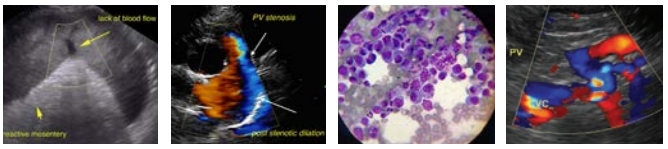

SonoPath.com™
1-800-838-4268 info@sonopath.com

PATIENT

Pudding Ventura

SPECIES

Feline

BREED

DSH

SEX

Neutered Male

AGE

17 Years

WEIGHT

Neutered Male

INTERPRETED BY

Kathleen Sennello DVM, MS, Diplomate ACVIM (Small Animal Internal Medicine)

IMAGING PERFORMED BY

Dr. Judy Schroeder

HOSPITAL NAME

Animal Health Associates

REFERRING VET

Dr. Judy Schroeder

INVOICE

34090

DATE

1/7/22

PRESENTING CLINICAL SIGNS

History of GI symptoms that responded well to GI diet over past 3 years. Recently decreased appetite, weight loss, to the point of complete anorexia. One episode of vomiting. Historic heart murmur. Abnormal PE/Chem/CBC/UA Results: Emaciation, severe dehydration, anemia. Thickened intestines with nodular mesentery. Hematocrit 18.9 % Reticulocytes dramatically increased 427.8 K/ul. Chemistry is wnl (albumin low normal 2.4 g/dl) USG 1.023.

ULTRASONOGRAPHIC EXAMINATION OF THE ABDOMEN

Urinary System

The urinary bladder is moderately distended with anechoic urine. The Bladder wall, trigone, ureteral papillae and visible urethra (to a depth of 2cm) appear normal with no evidence of wall thickening, mucosal irregularities, masses or cystic calculi.

The left kidney has a normal shape and size (3.69 cm). Overall echogenicity is slightly hyperechoic with poor corticomedullary distinction and a typical 1:3 cortex:medulla ratio. There is no evidence of perinephric inflammation or effusion. There is no evidence of pyelectasia, nephroliths, infarcts or hydroureter. Renal vasculature is normal.

The right kidney has a normal shape and size (3.29 cm). Overall echogenicity is slightly hyperechoic with poor corticomedullary distinction and a typical 1:3 cortex:medulla ratio. There is no evidence of perinephric inflammation or effusion. There is no evidence of pyelectasia, nephroliths, infarcts or hydroureter. Renal vasculature is normal.

Adrenal Glands

The left adrenal gland is normal in size measuring 0.30 cm at the caudal pole. It is observed in its normal position cranial to the left renal artery. It is normal in appearance (uniformly hypoechoic) and shape with no evidence of a mass effect.

The right adrenal gland is normal in size measuring 0.32 cm at the caudal pole. It is observed in its normal position between the cranial aspect of the right kidney and the caudal vena cava. It is normal in appearance (uniformly hypoechoic) and shape with no evidence of a mass effect.

Spleen

The spleen is borderline in size, measuring 1.1 cm in thickness at the hilus (normal is < 1.0 cm) and slightly irregular with scalloped edges. The spleen echotexture is heterogenous and mottled. The blood flow through the hilus and splenic parenchyma appears normal. No focal parenchymal abnormalities are visualized.

Liver

The liver is large in size, and normal in echogenicity with smooth peripheral margins. The parenchyma is heterogenous in echotexture with subtle, indistinct focal mottling. The visible portions of the vasculature and biliary tract appear normal. No focal nodules or cystic lesions are observed.

The gallbladder lumen is moderately distended. The wall of the gall bladder is not thickened and has a smooth mucosal surface. Luminal contents are primarily anechoic. The cystic and common bile ducts are normal/not visible.

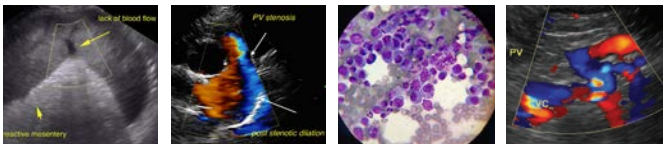

SonoPath.com
1-800-838-4268 info@sonopath.com

PATIENT

Pudding Ventura

SPECIES

Feline

BREED

DSH

SEX

Neutered Male

AGE

17 Years

WEIGHT

Neutered Male

INTERPRETED BY

Kathleen Sennello DVM, MS, Diplomate ACVIM (Small Animal Internal Medicine)

IMAGING PERFORMED BY

Dr. Judy Schroeder

HOSPITAL NAME

Animal Health Associates

REFERRING VET

Dr. Judy Schroeder

INVOICE

34090

DATE

1/7/22

Gastrointestinal

The stomach contains minimal luminal contents. It measures at a normal thickness of <0.36cm with some variability due to the presence of rugal folds. The distinction of the gastric wall layers is adequate and there is no impression of reduced peristaltic activity. No masses or focal lesions were observed.

The visualized areas of duodenum, jejunum and ileum have a uniform diameter with minimal fluid distension. Wall thickness is increased, measuring 0.44 cm in the jejunum. Bowel loops follow a typical curvilinear path with distinct wall layering, but some areas display a prominent muscularis layer which does not display the typical 1:3 muscularis:mucosa layer ratio. Visualized peristalsis appears appropriate. There were no focal lesions consistent with obstruction or a mass effect observed.

The ileocecal junction was visualized and exhibited normal intact wall layering and is subjectively of normal thickness. Sections of colon are visualized with formed fecal material and gas shadowing distally. There is no observed focal or generalized colon wall thickening or loss of layering.

Pancreas

The pancreas is prominent and hypoechoic in the area of the right limb. In the area of the left limb, there is nodular, very prominent, hypoechoic tissue, most consistent with either nodular/inflamed pancreas or irregular clusters of mesenteric lymph nodes.

Free Abdomen

There is a small volume of anechoic free fluid. There are prominent mesenteric lymph nodes in the abdomen. One is visualized measuring 1.54 cm in diameter. Additionally medial to the spleen is a cluster of irregular, hyperechoic tissue, most consistent with nodular pancreas or irregular mesenteric lymph nodes (or both). The omentum is of increased echogenicity in the area around the prominent lymph nodes and abnormal bowel.

PRIMARY FINDINGS

- Mottled, large, scalloped spleen – The diffuse splenic changes are non-specific and could be consistent with lymphoid hyperplasia, extramedullary hematopoiesis, infiltrative neoplasia, inflammation, other. Cytology or histopathology would be necessary to get a definitive diagnosis.

- Hypoechoic, irregular/nodular pancreas – The pancreatic changes are most consistent with moderate pancreatitis/pancreatic inflammation. Recommend fPLI testing and continued monitoring for improvement or possible development of a pancreatic abscess. Consider fine needle aspirate if not improving. Additionally, this could be consistent with infiltrative pancreatic disease (neoplasia).

- Large, heterogeneous liver – Hepatic changes are non-specific and could be consistent with inflammation/infection (cholangiohepatitis), infiltrative neoplasia, lipidosis or other hepatopathy.

- Thickened small intestine with prominent muscularis layer – The bowel wall thickening could be consistent with inflammation, edema, or infiltrative neoplasia.

- Moderate mesenteric lymphadenopathy – The moderate mesenteric lymphadenopathy is most concerning for a neoplastic process, although you can see significant lymphadenopathy in some cases of autoimmune/inflammatory disease, infectious disease(tick born disease-such as bartonella, fungal infections, FIP (cats)) etc. A fine needle aspirate with cytology is

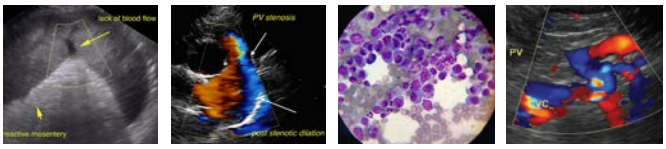

SonoPath.com
1-800-838-4268 info@sonopath.com

PATIENT

Pudding Ventura

SPECIES

Feline

BREED

DSH

SEX

Neutered Male

AGE

17 Years

WEIGHT

Neutered Male

INTERPRETED BY

Kathleen Sennello DVM, MS, Diplomate ACVIM (Small Animal Internal Medicine)

IMAGING PERFORMED BY

Dr. Judy Schroeder

HOSPITAL NAME

Animal Health Associates

REFERRING VET

Dr. Judy Schroeder

INVOICE

34090

DATE

1/7/22

recommended for further evaluation.

- Small volume free abdominal fluid.

SECONDARY FINDINGS

- Decreased corticomedullary distinction in both kidneys – The bilateral renal findings are consistent with age-related change.

INTERPRETATION OF THE FINDINGS & FURTHER RECOMMENDATIONS

I'm concerned the changes observed involving the small bowel and lymph nodes/pancreas are concerning for a possible underlying neoplastic condition. Alternatively, this could be a severe inflammatory disease, but these changes are not typically found in "normal" immune mediated anemia. Recommend holding off on Prednisone therapy until a diagnosis can be reached.

- Recommend a fine needle aspirate of a mesenteric lymph node, the irregular/abnormal pancreatic/mesenteric lymph nodes medial to the spleen, and you could also consider a fine needle aspirate of the liver and spleen.
- Recommend pathologist review of a blood smear to look for any atypical cells.
- Recommend FELV/FIV testing if not already done.
- Recommend 3-view thoracic radiographs to look for evidence of intrathoracic disease.
- If fine needle aspirates are not diagnostic, and a non-regenerative anemia is present, you could consider a bone marrow aspirate.
- Surgical biopsies of the small intestine, mesenteric lymph nodes, pancreas, etc. could be considered as well.
- If this patient isn't feeling well, you could consider a blood transfusion to provide symptomatic care while trying to obtain a definitive diagnosis.

If a full work up is not possible due to patient age/etc.. then palliative therapy with steroids could be considered (approx. 0.5mg/kg/day pred)as long as it is understood that this could impair the ability to get a diagnosis in the future.

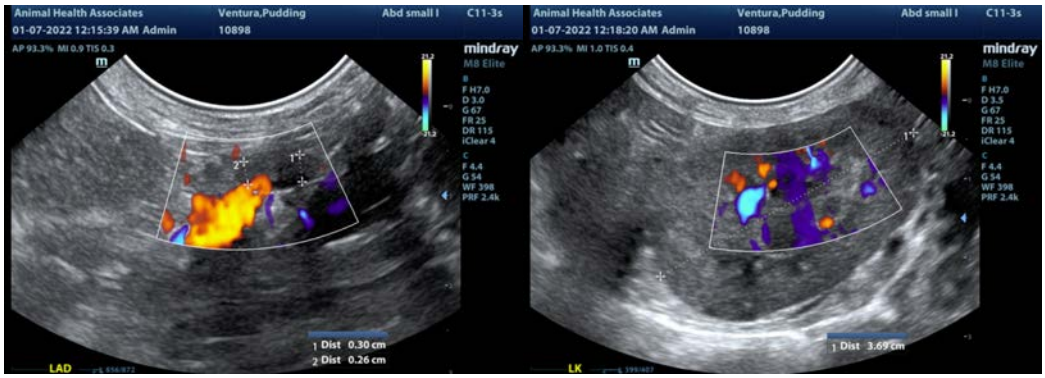

SonoPath

Clinical Sonography & Telecytology

EDUCATIONAL TELECONSULTATION SERVICES™

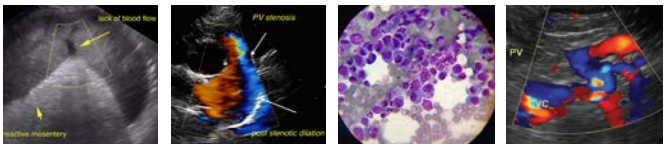

SonoPath.com™

1-800-838-4268 info@sonopath.com

PATIENT

Pudding Ventura

SPECIES

Feline

BREED

DSH

SEX

Neutered Male

AGE

17 Years

WEIGHT

Neutered Male

INTERPRETED BY

Kathleen Sennello DVM, MS, Diplomate ACVIM (Small Animal Internal Medicine)

IMAGING PERFORMED BY

Dr. Judy Schroeder

HOSPITAL NAME

Animal Health Associates

REFERRING VET

Dr. Judy Schroeder

INVOICE

34090

DATE

1/7/22

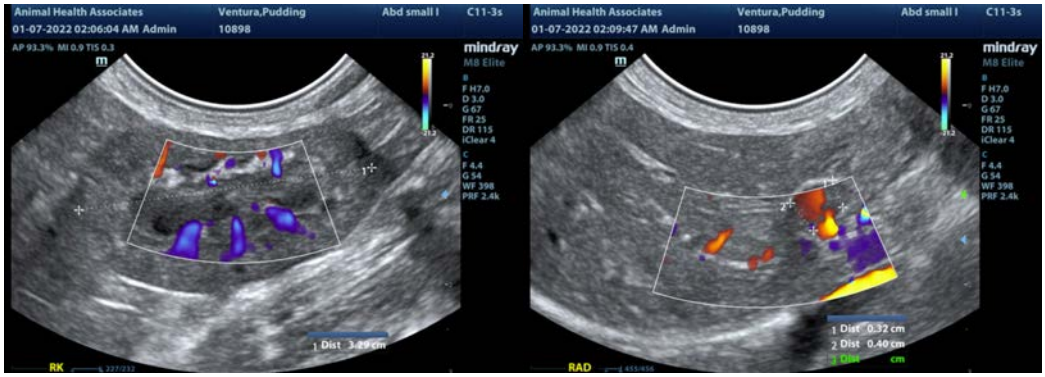

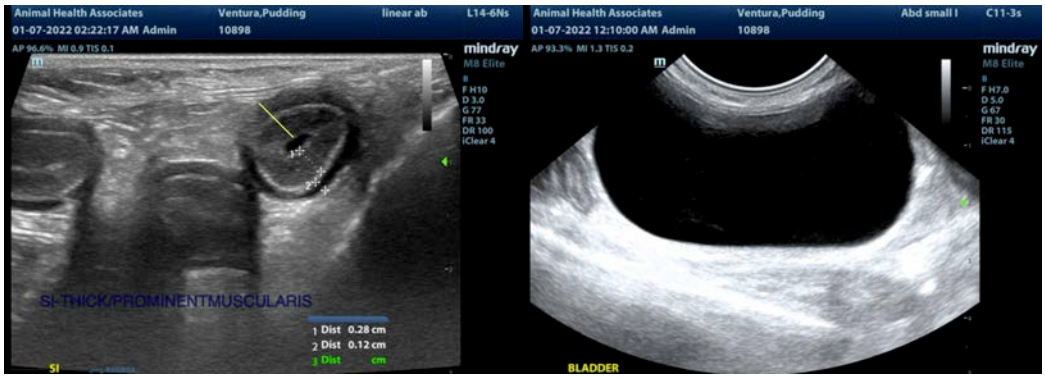

SonoPath

Clinical Sonography & Telecytology

EDUCATIONAL TELECONSULTATION SERVICES™

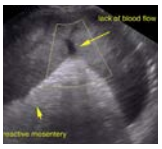
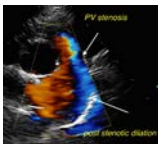
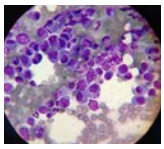
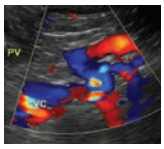

SonoPath.com™
1-800-838-4268 info@sonopath.com

PATIENT

Pudding Ventura

SPECIES

Feline

BREED

DSH

SEX

Neutered Male

AGE

17 Years

WEIGHT

Neutered Male

INTERPRETED BY

Kathleen Sennello DVM, MS, Diplomate ACVIM (Small Animal Internal Medicine)

IMAGING PERFORMED BY

Dr. Judy Schroeder

HOSPITAL NAME

Animal Health Associates

REFERRING VET

Dr. Judy Schroeder

INVOICE

34090

DATE

1/7/22

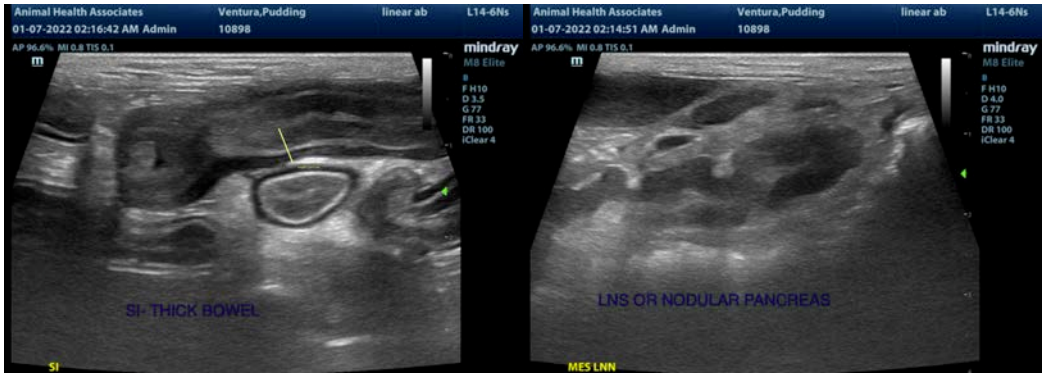

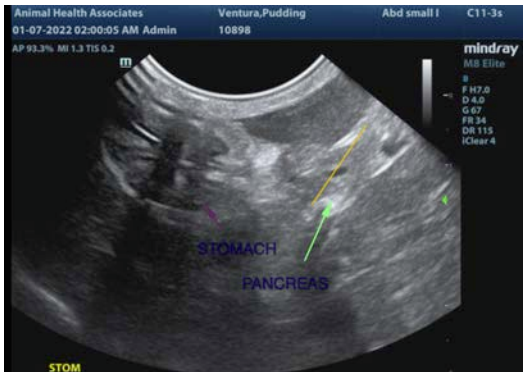

The information and recommendations provided are based on the images presented by the referring veterinarian. No evaluation can be communicated regarding pathology that was not visible in the image/video clips provided.

Thank you for this referral. If the clinical or image interpretation does not parallel your findings or if I can be of any further assistance please contact me.

Kathleen Sennello DVM,MS, Diplomate ACVIM (Small animal Internal Medicine)
kathleen.sennello@sonopath.com