

SonoPath
www.carolinavetmobile.com
info@carolinavetmobile.com
800.808.5948

PATIENT

Clover Duggan

SPECIES

Canine

BREED

Border Collie

SEX

Spayed Female

AGE

10 Years

WEIGHT

37.4

INTERPRETED BY

Kathleen Sennello DVM, MS, Diplomate ACVIM (Small Animal Internal Medicine)

IMAGING PERFORMED BY

Kathleen Byrnes

HOSPITAL NAME

Animal Hospital of Lake Brandt

REFERRING VET

Dr. Smith

INVOICE

72962

DATE

1/6/26

PRESENTING CLINICAL SIGNS

P presented for US due to chronic diarrhea. Fecal this am positive for whipworms

ULTRASONOGRAPHIC EXAMINATION OF THE ABDOMEN

Urinary System

The urinary bladder is moderately distended with anechoic urine. The Bladder wall, trigone, ureteral papillae and visible urethra (to a depth of 2cm) appear normal with no evidence of wall thickening, mucosal irregularities, masses or cystic calculi.

The left kidney has a normal shape and size (5.45 cm). Overall echogenicity is normal with adequate corticomedullary distinction and a typical 1:3 cortex:medulla ratio. There is no evidence of focal perinephric inflammation or effusion. There is no evidence of pyelectasia, nephroliths, infarcts or hydroureter. Renal vasculature is normal.

The right kidney has a normal shape and size (5.81 cm). Overall echogenicity is normal with adequate corticomedullary distinction and a typical 1:3 cortex:medulla ratio. There is no evidence of focal perinephric inflammation or effusion. There is no evidence of pyelectasia, nephroliths, infarcts or hydroureter. Renal vasculature is normal.

Adrenal Glands

The left adrenal gland is normal in size measuring 0.50 cm at the cranial pole and 0.59 cm at the caudal pole. It is observed in its normal position cranial to the left renal artery. It is normal in appearance (uniformly hypoechoic) and shape with no evidence of a mass effect.

The right adrenal gland is normal in size measuring 0.60 cm at the cranial pole and 0.49 cm at the caudal pole. It is observed in its normal position between the cranial aspect of the right kidney and the caudal vena cava. It is normal in appearance (uniformly hypoechoic) and shape with no evidence of a mass effect.

Spleen

The spleen is subjectively normal in size (2.03 cm), echotexture is homogenous, and the splenic capsule is smooth with no irregularities. The blood flow through the hilus and splenic parenchyma appears normal. No focal parenchymal abnormalities are visualized.

Liver

The liver is subjectively normal in size, and echogenicity with smooth peripheral margins. The parenchyma is homogenous echotexture. The visible portions of the vasculature and biliary tract appear normal. There are numerous poorly defined hyperechoic nodules in the parenchyma. The largest example measures 1.73 cm x 2.05 cm. Additional nodules measure 0.68 cm, 0.89 cm, and 0.43 cm in diameter.

The gall bladder lumen is moderately distended. The wall of the gall bladder is not thickened and has a smooth mucosal surface. There is a moderate amount of non-organized echogenic debris. Some of the debris appears adhered to the gallbladder wall, which appears mildly thickened, measuring at 0.30 cm. The cystic and common bile ducts are normal/not visible.

PATIENT

Clover Duggan

SPECIES

Canine

BREED

Border Collie

SEX

Spayed Female

AGE

10 Years

WEIGHT

37.4

INTERPRETED BY

Kathleen Sennello DVM, MS, Diplomate ACVIM (Small Animal Internal Medicine)

IMAGING PERFORMED BY

Kathleen Byrnes

HOSPITAL NAME

Animal Hospital of Lake Brandt

REFERRING VET

Dr. Smith

INVOICE

72962

DATE

1/6/26

Gastrointestinal

The stomach contains moderate fluid and gas. It measures at a normal thickness of <0.7cm with some variability due to the presence of rugal folds. The distinction of the gastric wall layers is adequate and there is no impression of reduced peristaltic activity. No masses or focal lesions were observed.

The visualized areas of duodenum, jejunum and ileum have a uniform diameter with minimal to moderate fluid distension. Wall appears subjectively, mildly increased. Bowel loops follow a typical curvilinear path with distinct wall layering. Duodenum wall measures 0.51 cm. Jejunum wall measures 0.30 cm. Visualized peristalsis appears appropriate. Some sections of small intestine appear somewhat more thickened, measuring up to 0.56 cm, with intact wall layering.

Sections of colon are visualized with non-formed fecal material and gas shadowing distally. The descending colon wall appears normal in thickness with intact wall layering, measuring at 0.26 cm.

Pancreas

The pancreas is normal and isoechoic to surrounding mesentery. There is no evidence of nodules or cystic lesions. There is no evidence of regional mesenteric inflammation or fluid.

Free Abdomen

Evaluation of the peritoneal cavity did not reveal any evidence of effusion. There are occasional prominent mesenteric lymph nodes. A jejunal lymph node is visualized measuring 1.01 cm x 3.92 cm. The omentum is normal in echogenicity.

ULTRASONOGRAPHIC FINDINGS

- Hyperechoic nodules in the liver – These generally have the appearance most consistent with benign lesions, although early neoplastic lesions cannot be ruled out.
- Moderate gallbladder debris with some debris adhered to the gallbladder wall – The significance of the aggregated gallbladder debris is unclear. This could represent an early mucocele, cholestasis, or may be secondary to fasting but seems unlikely to be causing a current issue. Recommend continued monitoring.
- Mild/moderate fluid/gas distended stomach and mild fluid distention of the small intestine – Correlate with the feeding history. Findings could be consistent with a non-fasted patient or generalized ileus/enteritis.
- Mildly thickened small intestine – The mild small intestinal wall changes may be a normal variant in this patient or could be consistent with an inflammatory process (e.g., inflammatory bowel disease).
- Occasional reactive mesenteric lymph nodes.

INTERPRETATION OF THE FINDINGS & FURTHER RECOMMENDATIONS

There is the general impression of prominent/mildly thickened small intestine with mild/moderate fluid distention. Correlate with the feeding history. If the patient was adequately fasted, this could represent mild ileus and enteritis. Given the recent positive whipworm test, this should be treated. These infections can sometimes be recurrent and difficult to clear. Monthly treatment is recommended with

PATIENT

Clover Duggan

SPECIES

Canine

BREED

Border Collie

SEX

Spayed Female

AGE

10 Years

WEIGHT

37.4

INTERPRETED BY

Kathleen Sennello DVM, MS, Diplomate ACVIM (Small Animal Internal Medicine)

IMAGING PERFORMED BY

Kathleen Byrnes

HOSPITAL NAME

Animal Hospital of Lake Brandt

REFERRING VET

Dr. Smith

INVOICE

72962

DATE

1/6/26

screening. If this appears to have cleared and symptoms are persistent, then a concurrent enteritis is possible. Consider the following:

- Consider a novel protein/hydrolyzed protein diet (exclusively at least 4-6 weeks)
- Consider a GI panel to Texas A&M for evaluation of B12 levels, folate, PLI/TLI etc.. to further evaluate for pancreatic/small intestinal disease.
- Recommend chronic probiotic therapy.

If symptoms are persistent despite taking these measures, eventually biopsies of the GI tract may be warranted.

The nature of the hyperechoic nodules in the liver is uncertain. Options would include continued monitoring with ultrasound or possibly a fine needle aspirate if a safe window for sampling is available and coagulation parameters are normal.

Correlate the gallbladder findings with current lab work. If significant liver enzyme elevations are present, you could consider treatment for mild cholecystitis, although I suspect the current findings are incidental.

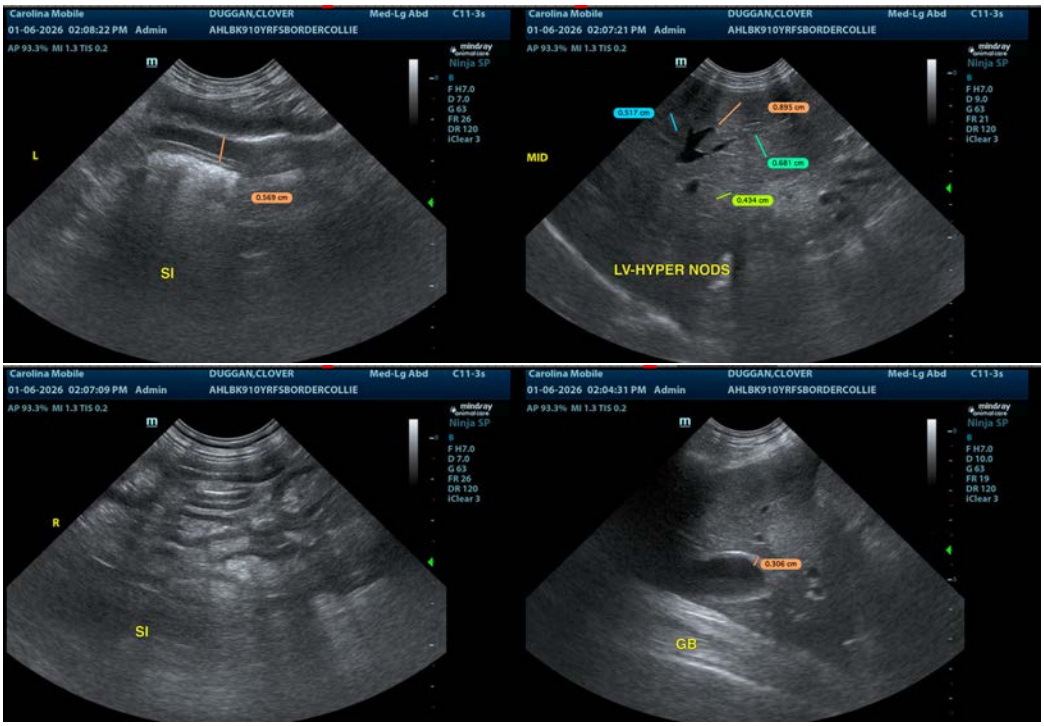

Carolina Veterinary Mobile
FUELED BY SONOPATH VETERINARY ULTRASOUND



Clinical Sonography & Telecytology
Educational Teleconsultation Services™

SonoPath
www.carolinavetmobile.com
info@carolinavetmobile.com
800.808.5948

PATIENT

Clover Duggan

SPECIES

Canine

BREED

Border Collie

SEX

Spayed Female

AGE

10 Years

WEIGHT

37.4

INTERPRETED BY

Kathleen Sennello DVM, MS, Diplomate ACVIM (Small Animal Internal Medicine)

IMAGING PERFORMED BY

Kathleen Byrnes

HOSPITAL NAME

Animal Hospital of Lake Brandt

REFERRING VET

Dr. Smith

INVOICE

72962

DATE

1/6/26

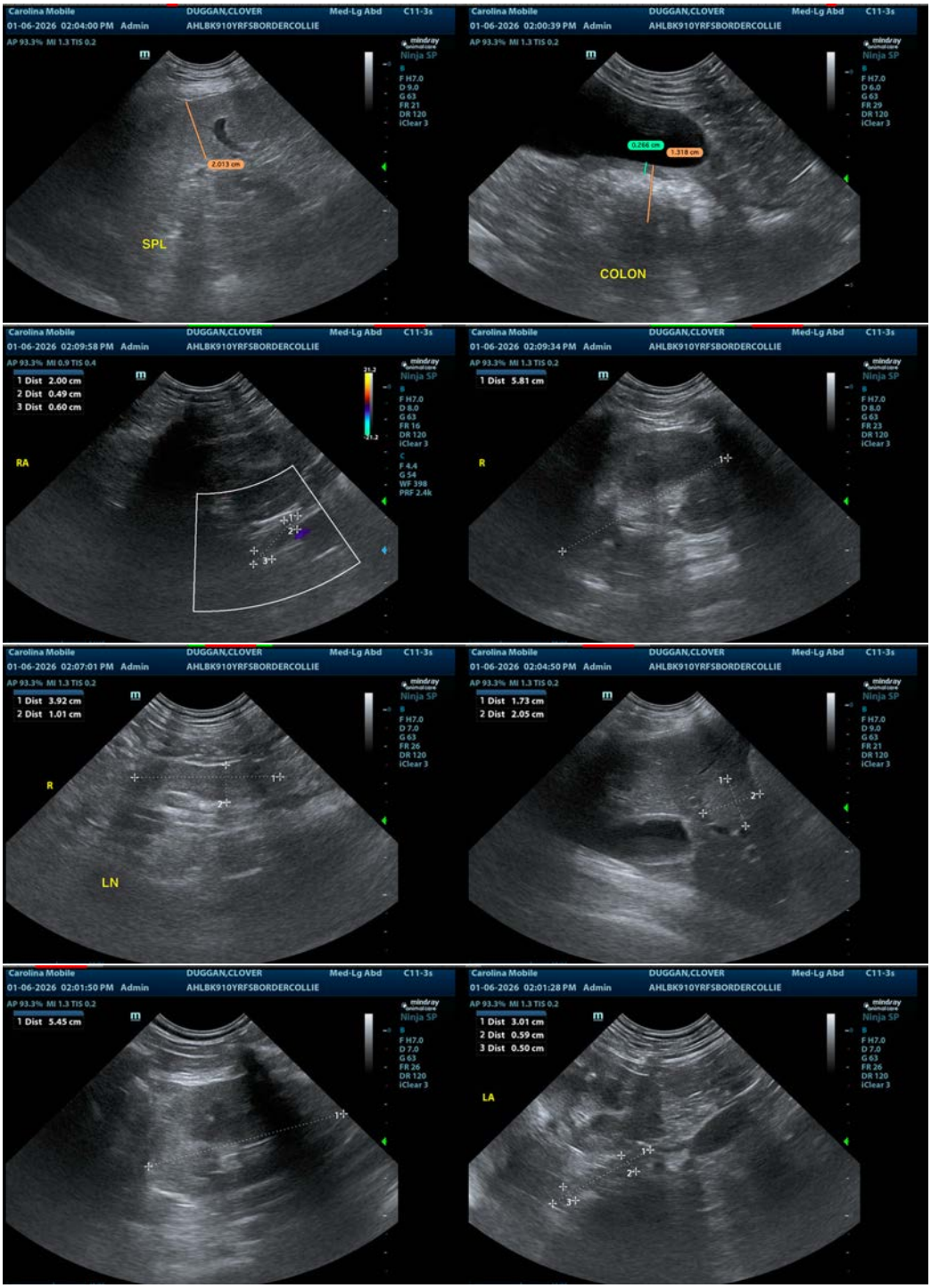



PATIENT

Clover Duggan

SPECIES

Canine

BREED

Border Collie

SEX

Spayed Female

AGE

10 Years

WEIGHT

37.4

INTERPRETED BY

Kathleen Sennello DVM, MS, Diplomate ACVIM (Small Animal Internal Medicine)

IMAGING PERFORMED BY

Kathleen Byrnes

HOSPITAL NAME

Animal Hospital of Lake Brandt

REFERRING VET

Dr. Smith

INVOICE

72962

DATE

1/6/26

The information and recommendations provided are based on the images presented by the referring veterinarian/sonographer. No evaluation can be communicated regarding pathology that was not visible in the image/video clips provided.

Thank you for this referral. If the clinical or image interpretation does not parallel your findings or if I can be of any further assistance please contact me.

Kathleen Sennello DVM,MS, Diplomate ACVIM (Small animal Internal Medicine)

info@sonopath.com