

**DATE PRESENTING CLINICAL SIGNS**

1/6/22

History: Vomiting and hematochezia since 12/29, seen by ER on 12/31 diagnostics wnl, no improvement with outpatient care. PE - dehydration, moderate dental tartar, dark tarry stools.

PATIENT

Portland Goldbloom

Current Medications: Sent home with meds from ER visit, unable to administer. Started on 1/3/21: Metronidazole 10mg/kg IV q12 hrs, Pantoprazole 1 mg/kg IV q24 hrs, Unasyn 30 mg/kg IV q8 h4rs, Cerenia 1 mg/kg IV q24 hrs, Diagal small dog PO q24 hrs twice, Hetastarch.

SPECIES

Canine

Lab Results: Bloodwork and rads from ER on 12/29 wnl. Bloodwork 1/3/21 - Albumin 2.2, TP 4.6, cholesterol 89. UA on 1/3/21 1.038, ph 8, prot 30, ketones 15, wbc 10/hpf, blood 250. Attached separately.

Date of Previous IntraPet Ultrasound: No previous IntraPet scans.

Sedation: Not required to complete full diagnostic ultrasound.

Stat Report: Not requested.

BREED

Toy Poodle

ULTRASONOGRAPHIC EXAMINATION OF THE ABDOMEN**SEX**

Spayed Female

Urinary System

The urinary bladder is moderately distended with anechoic urine. The Bladder wall, trigone, ureteral papillae and visible urethra (to a depth of 2cm) appear normal with no evidence of wall thickening, mucosal irregularities, masses or cystic calculi.

AGE

3/25/14

The left kidney has a normal shape and size (3.4 cm). Overall echogenicity is slightly hyperechoic with poor corticomedullary distinction and a typical 1:3 cortex:medulla ratio. There is no evidence of perinephric inflammation or effusion. There is no evidence of pyelectasia, nephroliths, infarcts or hydroureter. Renal vasculature is normal.

WEIGHT

9.2 Pounds

The right kidney has a normal shape and size (3.25 cm) with an occasional non-obstructive nephrolith visualized. Overall echogenicity is slightly hyperechoic with poor corticomedullary distinction and a typical 1:3 cortex:medulla ratio. There is no evidence of perinephric inflammation or effusion. There is no evidence of pyelectasia, infarcts or hydroureter. Renal vasculature is normal.

INTERPRETED BY

Kathleen Sennello DVM,
MS, Diplomate ACVIM
(Small Animal Internal
Medicine)

Adrenal Glands

The left adrenal gland is normal in size measuring 0.33 cm at the caudal pole. It is observed in its normal position cranial to the left renal artery. It is normal in appearance (uniformly hypoechoic) and shape with no evidence of a mass effect.

IMAGING PERFORMED BY

Stephanie Pearce
RDMS, RVT

The right adrenal gland is normal in size measuring 0.35 cm at the caudal pole. It is observed in its normal position between the cranial aspect of the right kidney and the caudal vena cava. It is normal in appearance (uniformly hypoechoic) and shape with no evidence of a mass effect.

HOSPITAL NAME

Eastern AH

Spleen

The spleen is subjectively normal in size, echotexture is homogenous, and the splenic capsule is smooth with no irregularities. The blood flow through the hilus and splenic parenchyma appears normal. No focal parenchymal abnormalities are visualized.

REFERRING VET

Dr. Cusack

Liver

The liver is subjectively normal in size, and echogenicity with smooth peripheral margins. The parenchyma is homogenous echotexture. The visible portions of the vasculature and biliary tract appear normal. No focal nodules or cystic lesions are observed.

INVOICE

34041

The gallbladder lumen is moderately distended. The wall of the gall bladder is not thickened and has a smooth mucosal surface. Luminal contents are primarily anechoic. The cystic and common bile ducts are normal/not visible.

Gastrointestinal

The stomach contains minimal luminal contents. It measures at a normal thickness of <0.7cm with some variability due to the presence of rugal folds. The distinction of the gastric wall layers is adequate and there is no impression of reduced peristaltic activity. No masses or focal lesions were observed.

The visualized areas of duodenum, jejunum and ileum have a relatively uniform diameter with minimal fluid distension. Wall thickness is normal. Bowel loops follow a curvilinear path with distinct wall layering maintaining the typical 1:3 muscularis:mucosa layer ratio. Jejunum wall measured 0.25, 0.27, 0.29 cm. Visualized peristalsis appears appropriate. There were no focal lesions consistent with obstruction or a mass effect observed.

The ileocecal junction was visualized and exhibited normal intact wall layering and is subjectively of normal thickness. Sections of colon are visualized with non-formed fecal material and gas shadowing distally. There is no observed focal or generalized colon wall thickening or loss of layering.

Pancreas

The pancreas is normal and isoechoic to surrounding mesentery. There is no evidence of nodules or cystic lesions. There is no evidence of regional mesenteric inflammation or fluid.

Free Abdomen

Evaluation of the peritoneal cavity did not reveal any evidence of effusion, or subjective lymphadenomegaly. The Medial iliac nodes appear normal and there was no evidence of a caudal aortic thrombus at the bifurcation. The omentum is of normal uniform echogenicity.

PRIMARY FINDINGS

- Decreased corticomedullary distinction in both kidneys – Mild loss of corticomedullary distinction in both kidneys could be consistent with chronic degenerative disease or interstitial nephrosis.

SECONDARY FINDINGS

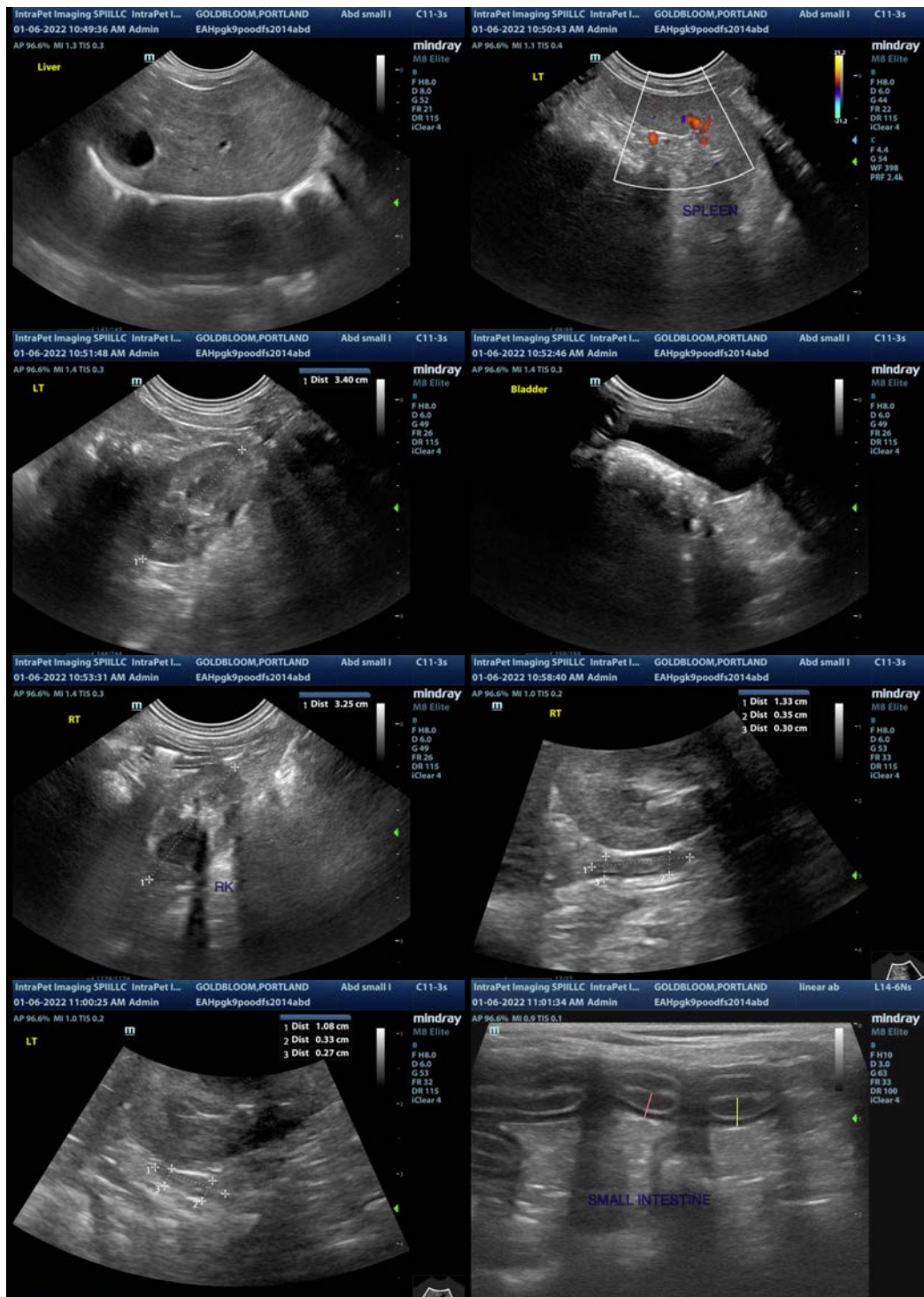
- Non-formed stool visualized in the distal colon – consistent with the diarrhea reported.

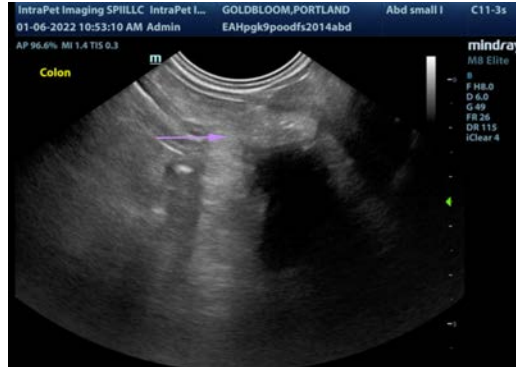INTERPRETATION OF THE FINDINGS & FURTHER RECOMMENDATIONS

No focal lesions were visualized to explain the vomiting and hematochezia described. Hopefully this is a severe HGE event, but other diagnostics are warranted at this point.

- Recommend current baseline bloodwork, recommend screening for Addison's disease (baseline cortisol or ACTH stimulation test).
- Recommend empirical deworming and testing.
- Consider possible fecal smear to look for evidence of clostridia or campylobacter
- Recommend continued in hospital treatment with antibiotics, probiotics, GI medications, and supportive care to ensure this patient gets adequate treatment (if owner can't medicate at home, etc.).
- Consider a urinalysis and urine protein/creatinine ratio to rule out concurrent proteinuria (seems unlikely based on recent urinalysis).
- If hemorrhage persists, consider a liver function test to rule out concurrent liver disease.
- If symptoms are not improving with adequate in hospital supportive care, then consider upper and lower GI endoscopy (sounds like large and small bowel signs).

The significance of the decreased corticomedullary distinction in the kidneys is uncertain. Recent urinalysis seems to at least show some concentrating ability, so this may be an incidental finding. Recommend continued monitoring of renal function.





The information and recommendations provided are based on the images presented by the referring veterinarian. No evaluation can be communicated regarding pathology that was not visible in the image/video clips provided.

Thank you for this referral. If the clinical or image interpretation does not parallel your findings or if I can be of any further assistance please contact me.

Kathleen Sennello DVM,MS, Diplomate ACVIM (Small animal Internal Medicine)
kathleen.sennello@sonopath.com