

**DATE PRESENTING CLINICAL SIGNS**

1/6/22 History: normal annual exam, no outward signs of illness. ALKP trending up over past 3 years: 401 (2019), 450 (2020), 688 (2021)

PATIENT CA 11.6, normal 11.4 new finding.

Khyber Dubois Current Medications: Gabapentin (Vet Visits), Omeprazole 10mg, Fluoxetine 10mg, Cetirizine.
Date of Previous IntraPet Ultrasound: No previous IntraPet scans.

SPECIES Sedation: Not required to complete full diagnostic ultrasound.
Stat Report: Not requested.

Canine

ULTRASONOGRAPHIC EXAMINATION OF THE ABDOMEN**BREED**

Chihuahua X

Urinary System

The urinary bladder is moderately distended with anechoic urine. The Bladder wall, trigone, ureteral papillae and visible urethra (to a depth of 2cm) appear normal with no evidence of wall thickening, mucosal irregularities, masses or cystic calculi.

SEX

Spayed Female

The left kidney has a normal shape and size (4.32 cm). Overall echogenicity is normal with adequate corticomedullary distinction and a typical 1:3 cortex:medulla ratio. There is no evidence of perinephric inflammation or effusion. There is no evidence of pyelectasia, nephroliths, infarcts or hydroureter. Renal vasculature is normal.

AGE

2/1/12

WEIGHT

15.3 Pounds

The right kidney has a normal shape and size (5.14 cm) with significant pyelectasia at 0.85 cm and two stones visualized within the renal pelvis measuring 0.35 cm and 0.31 cm. Overall echogenicity is normal with adequate corticomedullary distinction and a typical 1:3 cortex:medulla ratio. There is no evidence of perinephric inflammation or effusion. There is no evidence of infarcts or hydroureter. Renal vasculature is normal.

INTERPRETED BY

Kathleen Sennello DVM,
MS, Diplomate ACVIM
(Small Animal Internal
Medicine)

Adrenal Glands

The left adrenal gland is normal in size measuring 0.61 cm at the caudal pole. It is observed in its normal position cranial to the left renal artery. It is normal in appearance (uniformly hypoechoic) and shape with no evidence of a mass effect.

IMAGING PERFORMED BY

Stephanie Pearce
RDMS, RVT

The right adrenal gland is normal in size measuring 0.57 cm at the caudal pole. It is observed in its normal position between the cranial aspect of the right kidney and the caudal vena cava. It is normal in appearance (uniformly hypoechoic) and shape with no evidence of a mass effect.

HOSPITAL NAME

Eastern AH

Spleen

The spleen is subjectively normal in size, echotexture is homogenous, and the splenic capsule is smooth with no irregularities. The blood flow through the hilus and splenic parenchyma appears normal. There is a very small hypoechoic nodule visualized measuring 0.23 cm x 0.35 cm.

REFERRING VET

Dr. Warner-Jones

Liver

The liver is subjectively normal in size with smooth peripheral margins. The parenchyma is slightly hyperechoic and homogenous in echotexture. The visible portions of the vasculature and biliary tract appear normal. No focal nodules or cystic lesions are observed.

INVOICE

34038

The gall bladder lumen is moderately distended. The wall of the gall bladder is not thickened and has a smooth mucosal surface. There is a mild amount of non-organized echogenic debris. The cystic and common bile ducts are normal/not visible.

Gastrointestinal

The stomach contains minimal luminal contents. It measures at a normal thickness of <0.7cm with some variability due to the presence of rugal folds. The distinction of the gastric wall layers is adequate and there is no impression of reduced peristaltic activity. No masses or focal lesions were observed.

The visualized areas of duodenum, jejunum and ileum have a relatively uniform diameter with minimal fluid distension. Wall thickness is normal. Bowel loops follow a curvilinear path with distinct wall layering maintaining the typical 1:3 muscularis:mucosa layer ratio. Duodenum wall measured 0.37 cm. Jejunum wall measured 0.35 cm. Visualized peristalsis appears appropriate. There were no focal lesions consistent with obstruction or a mass effect observed.

The ileocecal junction was visualized and exhibited normal intact wall layering and is subjectively of normal thickness. Sections of colon are visualized with formed fecal material and gas shadowing distally. There is no observed focal or generalized colon wall thickening or loss of layering.

Pancreas

The pancreas is prominent and hypoechoic as compared to the surrounding isoechoic mesentery. There is no evidence of nodules or cystic lesions. There is no evidence of regional mesenteric inflammation or fluid.

Free Abdomen

Evaluation of the peritoneal cavity did not reveal any evidence of effusion, or subjective lymphadenomegaly. The Medial iliac nodes appear normal and there was no evidence of a caudal aortic thrombus at the bifurcation. The omentum is of normal uniform echogenicity.

Other

A brief view of the heart was submitted. No pericardial effusion was seen.

The uterine stump is visualized and appears within normal limits.

PRIMARY FINDINGS

- Right-sided renal pelvic dilation with two stones visualized within the renal pelvis – These changes are concerning for possible partial obstruction due to the stones. I don't see any evidence of ureteral dilation.
- Very small, hypoechoic splenic nodule – There is a non-cavitated, hypoechoic splenic nodule visualized. Differentials include lymphoid hyperplasia, extramedullary hematopoiesis, infiltrative neoplasia, inflammation, other. Cytology or histopathology would be necessary to get a definitive diagnosis.
- Mildly hyperechoic liver – The diffuse hepatic changes are non-specific and can be seen with vacuolar hepatopathy, reactive change, nodular hyperplasia or, less likely, inflammatory/immune-mediated disease, infiltrative neoplasia, or other hepatopathy.

SECONDARY FINDINGS

- Hypoechoic, prominent pancreas – The pancreatic changes are most consistent with age-related parenchymal remodeling, potentially secondary to a prior inflammatory episode, early fibrosis or chronic pancreatitis.
- Mild gallbladder sludge – The significance of the aggregated gallbladder sludge is unclear. This could represent an early mucocele, cholestasis, or may be secondary to fasting.

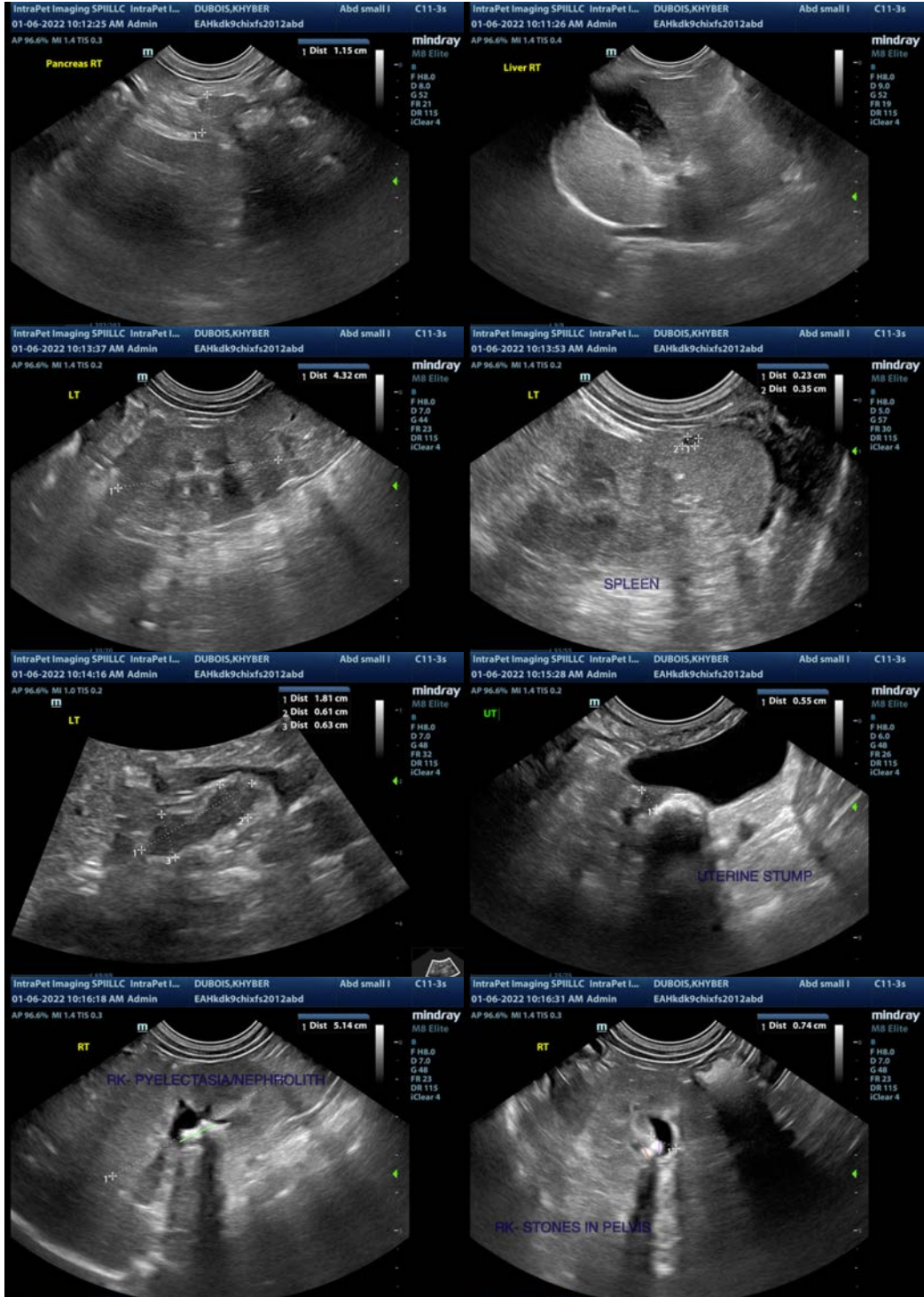
INTERPRETATION OF THE FINDINGS & FURTHER RECOMMENDATIONS

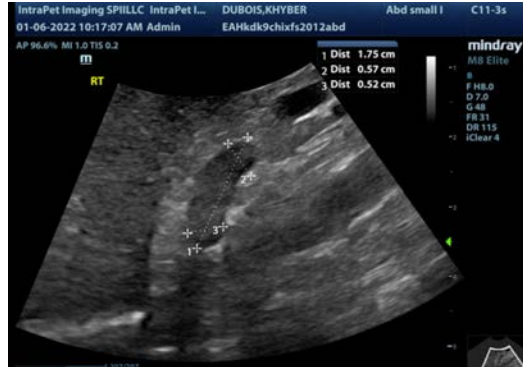No focal lesions are visualized within the liver to explain the ALP elevation. Additionally, the gallbladder looks relatively normal, so this is unlikely gallbladder disease. These are my recommendations for a patient with an ALP elevation:

- Induction phenomena are the most common cause for an elevation in ALP. These are systemic illnesses that 'turn on' the liver enzyme. Causes of this include Cushing's disease, dental disease, arthritis, and numerous others. In many cases the exact cause is unclear but as long as ultrasound and bile acids tests are normal most patients do not have progressive changes in their liver. While liver biopsy is not routinely performed, vacuolar hepatopathy, is noted on most biopsies. This is often non-progressive but in rare cases can be more severe and lead to liver failure.
- If signs of Cushing's disease are present recommend endocrine function testing to evaluate for Cushing's disease.
- Consider fine needle aspirate to rule out round cell neoplasia -if this is a concern.
- If a cause for the ALP elevation is not identified: I recommend recheck general blood work every 6 months, ultrasound once per year, and bile acids test every 1-2 years based on other results. If the ALP continues to climb a biopsy could be considered.
- Consider long term use of denamarin, and monitoring for the signs of Cushing's developing.
- A primary vacuolar hepatopathy can be breed related and is seen in Scottish Terriers, Schnauzers, Cocker spaniels etc.

Additionally, there is significant pyelectasia in the right kidney and two stones visualized in the renal pelvis. This is concerning for an early partial obstructive process or for the possibility of these stones dropping to the ureter and causing an obstruction. Unfortunately, there is no direct remedy for this other than surgery at this time. Recommend a urinalysis and culture and monitoring with ultrasound +/- radiographs if the stones can be seen on films. Vigilance in monitoring this is recommended at this time rather than intervention, as these stones could sit there quietly for an indeterminate amount of time. Monitoring will help to determine if an active obstruction is present. Consider recheck ultrasound in 2-4 weeks, earlier if there are any concerns regarding abdominal pain, etc.

The first step in evaluation of the calcium is getting an ionized calcium, PTH and PTHrP level performed to see if this is a real significant hypercalcemia. Additionally, careful palpation of the anal glands on rectal exam and a good oral exam to look for any mass effects is recommended. If the ionized calcium is elevated, then recommended 3-view thoracic radiographs.





The information and recommendations provided are based on the images presented by the referring veterinarian. No evaluation can be communicated regarding pathology that was not visible in the image/video clips provided.

Thank you for this referral. If the clinical or image interpretation does not parallel your findings or if I can be of any further assistance please contact me.

Kathleen Sennello DVM,MS, Diplomate ACVIM (Small animal Internal Medicine)
kathleen.sennello@sonopath.com