

**DATE PRESENTING CLINICAL SIGNS**

1/5/23 Presented for wellness 12/30/22, mild lethargy noted at home and mild cough. Moderate to severe dental disease, salivary staining and prominent submandibular lymph nodes on exam. Labs showed lymphocytosis but no other significant abnormalities. Flow cytometry pending.

**PATIENT**

Mikey Wallace

Current Medications: clavamox drops started 1/4/22

Lab Results: 12/30/22: lymphocytosis 7490, GGT 21

Radiographs: chest x-rays 12/30/22: NSF

Date of Previous IntraPet Ultrasound: No previous.

Sedation: Not required to complete full diagnostic ultrasound.

Stat Report: Not requested.

Imaging Performed By: Rachel Brillhart, RDMS.

**SPECIES**

Canine

**BREED**

Chihuahua

**ULTRASONOGRAPHIC EXAMINATION OF THE ABDOMEN****SEX**

Neutered Male

**Urinary System**

The urinary bladder is moderately distended with anechoic urine. The Bladder wall, trigone, ureteral papillae and visible urethra (to a depth of 2cm) appear normal with no evidence of wall thickening, mucosal irregularities, masses or cystic calculi.

**AGE**

2/4/12

The prostate is normal in size (0.76 cm) and shape for this neutered male dog. The parenchyma is homogenous and the external margins are smooth. The prostatic urethra appears normal with no evidence of irregularity, invasion, mass effect or calculi.

**WEIGHT**

5.6 Pounds

The left kidney has a normal shape and size (3.67 cm). Overall echogenicity is normal with adequate corticomedullary distinction and a typical 1:3 cortex:medulla ratio. There is no evidence of focal perinephric inflammation or effusion. There is no evidence of pyelectasia, nephroliths, infarcts or hydroureter. Renal vasculature is normal.

**INTERPRETED BY**

Kathleen Sennello DVM,  
MS, Diplomate ACVIM  
(Small Animal Internal  
Medicine)

The right kidney has a normal shape and size (3.67 cm). Overall echogenicity is normal with adequate corticomedullary distinction and a typical 1:3 cortex:medulla ratio. There is no evidence of focal perinephric inflammation or effusion. There is no evidence of pyelectasia, nephroliths, infarcts or hydroureter. Renal vasculature is normal.

**HOSPITAL NAME**

Everhart Vet Hospital

**Adrenal Glands**

The left adrenal gland is normal in size measuring 0.61 cm at the caudal pole. It is observed in its normal position cranial to the left renal artery. It is normal in appearance (uniformly hypoechoic) and shape with no evidence of a mass effect.

**REFERRING VET**

Dr. Notarangelo

The right adrenal gland is normal in size measuring 0.61 cm at the caudal pole. It is observed in its normal position between the cranial aspect of the right kidney and the caudal vena cava. It is normal in appearance (uniformly hypoechoic) and shape with no evidence of a mass effect.

**INVOICE**

43971

**Spleen**

The spleen is subjectively normal in size, echotexture is homogenous, and the splenic capsule is smooth with no irregularities. The blood flow through the hilus and splenic parenchyma appears normal. No focal parenchymal abnormalities are visualized.

**Liver**

The liver is subjectively normal in size, and echogenicity with smooth peripheral margins. The parenchyma is homogenous echotexture. The visible portions of the vasculature and biliary tract appear normal. No focal nodules or cystic lesions are observed.

The gall bladder lumen is significantly distended. The wall is slightly prominent at 0.23 cm with adherent debris. There is a large amount of primarily non-organized echogenic debris. There is no evidence of bile duct dilation.

### ***Gastrointestinal***

The stomach contains minimal luminal contents. It measures at a normal thickness of <0.7cm with some variability due to the presence of rugal folds. The distinction of the gastric wall layers is adequate and there is no impression of reduced peristaltic activity. No masses or focal lesions were observed.

The visualized areas of duodenum, jejunum and ileum have a relatively uniform diameter with minimal fluid distension. Wall thickness is normal. Bowel loops follow a curvilinear path with distinct wall layering maintaining the typical 1:3 muscularis:mucosa layer ratio. Jejunum wall measures 0.25 cm. Visualized peristalsis appears appropriate. There were no focal lesions consistent with obstruction or a mass effect observed.

The ileocecal junction was visualized and exhibited normal intact wall layering and is subjectively of normal thickness. Sections of colon are visualized with formed fecal material and gas shadowing distally. There is no observed focal or generalized colon wall thickening or loss of layering.

### ***Pancreas***

The pancreas is normal and isoechoic to surrounding mesentery. There is no evidence of nodules or cystic lesions. There is no evidence of regional mesenteric inflammation or fluid.

### ***Free Abdomen***

Evaluation of the peritoneal cavity did not reveal any evidence of effusion. There are prominent sublumbar lymph nodes and occasional mesenteric lymph nodes. Sublumbar lymph nodes measure at 0.41 cm and 0.41 cm in width. The omentum is of normal echogenicity.

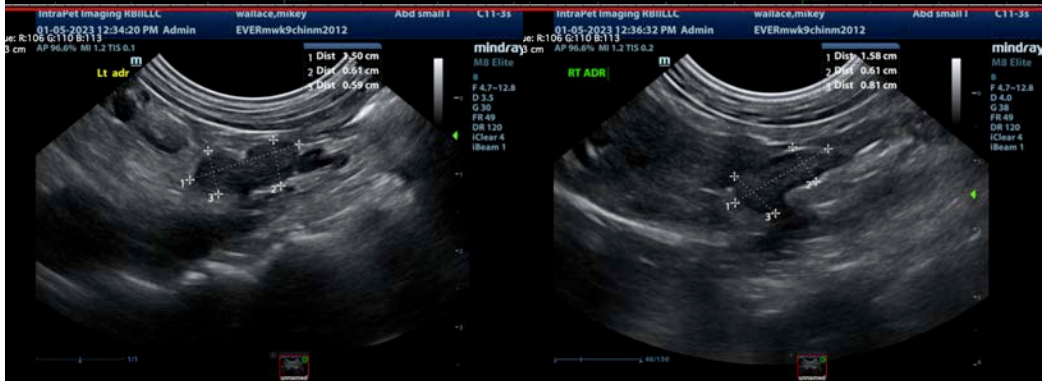
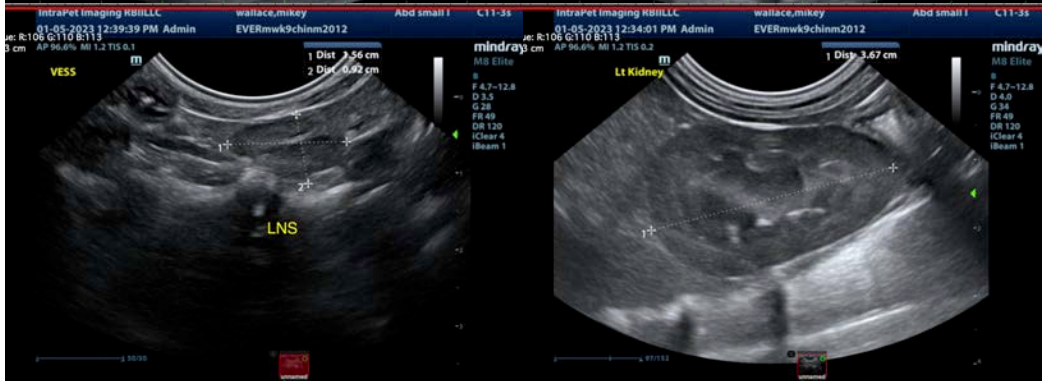
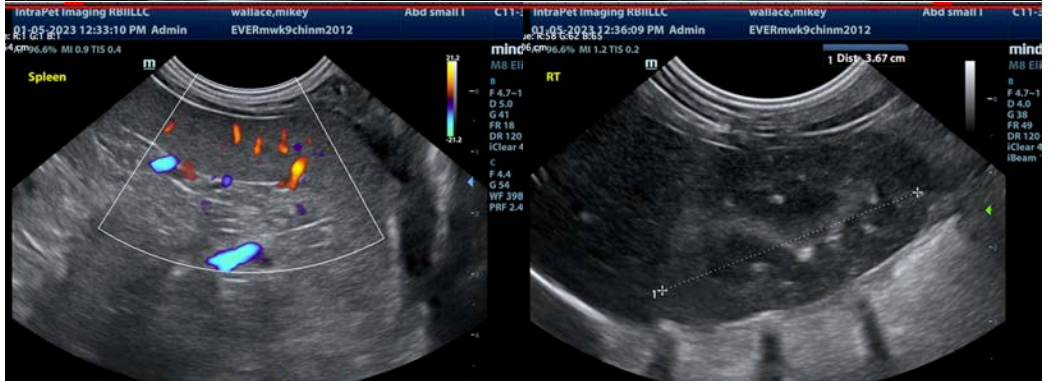
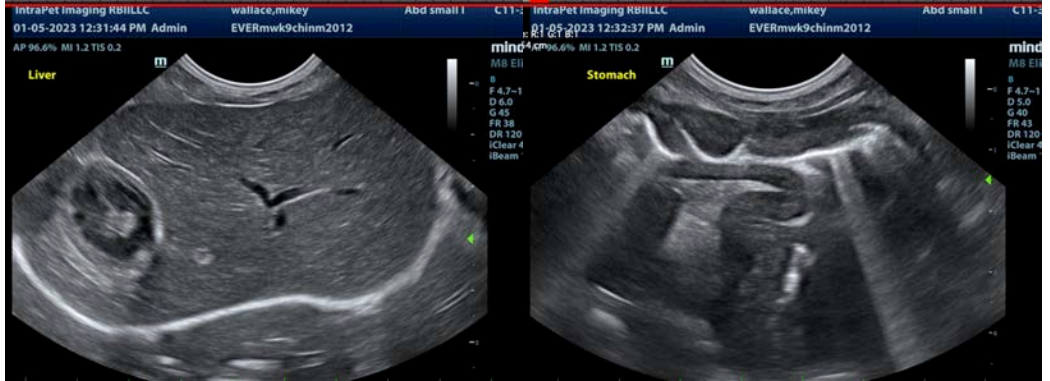## **ULTRASONOGRAPHIC FINDINGS**

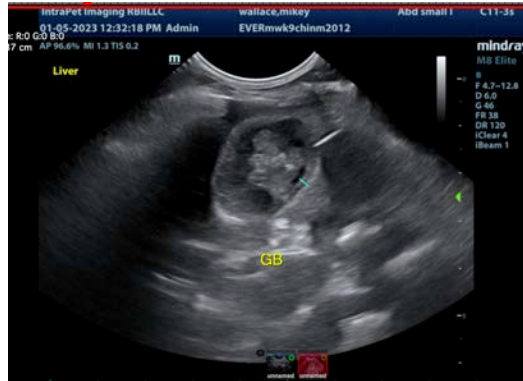- Large amount of gallbladder debris with mild gallbladder wall thickening and adherent debris – A large amount of debris is evident in the gall bladder with no evidence of a mucocele or associated inflammation at this time. This could represent an early mucocele or cholestasis, with minimal evidence of associated inflammation at this time. Continued monitoring of labwork and ultrasound are warranted for progression of this lesion. Ursodiol therapy could be considered.
- Mildly enlarged/prominent sublumbar and mesenteric lymph nodes – The prominent abdominal lymph nodes are most consistent with reactive lymphadenitis or lymphoid hyperplasia. Neoplastic infiltration is considered less likely.

## **INTERPRETATION OF THE FINDINGS & FURTHER RECOMMENDATIONS**

There are no overt mass lesion observed on today's scan, and the prominent sublumbar lymph nodes are likely not large enough to easily sample. The gallbladder does appear to have a large amount of adhered debris to the gallbladder wall, and the wall appears mildly thickened. If liver enzyme elevations are present, recommend continued monitoring of the gallbladder +/- chronic Ursodiol therapy.

Your plan for further evaluation of the lymphocytosis is very appropriate. Recommend 3-view thoracic radiographs (if not already done).





**The information and recommendations provided are based on the images presented by the referring veterinarian/sonographer. No evaluation can be communicated regarding pathology that was not visible in the image/video clips provided.**

Thank you for this referral. If the clinical or image interpretation does not parallel your findings or if I can be of any further assistance please contact me.

Kathleen Sennello DVM,MS, Diplomate ACVIM (Small animal Internal Medicine)  
kathleen.sennello@sonopath.com