

**DATE PRESENTING CLINICAL SIGNS**

1/5/23 Follow up u/s from 6/24/22 - see full report. Has HX of 1/2/6 heart murmur left mitral 7/14/22.

PATIENT

Current Medications: Purina EN, Prednisone rx last 8/22/22

Jessa Noye

Lab Results: BW 8/1/22, ER 7/15/22, ALT -251, ALKP- 218, THILI-1.1
BG-169.

Date of Previous IntraPet Ultrasound: 6/24/22. See attached.

Sedation: Not required to complete full diagnostic ultrasound.

SPECIES

Stat Report: Not requested.

Canine

Imaging Performed By: Andi Parkinson, BS, RDMS.

BREED**ULTRASONOGRAPHIC EXAMINATION OF THE ABDOMEN**

American Pit Bull X

Urinary System

The urinary bladder is moderately distended with anechoic urine. The Bladder wall, trigone, ureteral papillae and visible urethra (to a depth of 2cm) appear normal with no evidence of wall thickening, mucosal irregularities, masses or cystic calculi.

SEX

Spayed Female

The left kidney has a normal shape and size (6.26 cm). Overall echogenicity is normal with adequate corticomedullary distinction and a typical 1:3 cortex:medulla ratio. There is no evidence of focal perinephric inflammation or effusion. There is no evidence of pyelectasia, nephroliths, infarcts or hydroureter. Renal vasculature is normal.

AGE

12/2/09

The right kidney has a normal shape and size (6.26 cm). Overall echogenicity is normal with adequate corticomedullary distinction and a typical 1:3 cortex:medulla ratio. There is no evidence of focal perinephric inflammation or effusion. There is no evidence of pyelectasia, nephroliths, infarcts or hydroureter. Renal vasculature is normal.

WEIGHT

57 Pounds

INTERPRETED BY

Kathleen Sennello DVM,
MS, Diplomate ACVIM
(Small Animal Internal
Medicine)

Adrenal Glands

The left adrenal gland is normal in size measuring 0.95 cm at the caudal pole. It is observed in its normal position cranial to the left renal artery. It is normal in appearance (uniformly hypoechoic) and shape with no evidence of a mass effect.

HOSPITAL NAME

Bel Air VH

The right adrenal gland is normal in size measuring 0.64 cm at the caudal pole. It is observed in its normal position between the cranial aspect of the right kidney and the caudal vena cava. It is normal in appearance (uniformly hypoechoic) and shape with no evidence of a mass effect.

REFERRING VET

Dr. Stevenson

Spleen

The spleen is subjectively normal in size, echotexture is homogenous, and the splenic capsule is smooth with no irregularities. The blood flow through the hilus and splenic parenchyma appears normal. No focal parenchymal abnormalities are visualized.

INVOICE

43987

Liver

The liver is subjectively normal in size, and echogenicity with smooth peripheral margins. The parenchyma is homogenous echotexture. The visible portions of the vasculature and biliary tract appear normal. No focal nodules or cystic lesions are observed.

The gall bladder lumen is moderately distended. The wall of the gall bladder is not thickened and has a smooth mucosal surface. There is a moderate amount of non-organized echogenic debris. The cystic and common bile ducts are normal/not visible.

Gastrointestinal

The stomach is moderately dilated with fluid and irregular shadowing material most consistent with normal ingesta and gas. It measures at a normal thickness of <0.7cm with some variability due to the presence of rugal folds. The distinction of the gastric wall layering is adequate and there is no impression of reduced peristaltic activity. No masses or focal lesions were observed.

The visualized areas of duodenum, jejunum and ileum have a relatively uniform diameter with minimal fluid distension. Wall thickness is normal. Bowel loops follow a curvilinear path with distinct wall layering maintaining the typical 1:3 muscularis:mucosa layer ratio. The duodenum measured as normal (between 0.3-0.5cm in wall thickness) and the jejunum measured as normal (between 0.2-0.47cm.) Visualized peristalsis appears appropriate. There were no focal lesions consistent with obstruction or a mass effect observed.

The ileocecal junction was visualized and exhibited normal intact wall layering and is subjectively of normal thickness. Sections of colon are visualized with formed fecal material and gas shadowing distally. There is no observed focal or generalized colon wall thickening or loss of layering.

Pancreas

The pancreas is normal and isoechoic to surrounding mesentery. There is no evidence of nodules or cystic lesions. There is no evidence of regional mesenteric inflammation or fluid.

Free Abdomen

Evaluation of the peritoneal cavity did not reveal any evidence of effusion, or subjective lymphadenomegaly. The Medial iliac nodes appear normal and there was no evidence of a caudal aortic thrombus at the bifurcation. The omentum is of normal uniform echogenicity.

Other

The uterine stump is visualized and measures 0.75 cm in diameter (previous measurement 0.89 cm), and there is significantly less inflammation surrounding the uterine stump.

PRIMARY FINDINGS

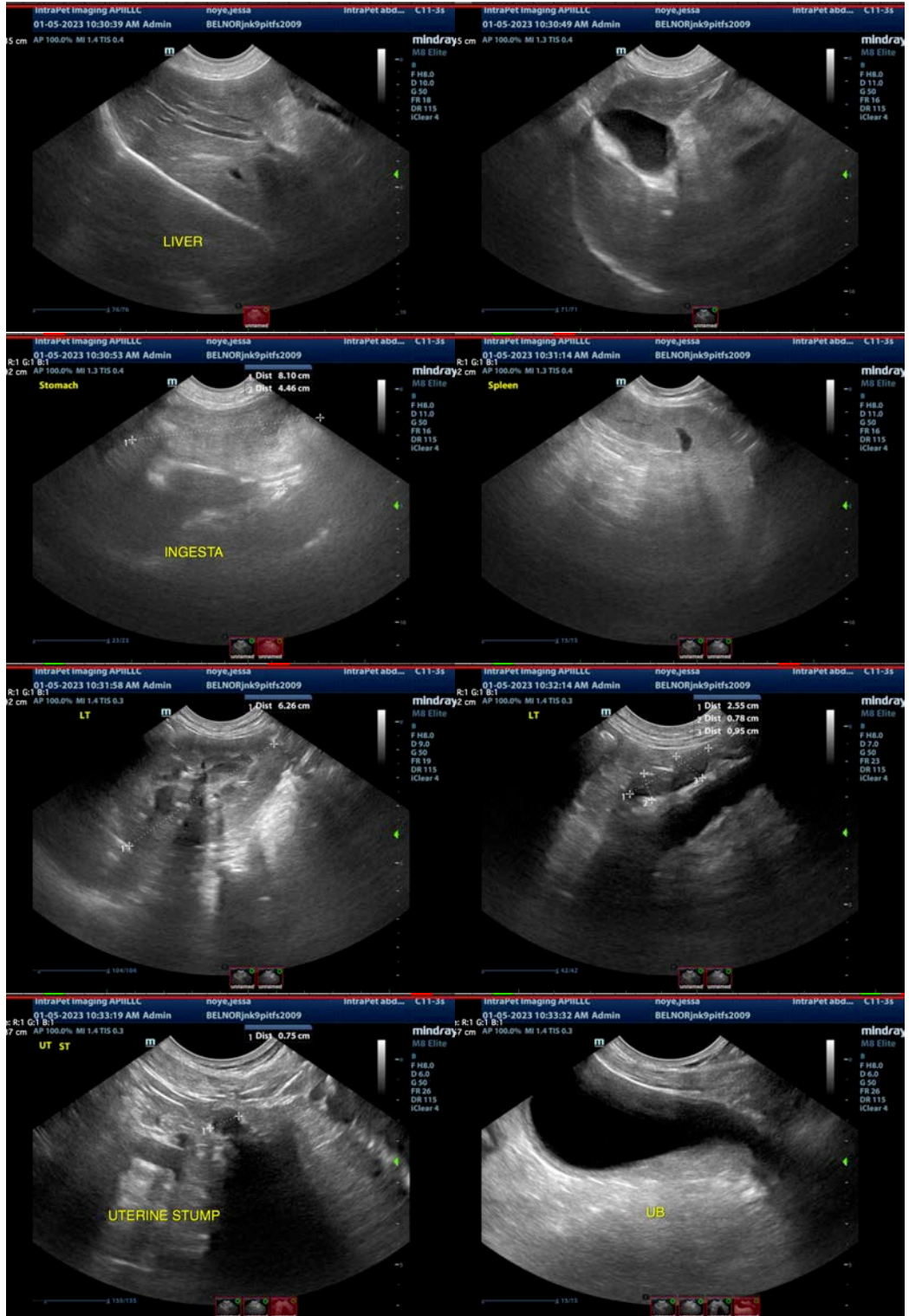
- Uterine stump appears less prominent and less inflamed on today's exam.

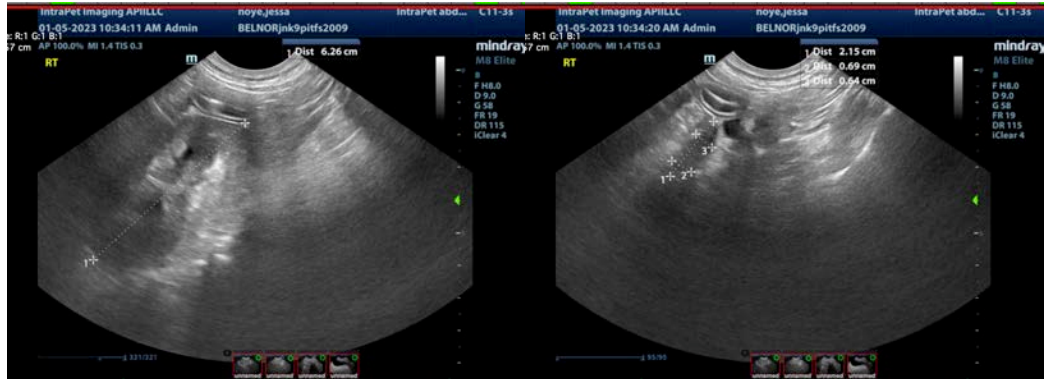
SECONDARY FINDINGS

- Mild gallbladder debris – The significance of the aggregated gallbladder debris is unclear. This could represent an early mucocele, cholestasis, or may be secondary to fasting but seems unlikely to be causing a current issue. Recommend continued monitoring.
- Moderate ingesta within the gastric lumen – Findings are most consistent with a non-fasted patient.

INTERPRETATION OF THE FINDINGS & FURTHER RECOMMENDATIONS

Today's scan is essentially normal for a geriatric canine. The previously prominent uterine stump appears much more normal today. If clinical signs have improved as well, then continued monitoring is warranted. If signs persist, then recommend vaginoscopy/cystoscopy.





The information and recommendations provided are based on the images presented by the referring veterinarian/sonographer. No evaluation can be communicated regarding pathology that was not visible in the image/video clips provided.

Thank you for this referral. If the clinical or image interpretation does not parallel your findings or if I can be of any further assistance please contact me.

Kathleen Sennello DVM,MS, Diplomate ACVIM (Small animal Internal Medicine)
kathleen.sennello@sonopath.com