



PATIENT

Chase Wald

SPECIES

Canine

BREED

Golden Retriever

SEX

Neutered Male

AGE

9 Years

WEIGHT

76 Pounds

INTERPRETED BY

Kathleen Sennello DVM,
MS, Diplomate ACVIM
(Small Animal Internal
Medicine)

**IMAGING
PERFORMED BY**

Dr. Megan Cassels-
Conway

HOSPITAL NAME

Central Broward AH

REFERRING VET

Dr. Johnathan Wald

INVOICE

43962

DATE

1/5/23

PRESENTING CLINICAL SIGNS

Mild decreased appetite and energy waxing and waning past few weeks. Did improve on carprofen. Abdominal rads showed mid-abdominal mass, likely splenic. Thoracic rads showed possible sternal lymphadenopathy. CBC/chem/UA pending, 4dx pending, Lyme titer. Does spend at least half year in Massachusetts.

Abnormal PE/Chem/CBC/UA Results: 11/18/22: CBC/chem/UA WNL BW today pending

ULTRASONOGRAPHIC EXAMINATION OF THE ABDOMEN

Urinary System

The urinary bladder is moderately distended with anechoic urine. The Bladder wall, trigone, ureteral papillae and visible urethra (to a depth of 2cm) appear normal with no evidence of wall thickening, mucosal irregularities, masses or cystic calculi.

The visualized areas of prostate and surrounding tissue appear normal. Unfortunately, the prostate is not fully visualized likely due to its intrapelvic location. Correlate with rectal exam findings.

The left kidney has a normal shape and size (7.68 cm). Overall echogenicity is normal with adequate corticomedullary distinction and a typical 1:3 cortex:medulla ratio. There is no evidence of focal perinephric inflammation or effusion. There is no evidence of pyelectasia, nephroliths, infarcts or hydroureter. Renal vasculature is normal.

The right kidney has a normal shape and size (7.76 cm). Overall echogenicity is normal with adequate corticomedullary distinction and a typical 1:3 cortex:medulla ratio. There is no evidence of focal perinephric inflammation or effusion. There is no evidence of pyelectasia, nephroliths, infarcts or hydroureter. Renal vasculature is normal.

Adrenal Glands

The left adrenal gland is normal in size measuring 1.0 cm at the caudal pole. It is observed in its normal position cranial to the left renal artery. It is normal in appearance (uniformly hypoechoic) and shape with no evidence of a mass effect.

The right adrenal gland is normal in size measuring 0.69 cm at the caudal pole. It is observed in its normal position between the cranial aspect of the right kidney and the caudal vena cava. It is normal in appearance (uniformly hypoechoic) and shape with no evidence of a mass effect.

Spleen

The spleen is large, irregular, and mottled. The blood flow through the hilus and splenic parenchyma appears normal. Much of the normal splenic parenchyma is comprised of numerous hypoechoic heterogeneous mass lesions. There is a large cavitated mass lesion at the head of the spleen measuring 11.61 cm x 12.04 cm. There are multiple mid body splenic masses and a mass at the tail measuring 2.99 cm in diameter.

Liver

The liver is subjectively normal in size, but irregular. The parenchyma is mildly heterogenous in echotexture with subtle, indistinct focal mottling. The visible portions of the vasculature and biliary tract appear normal. There are numerous hypoechoic, some what "target" type nodules/mass lesions within the liver. Examples measure 1.45 cm x 0.78 cm, 1.8 cm x 1.64 cm, and 5.23 cm x 3.05 cm.



PATIENT

Chase Wald

The gall bladder lumen is moderately distended. The wall of the gall bladder is not thickened and has a smooth mucosal surface. There is a moderate amount of non-organized echogenic debris. The cystic and common bile ducts are normal/not visible.

SPECIES

Canine

Gastrointestinal

The stomach contains minimal luminal contents. It measures at a normal thickness of <0.7cm with some variability due to the presence of rugal folds. The distinction of the gastric wall layers is adequate and there is no impression of reduced peristaltic activity. No masses or focal lesions were observed.

BREED

Golden Retriever

The visualized areas of duodenum, jejunum and ileum have a relatively uniform diameter with minimal fluid distension. Wall thickness is normal. Bowel loops follow a curvilinear path with distinct wall layering maintaining the typical 1:3 muscularis:mucosa layer ratio. The duodenum measured as normal (between 0.3-0.5cm in wall thickness) and the jejunum measured as normal (between 0.2-0.47cm.)

SEX

Neutered Male

Visualized peristalsis appears appropriate. There were no focal lesions consistent with obstruction or a mass effect observed.

AGE

9 Years

The ileocecal junction was visualized and exhibited normal intact wall layering and is subjectively of normal thickness. Sections of colon are visualized with formed fecal material and gas shadowing distally. There is no observed focal or generalized colon wall thickening or loss of layering.

Pancreas

The pancreas is normal and isoechoic to surrounding mesentery. There is no evidence of nodules or cystic lesions. There is no evidence of regional mesenteric inflammation or fluid.

WEIGHT

76 Pounds

Free Abdomen

Evaluation of the peritoneal cavity did not reveal any evidence of effusion, or subjective lymphadenomegaly. The Medial iliac nodes appear normal and there was no evidence of a caudal aortic thrombus at the bifurcation. The omentum is hyperechoic surrounding the splenic masses.

INTERPRETED BY

Kathleen Sennello DVM,
MS, Diplomate ACVIM
(Small Animal Internal
Medicine)

ULTRASONOGRAPHIC FINDINGS

- Large, irregular spleen with numerous large, hypoechoic masses. One of the masses is cavitated. These masses distort the splenic capsule. Differentials neoplasia (e.g., hemangiosarcoma, hemangioma), hematoma, abscess, other. A neoplastic process is favored.
- Irregular, heterogeneous liver with hypoechoic target type nodules – The diffuse hepatic changes are non-specific and could be consistent with vacuolar hepatopathy, nodular hyperplasia, inflammatory/immune-mediated disease, fibrosis, extramedullary hematopoiesis, toxic hepatopathy (e.g., copper), infiltrative neoplasia (less likely) or other hepatopathy. These lesions are concerning for (but not diagnostic for) possible metastatic disease.

IMAGING PERFORMED BY

Dr. Megan Cassels-Conway

HOSPITAL NAME

Central Broward AH

REFERRING VET

Dr. Johnathan Wald

INVOICE

43962

DATE

1/5/23

INTERPRETATION OF THE FINDINGS & FURTHER RECOMMENDATIONS

The majority of the spleen is occupied by large, irregular, expansile, hypoechoic mass lesions. Some of these have cavitated regions. The appearance of these lesions is highly concerning for neoplastic process, although other differentials are possible.

Additionally, there are numerous hypoechoic nodules in the liver with a more hypoechoic center, having a target type appearance (or possibly cavitated), which is concerning for possible metastatic nodules. Some of these nodules are more superficial in the ventral aspect of the liver and could be potentially aspirated.



PATIENT

Chase Wald

Options would include splenectomy with histopathology and biopsy of a hepatic nodule, fine needle aspirate of a hepatic nodule to decide if splenectomy will be pursued, or palliative therapy (including consultation with a veterinary oncologist regarding possible chemotherapeutic options).

SPECIES

Canine

Recommend three view thoracic radiographs to evaluate for possible concurrent thoracic disease/involvement.

BREED

Golden Retriever

SEX

Neutered Male

AGE

9 Years

WEIGHT

76 Pounds

INTERPRETED BY

Kathleen Sennello DVM,
MS, Diplomate ACVIM
(Small Animal Internal
Medicine)

**IMAGING
PERFORMED BY**

Dr. Megan Cassels-
Conway

HOSPITAL NAME

Central Broward AH

REFERRING VET

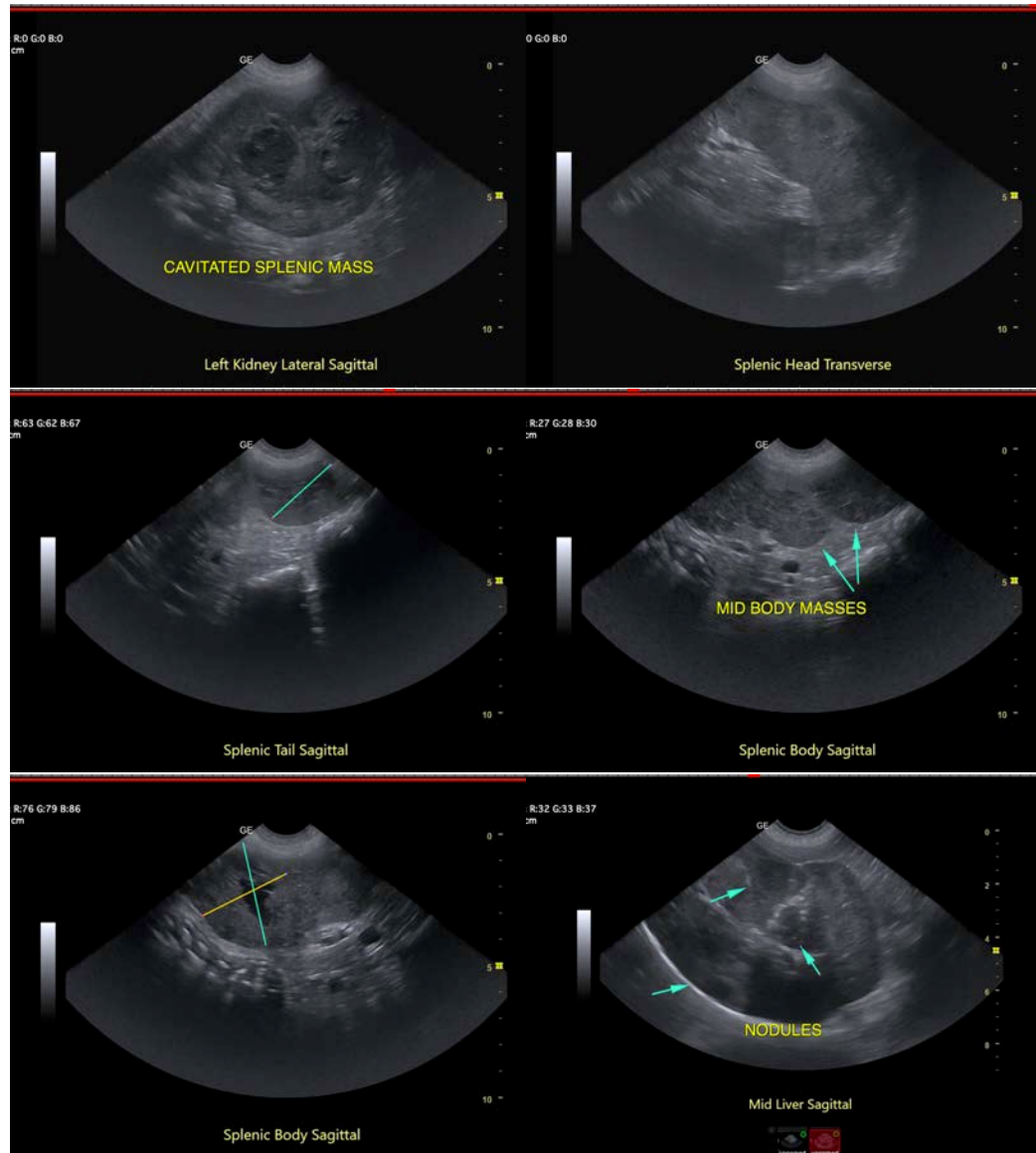
Dr. Johnathan Wald

INVOICE

43962

DATE

1/5/23





PATIENT

Chase Wald

SPECIES

Canine

BREED

Golden Retriever

SEX

Neutered Male

AGE

9 Years

WEIGHT

76 Pounds

INTERPRETED BY

Kathleen Sennello DVM,
MS, Diplomate ACVIM
(Small Animal Internal
Medicine)

**IMAGING
PERFORMED BY**

Dr. Megan Cassels-
Conway

HOSPITAL NAME

Central Broward AH

REFERRING VET

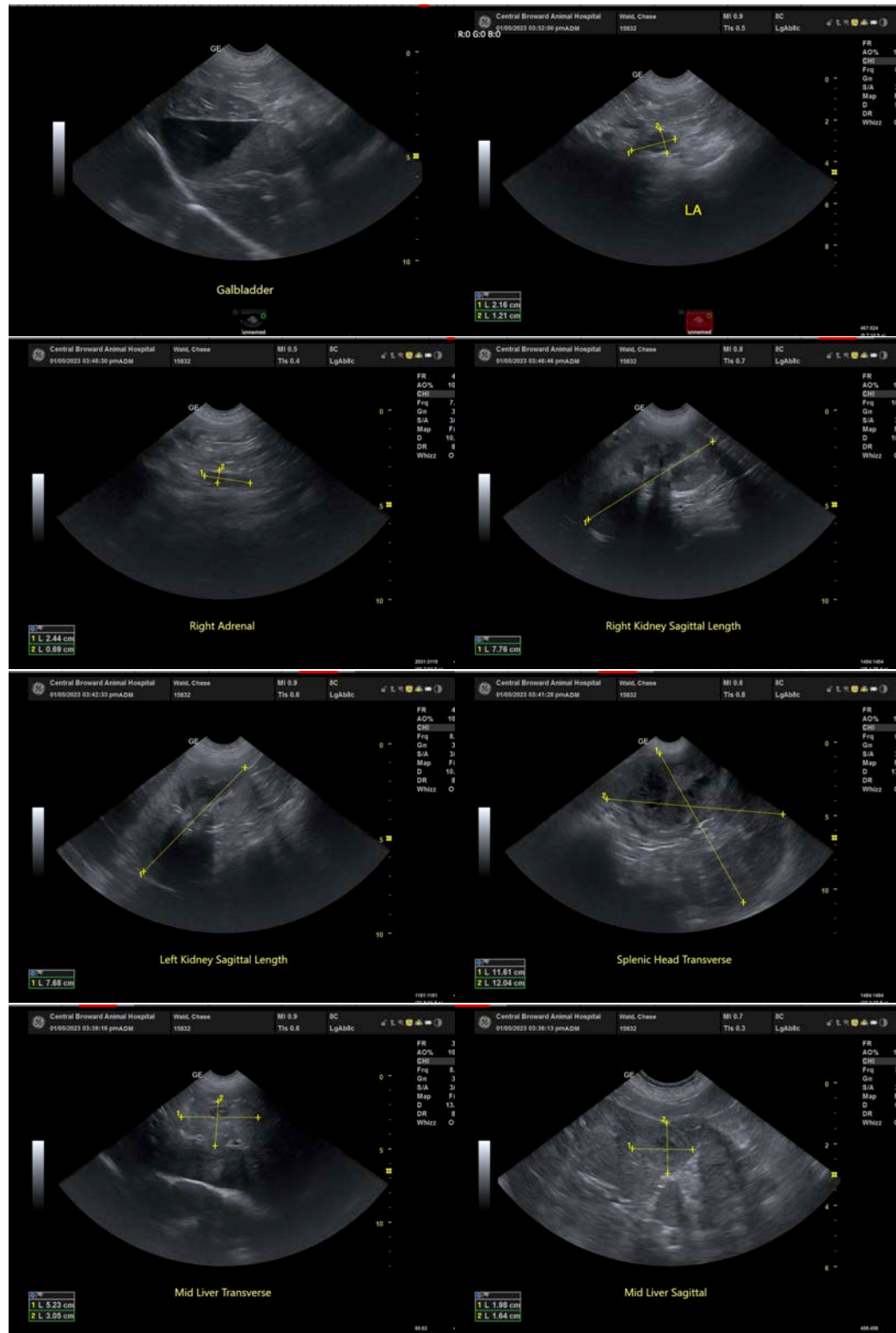
Dr. Johnathan Wald

INVOICE

43962

DATE

1/5/23





PATIENT

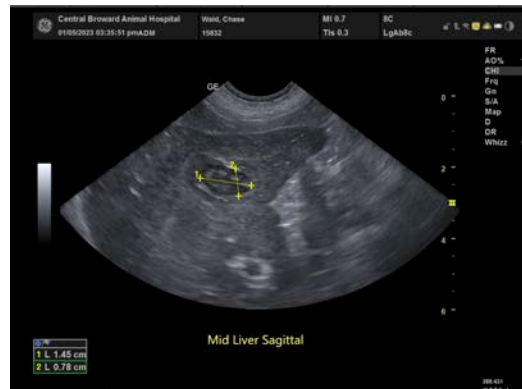
Chase Wald

SPECIES

Canine

BREED

Golden Retriever



SEX

Neutered Male

The information and recommendations provided are based on the images presented by the referring veterinarian/sonographer. No evaluation can be communicated regarding pathology that was not visible in the image/video clips provided.

AGE

9 Years

Thank you for this referral. If the clinical or image interpretation does not parallel your findings or if I can be of any further assistance please contact me.

Kathleen Sennello DVM,MS, Diplomate ACVIM (Small animal Internal Medicine)

kathleen.sennello@sonopath.com

WEIGHT

76 Pounds

INTERPRETED BY

Kathleen Sennello DVM,
MS, Diplomate ACVIM
(Small Animal Internal
Medicine)

**IMAGING
PERFORMED BY**

Dr. Megan Cassels-
Conway

HOSPITAL NAME

Central Broward AH

REFERRING VET

Dr. Johnathan Wald

INVOICE

43962

DATE

1/5/23