

**DATE PRESENTING CLINICAL SIGNS**

1/5/23 Vomiting, decreased appetite, and 5lb weight loss in about 4 months.  
Bloodwork (including T4) unremarkable.

**PATIENT**

Cash Bluebaugh-Elder

Current Medications: 12mg Cerenia started on 01/02/2023

Lab Results: See attached.

Date of Previous IntraPet Ultrasound: No previous.

Sedation: Not required to complete full diagnostic ultrasound.

Stat Report: Not requested.

Imaging Performed By: Rachel Brillhart, RDMS.

**SPECIES**

Feline

**BREED**

Maine Coon X

**SEX**

Neutered Male

**AGE**

11/29/12

**WEIGHT**

11.4 Pounds

**INTERPRETED BY**

Kathleen Sennello DVM,  
MS, Diplomate ACVIM  
(Small Animal Internal  
Medicine)

**HOSPITAL NAME**

Everhart Vet Hospital

**REFERRING VET**

Dr. DeFavero

**INVOICE**

43968

**ULTRASONOGRAPHIC EXAMINATION OF THE ABDOMEN****Urinary System**

The urinary bladder is moderately distended with anechoic urine. The Bladder wall, trigone, ureteral papillae and visible urethra (to a depth of 2cm) appear normal with no evidence of wall thickening, mucosal irregularities, masses or cystic calculi.

The left kidney has a normal shape and size (3.88 cm). Overall echogenicity is normal with adequate corticomedullary distinction and a typical 1:3 cortex:medulla ratio. There is no evidence of focal perinephric inflammation or effusion. There is no evidence of pyelectasia, nephroliths, infarcts or hydroureter. Renal vasculature is normal.

The right kidney has a normal shape and size (4.19 cm). Overall echogenicity is normal with adequate corticomedullary distinction and a typical 1:3 cortex:medulla ratio. There is no evidence of focal perinephric inflammation or effusion. There is no evidence of pyelectasia, nephroliths, infarcts or hydroureter. Renal vasculature is normal.

**Adrenal Glands**

The left adrenal gland is normal in size measuring 0.42 cm at the caudal pole. It is observed in its normal position cranial to the left renal artery. It is normal in appearance (uniformly hypoechoic) and shape with no evidence of a mass effect.

The right adrenal gland is normal in size measuring 0.36 cm at the caudal pole. It is observed in its normal position between the cranial aspect of the right kidney and the caudal vena cava. It is normal in appearance (uniformly hypoechoic) and shape with no evidence of a mass effect.

**Spleen**

The spleen is subjectively normal in size (0.91 cm in width at the level of the hilus), echotexture is homogenous, and the splenic capsule is smooth with no irregularities. The blood flow through the hilus and splenic parenchyma appears normal. No focal parenchymal abnormalities are visualized.

**Liver**

The liver is subjectively normal in size, and echogenicity with smooth peripheral margins. The parenchyma is homogenous echotexture. The visible portions of the vasculature and biliary tract appear normal. No focal nodules or cystic lesions are observed.

The gallbladder lumen is moderately distended. The wall of the gall bladder is not thickened and has a smooth mucosal surface. Luminal contents are mild and primarily anechoic. The cystic and common bile ducts are normal/not visible.

### ***Gastrointestinal***

The stomach contains minimal luminal contents. It measures at a normal thickness of <0.36cm with some variability due to the presence of rugal folds. The distinction of the gastric wall layers is adequate and there is no impression of reduced peristaltic activity. No masses or focal lesions were observed.

The visualized areas of duodenum, jejunum and ileum have a uniform diameter with minimal fluid distension. Wall thickness is normal to slightly increased. Bowel loops follow a typical curvilinear path with distinct wall layering, but some areas display a prominent muscularis layer which does not display the typical 1:3 muscularis:mucosa layer ratio. Duodenum wall measures 0.28 cm. Jejunum wall measures 0.23 cm. There is mucosal speckling visualized in many areas, particularly in the duodenum. Visualized peristalsis appears appropriate. There is a focal section of bowel that has significant wall thickening measuring at 0.37 cm. In this region, the bowel wall has a significant decrease in wall layering. This section of bowel extends for at least 3.2 cm.

The ileocecal junction was visualized and exhibited normal intact wall layering and is subjectively of normal thickness. Sections of colon are visualized with formed fecal material and gas shadowing distally. There is no observed focal or generalized colon wall thickening or loss of layering.

### ***Pancreas***

Both limbs of the pancreas prominent and hypoechoic as compared to the surrounding isoechoic mesentery. Near the mid body of the pancreas in the right cranial abdomen, there is a hypoechoic lesion measuring 1.42 cm x 0.94 cm that appears associated with the pancreas. This most closely resembles a pancreatic cyst or a cystic lymph node in the region, although a hypoechoic pancreatic mass cannot be excluded as a possibility. There is no evidence of regional mesenteric inflammation or fluid. Prominent pancreatic duct noted at 0.26 cm.

### ***Free Abdomen***

Evaluation of the peritoneal cavity did not reveal any evidence of effusion. There is a significant mesenteric lymphadenopathy with hypoechoic/cystic lymph nodes visualized around the ileocecal junction measuring 0.61, 0.60, and 0.47 cm. The omentum is hyperechoic, particularly around the abnormal thickened section of small intestine.

## **ULTRASONOGRAPHIC FINDINGS**

- Hypoechoic, prominent pancreas with prominent pancreatic duct and a focal hypoechoic structure – Findings are most consistent with either mild current pancreatitis or previous episodes of pancreatic inflammation. The focal hypoechoic structure is most consistent with a pancreatic cyst or cystic lymph node in the region, although a pancreatic mass cannot be excluded as a possibility.
- Diffuse small intestinal thickening with a prominent muscularis layer and mucosal speckling – Bright mucosal speckling has been postulated to represent dilated lacteals or focal accumulations of mucus, cellular debris, etc.. in the mucosal crypts. The small intestinal wall changes could be consistent with an underlying inflammatory process. These types of changes can sometimes be seen in normal older cats. Correlate with clinical signs.
- Focal section of small intestine with significant wall thickening and reduced detail of wall layering – Findings are concerning for possible infiltrative disease (round cell neoplasia, carcinoma, etc.), focal inflammation, etc.
- Moderate mesenteric lymphadenopathy – The moderate mesenteric lymphadenopathy could be concerning for a neoplastic process, although you can see significant lymphadenopathy in some cases of autoimmune/inflammatory disease, infectious disease (tick born disease-such as bartonella,

fungal infections, FIP (cats)) etc. A fine needle aspirate with cytology is recommended for further evaluation.

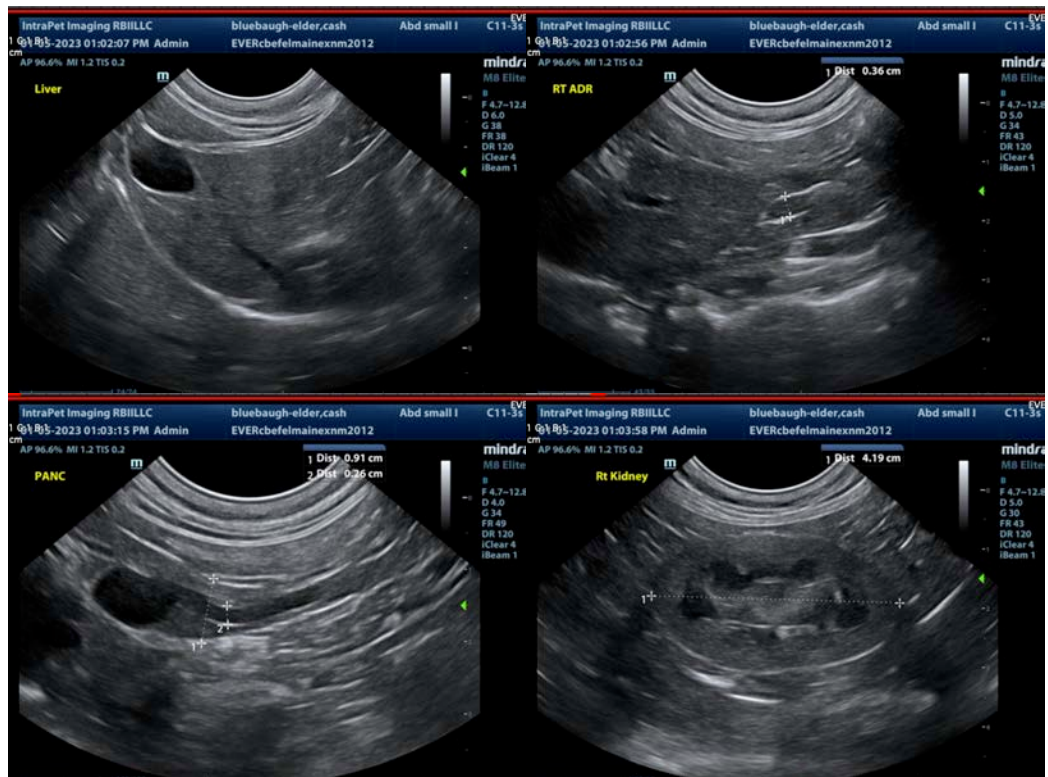
### INTERPRETATION OF THE FINDINGS & FURTHER RECOMMENDATIONS

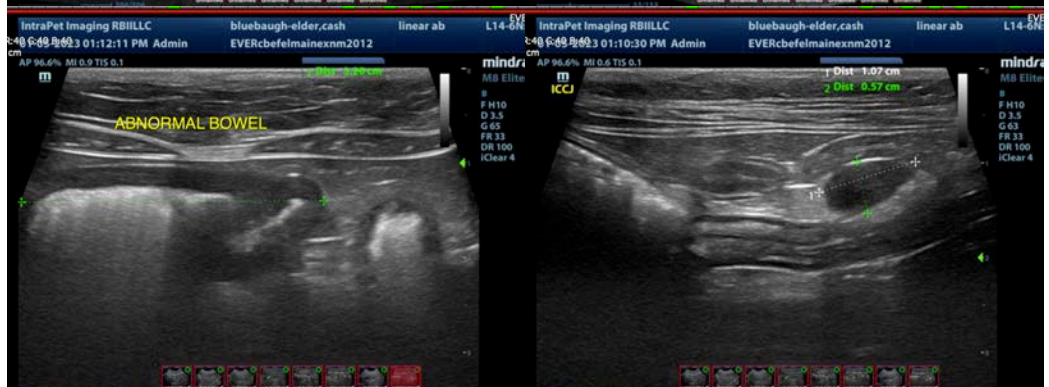
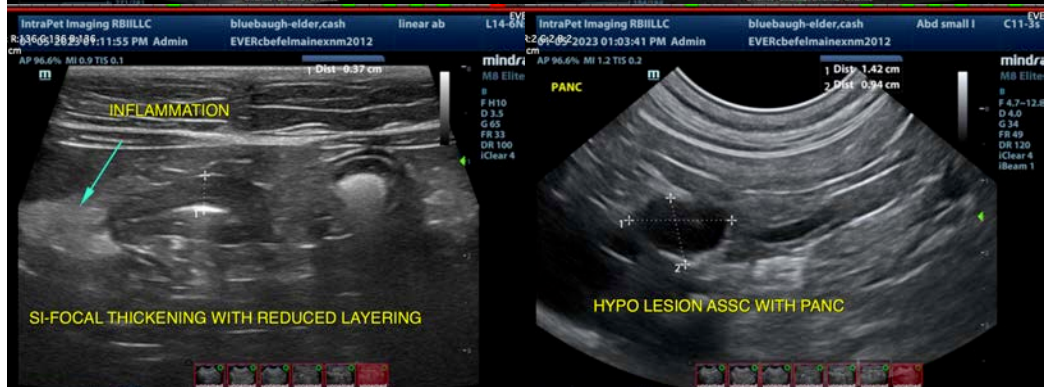
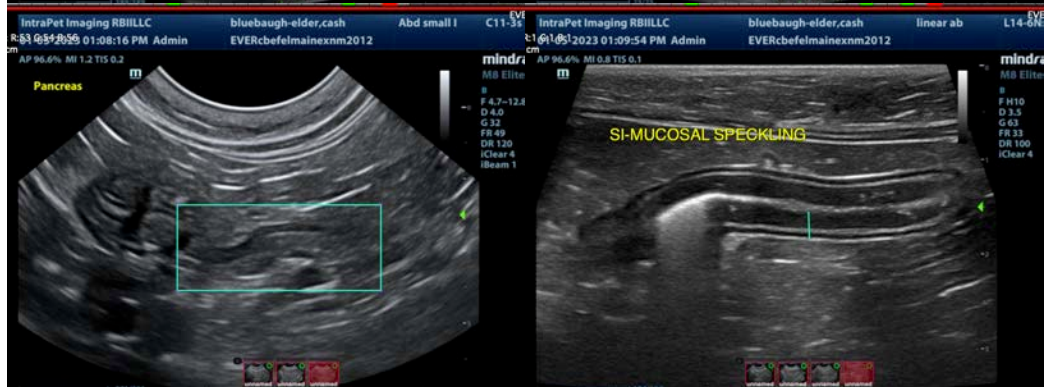
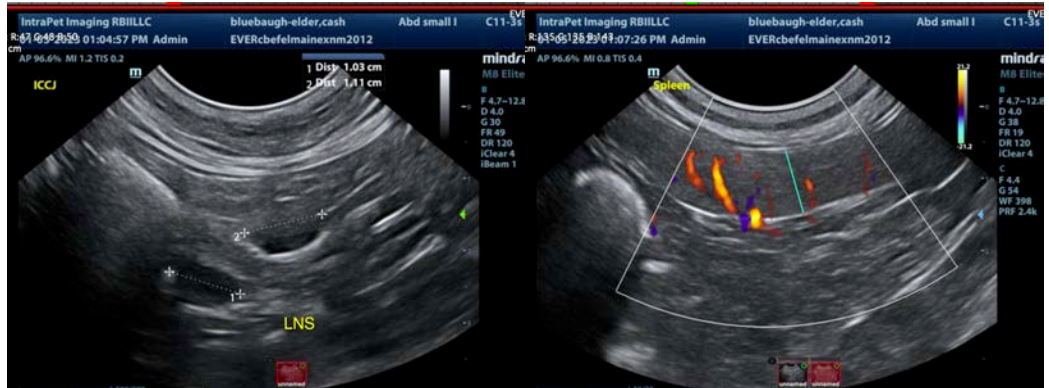
There is the impression of diffuse bowel thickening with mucosal speckling and a prominent muscularis layer, but a focal section of bowel has significant loss of layering and further thickening that is concerning for a possible neoplastic lesion, but there are other possibilities. Additionally, there is a significant mesenteric lymphadenopathy, with some of these lymph nodes appearing somewhat cystic. Consider a fine needle aspirate of a mesenteric lymph node. Aspiration of the wall of the abnormal bowel could be possible but may be tricky, as it is only moderately thickened.

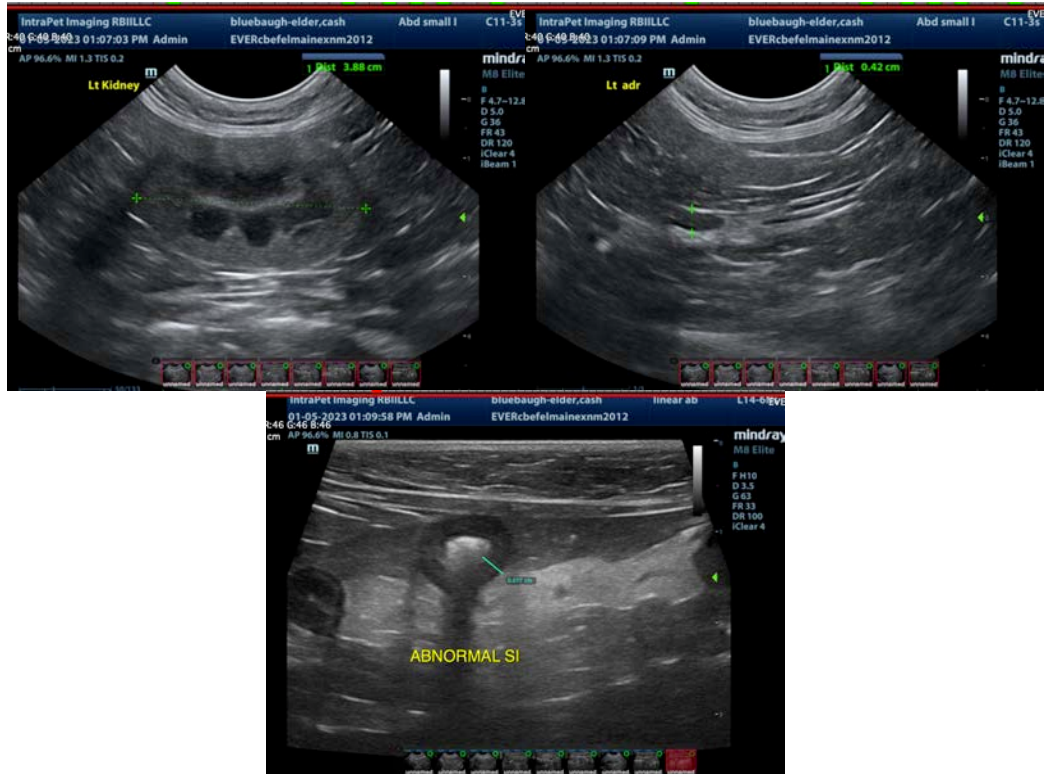
There is a hypochoic, rounded lesion associated with the body of the pancreas. I suspect this is a cystic lymph node or a pancreatic cyst, although a pancreatic mass effect cannot be ruled out. A fine needle aspirate of this lesion could be considered.

Recommend three view thoracic radiographs to evaluate for possible concurrent thoracic disease/involvement.

If a cytologic diagnosis cannot be obtained, surgical biopsies may be necessary.







The information and recommendations provided are based on the images presented by the referring veterinarian/sonographer. No evaluation can be communicated regarding pathology that was not visible in the image/video clips provided.

Thank you for this referral. If the clinical or image interpretation does not parallel your findings or if I can be of any further assistance please contact me.

Kathleen Sennello DVM,MS, Diplomate ACVIM (Small animal Internal Medicine)  
kathleen.sennello@sonopath.com