

**IMAGING PERFORMED BY**

SVS Mobile Imaging MI 734-637-7711  
svsimagingmi@gmail.com

**PATIENT**

Biscuit Morrow

**SPECIES**

Feline

**BREED**

DSH

**SEX**

Neuterd Male

**AGE**

6 Years

**WEIGHT**

12 Pounds

**INTERPRETED BY**

Kathleen Sennello DVM,  
MS, Diplomate ACVIM  
(Small Animal Internal  
Medicine)

**IMAGING PERFORMED BY**

Amy Mayhew, LVT

**HOSPITAL NAME**

SVS Imaging MI

**REFERRING VET**

Cat Care of Rochester  
Hills - Dr. Hunt

**INVOICE**

43992

**DATE**

1/5/23

**PRESENTING CLINICAL SIGNS**

Chronic weight loss since August 2021 (was 14.7 lbs then, was 11.62 lbs in August 2022 and 12 lbs in November 2022. Pet is overweight. On-off chronic vomiting.

Abnormal PE/Chem/CBC/UA Results: Elevated renal values since August, no known toxin exposure or other medical history Did one course of Zeniquin in August. Lab values: see attached UA, CBC/Chem and abdominal rad. ProBNP normal, FPL wnl, T4 wnl, all else wnl except kidneys, UA: usg 1.043, no crystals, no evidence of infection Radiographs (left lateral abdomen): potential pinpoint shaped opacities at renal pelvis/hilus but unsure, kidneys difficult to assess

**ULTRASONOGRAPHIC EXAMINATION OF THE ABDOMEN****Urinary System**

The urinary bladder is moderately distended with anechoic urine. The Bladder wall, trigone, ureteral papillae and visible urethra (to a depth of 2cm) appear normal with no evidence of wall thickening, mucosal irregularities, masses or cystic calculi.

The left kidney is normal in size (4.25 cm) but irregular in shape with an abnormal caudal pole (likely due to previous infarct) and a 0.59 cm cystic structure. There is significant pyelectasia noted, and some small hyperechoic foci, consistent with non-obstructive mineralizations. Overall echogenicity is slightly hyperechoic with poor corticomedullary distinction and a typical 1:3 cortex:medulla ratio. There is no evidence of focal perinephric inflammation or effusion. There is no evidence of hydroureter. Renal vasculature is normal.

The right kidney has a normal shape and size (3.03 cm) with pyelectasia at 0.30 cm. Overall echogenicity is slightly hyperechoic with poor corticomedullary distinction and a typical 1:3 cortex:medulla ratio. There is no evidence of focal perinephric inflammation or effusion. There is no evidence of nephroliths, infarcts or hydroureter. Renal vasculature is normal. On some images, there is a hypoechoic ill-defined area near the cranial third of the kidney measuring 1.03 cm x 0.98 cm, possibly consistent with a nodule or imaging artifact.

**Adrenal Glands**

The left adrenal gland is normal in size measuring 0.31 cm at the caudal pole. It is observed in its normal position cranial to the left renal artery. It is normal in appearance (uniformly hypoechoic) and shape with no evidence of a mass effect.

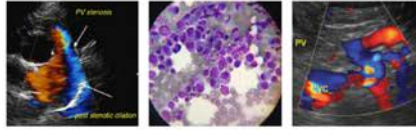
The right adrenal gland is normal in size measuring 0.37 cm at the caudal pole. It is observed in its normal position between the cranial aspect of the right kidney and the caudal vena cava. It is normal in appearance (uniformly hypoechoic) and shape with no evidence of a mass effect.

**Spleen**

The spleen is subjectively normal in size, echotexture is homogenous, and the splenic capsule is smooth with no irregularities. The blood flow through the hilus and splenic parenchyma appears normal. No focal parenchymal abnormalities are visualized.

**Liver**

The liver is subjectively normal in size, and echogenicity with smooth peripheral margins. The parenchyma is homogenous echotexture. The visible portions of the vasculature and biliary tract appear normal. No focal nodules or cystic lesions are observed.

**PATIENT**

Biscuit Morrow

The gallbladder lumen is moderately distended. The wall of the gall bladder is not thickened and has a smooth mucosal surface. Luminal contents are mild and primarily anechoic. The cystic and common bile ducts are normal/not visible.

**SPECIES**

Feline

***Gastrointestinal***

The stomach contains minimal luminal contents. It measures at a normal thickness of <0.36cm with some variability due to the presence of rugal folds. The distinction of the gastric wall layers is adequate and there is no impression of reduced peristaltic activity. No masses or focal lesions were observed.

**BREED**

DSH

The visualized areas of duodenum, jejunum and ileum have a relatively uniform diameter with minimal fluid distension. Wall thickness is normal. Bowel loops follow a curvilinear path with distinct wall layering maintaining the typical 1:3 muscularis:mucosa layer ratio. Jejunum wall measures 0.24 cm. Duodenum wall measures 0.31 cm. Visualized peristalsis appears appropriate. There were no focal lesions consistent with obstruction or a mass effect observed.

**SEX**

Neuterd Male

The ileocecal junction was visualized and exhibited normal intact wall layering and is subjectively of normal thickness. Sections of colon are visualized with formed fecal material and gas shadowing distally. There is no observed focal or generalized colon wall thickening or loss of layering. Colon wall measures 0.13 cm.

**AGE**

6 Years

***Pancreas***

The pancreas is normal and isoechoic to surrounding mesentery. There is no evidence of nodules or cystic lesions. There is no evidence of regional mesenteric inflammation or fluid.

**WEIGHT**

12 Pounds

***Free Abdomen***

Evaluation of the peritoneal cavity did not reveal any evidence of effusion, or subjective lymphadenomegaly. The Medial iliac nodes appear normal and there was no evidence of a caudal aortic thrombus at the bifurcation. The omentum is of normal uniform echogenicity.

**INTERPRETED BY**

Kathleen Sennello DVM,  
MS, Diplomate ACVIM  
(Small Animal Internal  
Medicine)

**ULTRASONOGRAPHIC FINDINGS**

- Decreased corticomedullary distinction in both kidneys with bilateral pyelectasia, a left renal cyst, and previous infarct – Mild loss of corticomedullary distinction in both kidneys could be consistent with chronic degenerative disease or interstitial nephrosis. The solitary renal lesion identified is ill defined and hyperechoic, this could be consistent with a previous renal infarct and can be an indicator of current or previous renal disease. Pyelectasia of the kidney(s) could be consistent with pyelonephritis, chronic renal disease, secondary to PU/PD or fluid therapy (if applicable), other.
- Questionable focal hypoechoic region in the right kidney – This could be consistent with artifact or nodule. This lesion is not visible in all planes, and primary differential is imaging artifact (shadow).

**IMAGING PERFORMED BY**

Amy Mayhew, LVT

**HOSPITAL NAME**

SVS Imaging MI

**REFERRING VET**

Cat Care of Rochester  
Hills – Dr. Hunt

**INTERPRETATION OF THE FINDINGS & FURTHER RECOMMENDATIONS**

Both kidneys are very abnormal in appearance with a reduced corticomedullary distinction and pyelectasia. It is curious that the USG still shows some level of concentration, which could indicate that there is a complicating factor such as pyelonephritis, a renal obstruction, etc. No obstruction is clearly seen, but small mineralizations are visualized in the left kidney.

**INVOICE**

43992

**DATE**

1/5/23

Recommend a urinalysis, culture, and blood pressure evaluation. Additionally, consider continued monitoring of the renal pelvises for continued dilation. If this occurs, then consider either a contrast CT scan or an intravenous pyelogram to look for a more distal obstruction, stricture, etc. At that time, the right kidney can be reevaluated, looking for a possible nodule.

**IMAGING PERFORMED BY**

SVS Mobile Imaging MI 734-637-7711  
svsimagingmi@gmail.com



**PATIENT**

Biscuit Morrow

**SPECIES**

Feline

**BREED**

DSH

**SEX**

Neuterd Male

**AGE**

6 Years

**WEIGHT**

12 Pounds

**INTERPRETED BY**

Kathleen Sennello DVM,  
MS, Diplomate ACVIM  
(Small Animal Internal  
Medicine)

**IMAGING PERFORMED BY**

Amy Mayhew, LVT

**HOSPITAL NAME**

SVS Imaging MI

**REFERRING VET**

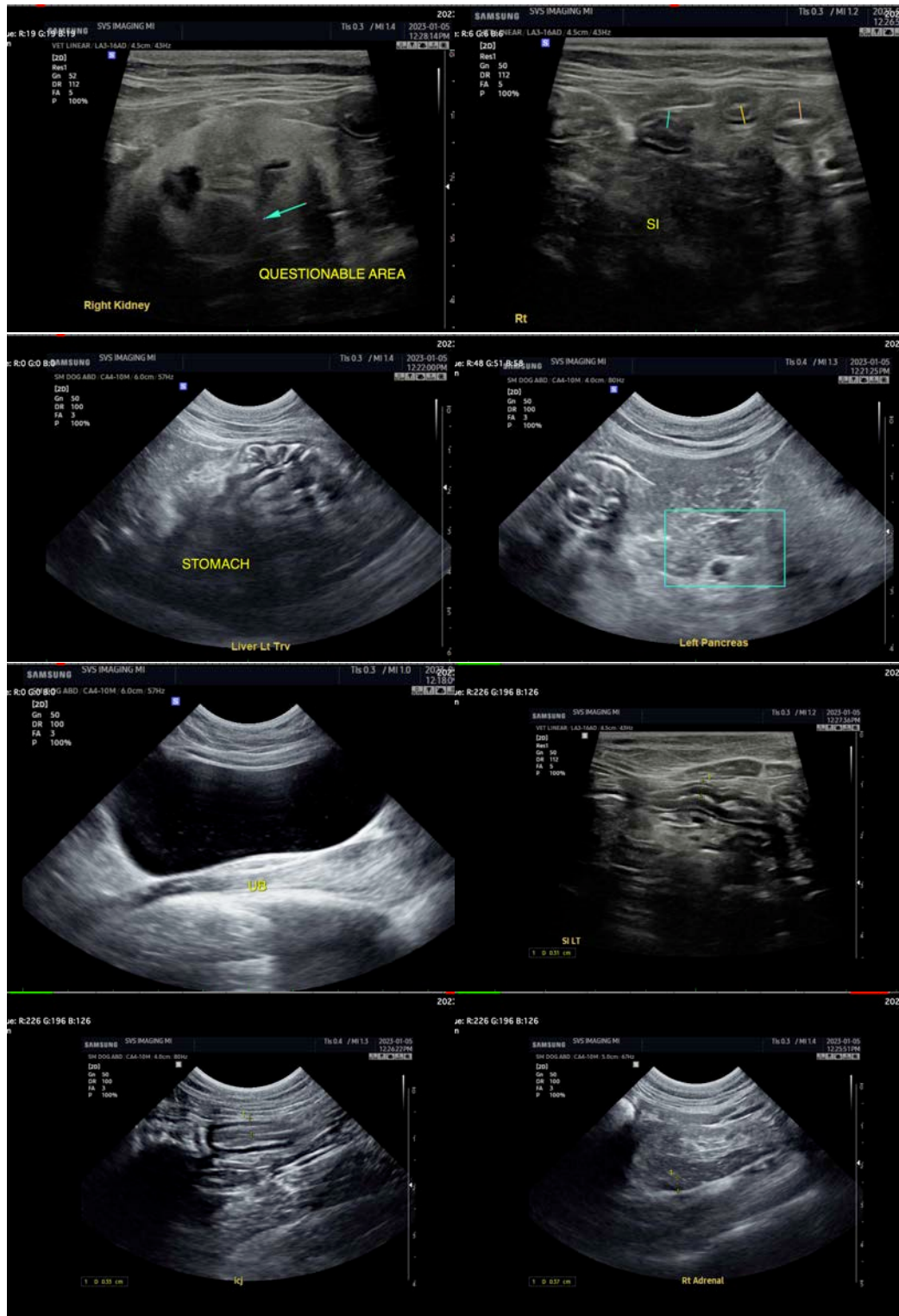
Cat Care of Rochester  
Hills - Dr. Hunt

**INVOICE**

43992

**DATE**

1/5/23



**IMAGING PERFORMED BY**

SVS Mobile Imaging MI 734-637-7711  
svsimagingmi@gmail.com



EDUCATIONAL TELECONSULTATION SERVICES™  
1-800-838-4268 info@sonopath.com SonoPath.com

**PATIENT**

Biscuit Morrow

**SPECIES**

Feline

**BREED**

DSH

**SEX**

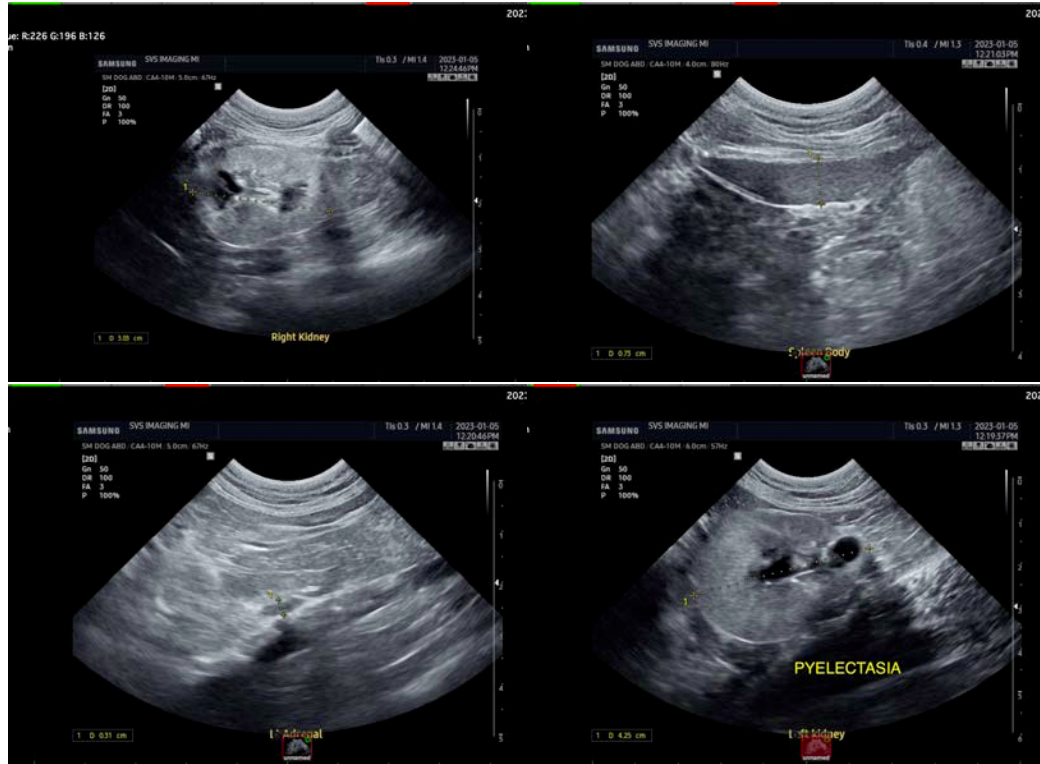
Neuterd Male

**AGE**

6 Years

**WEIGHT**

12 Pounds



**INTERPRETED BY**

Kathleen Sennello DVM,  
MS, Diplomate ACVIM  
(Small Animal Internal  
Medicine)

The information and recommendations provided are based on the images presented by the referring veterinarian/sonographer. No evaluation can be communicated regarding pathology that was not visible in the image/video clips provided.

Thank you for this referral. If the clinical or image interpretation does not parallel your findings or if I can be of any further assistance please contact me.

Kathleen Sennello DVM,MS, Diplomate ACVIM (Small animal Internal Medicine)

kathleen.sennello@sonopath.com

**IMAGING PERFORMED BY**

Amy Mayhew, LVT

**HOSPITAL NAME**

SVS Imaging MI

**REFERRING VET**

Cat Care of Rochester  
Hills - Dr. Hunt

**INVOICE**

43992

**DATE**

1/5/23