

IMAGING PERFORMED BY

IntraPet.com



SonoPath

Clinical Sonography & Telecytology

EDUCATIONAL TELECONSULTATION SERVICES™

1-800-838-4268 info@sonopath.com SonoPath.com

DATE PRESENTING CLINICAL SIGNS

1/5/22

History: 12/13/21: Presented to previous vet for increased urinary incontinence. UTI suspected on UA. P started on antibiotics.

PATIENT

12/22/21: No improvement with incontinence. P started on Proin.

Samantha Spalluzi

12/28/21: O notes PU/PD at home. Still having urinary accidents when sleeping, but less. Will not eat dog food, only human food and treats. UA (free catch): USG 1.010, inactive sediment. 1/4/22: Presented to Timonium AH. 1 day of vomiting and inappetence and lethargy. PU/PD and urinary incontinence.

SPECIES

Current Medications: Cerenia 40mg SID since 1/4/21.

Canine

Lab Results: 12/30/21: HCT 45.5% WBC 6.6, Neutrophils 3927, SDMA 26, Creat 1.7, BUN 30, ALKP 384, Cortisol: Creat 23

BREED

Radiographs: Brief ultrasound showed hypoechoic liver with mass effect in right liver lobe. 1/4/21:

Shepherd X

Radiograph: Thoracic: VHS=10, trachea wnl; lung wnl. Abdomen: liver appears small; stomach empty; intestines wnl; possible radiopacity in left kidney; remaining abdomen wnl.

SEX

Date of Previous IntraPet Ultrasound: No previous IntraPet scans.

Spayed Female

Sedation: Not required to complete full diagnostic ultrasound.

Stat Report: Not requested.

Imaging Performed By: Andi Parkinson, RDMS.

AGE

ULTRASONOGRAPHIC EXAMINATION OF THE ABDOMEN

1/3/07

Urinary System

The urinary bladder is moderately distended with anechoic urine. The Bladder wall, trigone, ureteral papillae and visible urethra (to a depth of 2cm) appear normal with no evidence of wall thickening, mucosal irregularities, masses or cystic calculi.

WEIGHT

47 Pounds

The left kidney has a normal shape and size (6.26 cm) with non-obstructive nephroliths. Overall echogenicity is normal with adequate corticomedullary distinction and a typical 1:3 cortex:medulla ratio. There is no evidence of perinephric inflammation or effusion. There is no evidence of pyelectasia, nephroliths, infarcts or hydroureter. Renal vasculature is normal.

INTERPRETED BY

Kathleen Sennello DVM, MS, Diplomate ACVIM (Small Animal Internal Medicine)

The right kidney has a normal shape and size (6.31 cm) with small non-obstructive nephroliths. Overall echogenicity is normal with adequate corticomedullary distinction and a typical 1:3 cortex:medulla ratio. There is no evidence of perinephric inflammation or effusion. There is no evidence of pyelectasia, infarcts or hydroureter. Renal vasculature is normal.

IMAGING PERFORMED BY

Andi Parkinson RDMS

Adrenal Glands

HOSPITAL NAME

Timonium AH

The left adrenal gland is normal in size measuring 0.70 cm at the caudal pole. It is observed in its normal position cranial to the left renal artery. It is normal in appearance (uniformly hypoechoic) and shape with no evidence of a mass effect.

REFERRING VET

Dr. Falkowski

The right adrenal gland is normal in size measuring 0.61 cm at the caudal pole. It is observed in its normal position between the cranial aspect of the right kidney and the caudal vena cava. It is normal in appearance (uniformly hypoechoic) and shape with no evidence of a mass effect.

INVOICE

34007

Spleen

The spleen is subjectively normal in size, echotexture is homogenous, and the splenic capsule is smooth with no irregularities. The blood flow through the hilus and splenic parenchyma appears normal. No focal parenchymal abnormalities are visualized.

Liver

The liver is large in size, and normal in echogenicity with smooth peripheral margins. The parenchyma is heterogenous in echotexture with subtle, indistinct focal mottling. The visible portions of the vasculature and biliary tract appear normal. There is a large solid, slightly mixed echogenic mass effect on the right side of the liver measuring 10.38 cm x 7.24 cm.

The gallbladder lumen is moderately distended. The wall of the gall bladder is not thickened and has a smooth mucosal surface. Luminal contents are primarily anechoic. The cystic and common bile ducts are normal/not visible.

Gastrointestinal

The stomach contains minimal luminal contents. It measures at a normal thickness of <0.7cm with some variability due to the presence of rugal folds. The distinction of the gastric wall layers is adequate and there is no impression of reduced peristaltic activity. No masses or focal lesions were observed.

The visualized areas of duodenum, jejunum and ileum have a relatively uniform diameter with minimal fluid distension. Wall thickness is normal. Bowel loops follow a curvilinear path with distinct wall layering maintaining the typical 1:3 muscularis:mucosa layer ratio. The duodenum measured as normal (between 0.3-0.5cm in wall thickness) and the jejunum measured as normal (between 0.2-0.47cm.) Visualized peristalsis appears appropriate. There were no focal lesions consistent with obstruction or a mass effect observed.

The ileocecal junction was visualized and exhibited normal intact wall layering and is subjectively of normal thickness. Sections of colon are visualized with formed fecal material and gas shadowing distally. There is no observed focal or generalized colon wall thickening or loss of layering.

Pancreas

The pancreas is normal and isoechoic to surrounding mesentery. There is no evidence of nodules or cystic lesions. There is no evidence of regional mesenteric inflammation or fluid.

Free Abdomen

Evaluation of the peritoneal cavity did not reveal any evidence of effusion, or subjective lymphadenomegaly. The Medial iliac nodes appear normal and there was no evidence of a caudal aortic thrombus at the bifurcation. The omentum is of increased echogenicity around the hepatic mass.

PRIMARY FINDINGS

- Heterogeneous liver with large right-sided mass effect – The diffuse hepatic changes are non-specific and could be consistent with vacuolar hepatopathy, nodular hyperplasia, inflammatory/immune-mediated disease, fibrosis, extramedullary hematopoiesis, toxic hepatopathy (e.g., copper), infiltrative neoplasia (less likely) or other hepatopathy. The appearance of this mass favors a primary hepatic mass. This could be benign or malignant.

SECONDARY FINDINGS

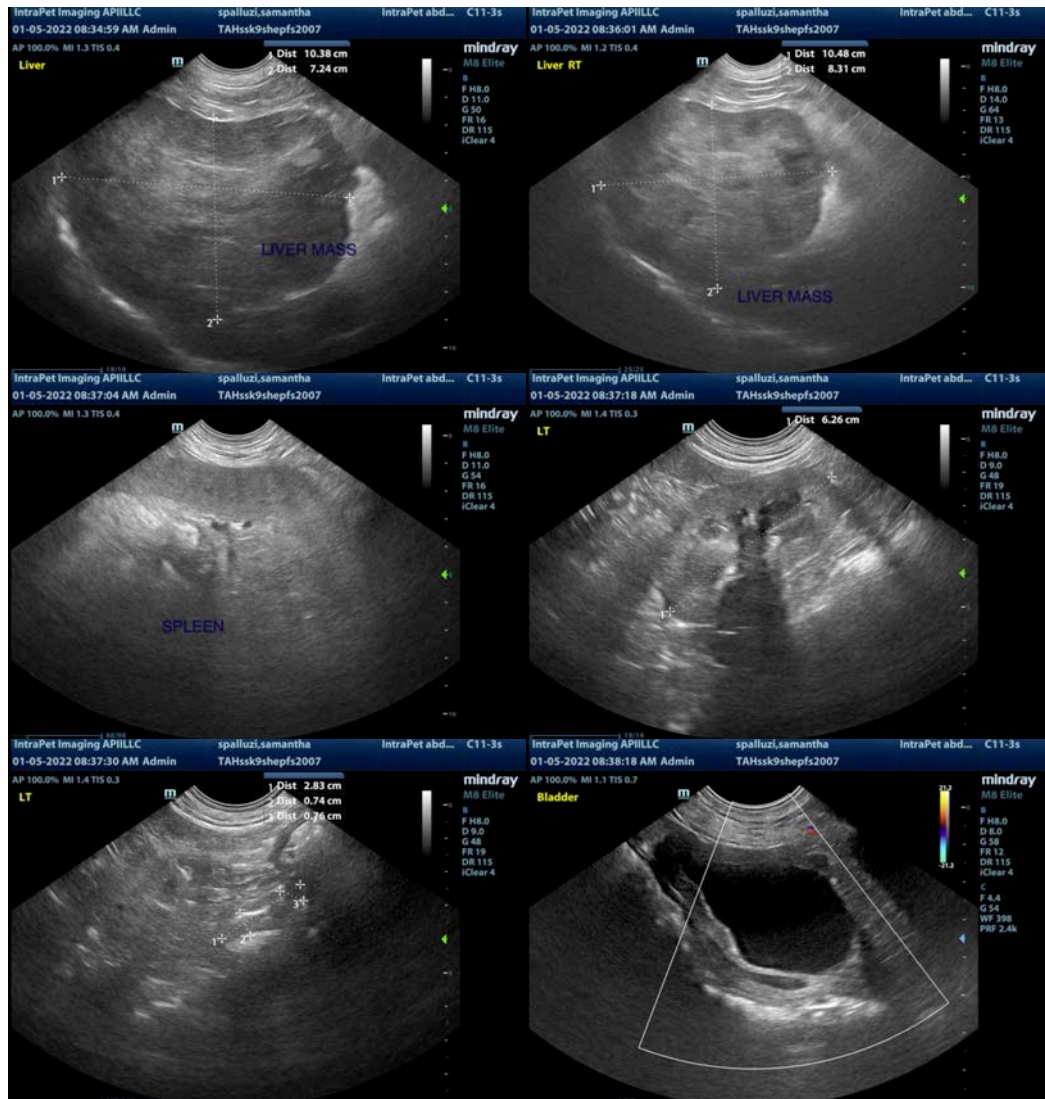
- Small, non-obstructive nephroliths visualized in both kidneys – The hyperechoic mineralized foci observed at the corticomedullary junction of the left/right kidney are consistent with small, non-obstructive nephroliths.

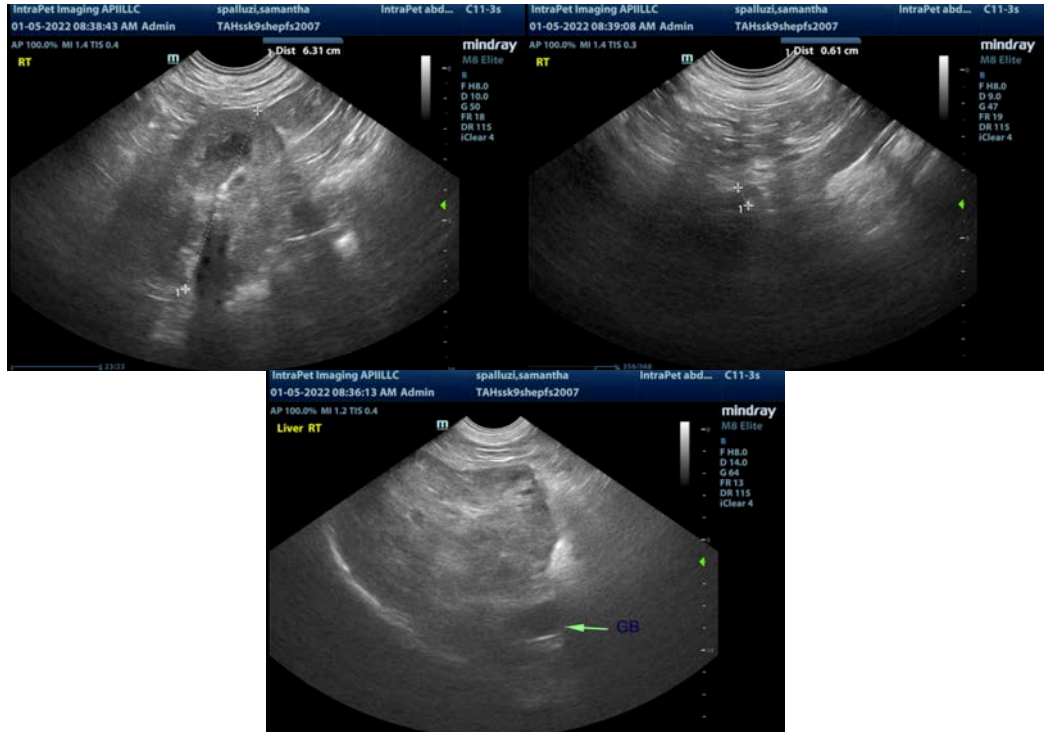
INTERPRETATION OF THE FINDINGS & FURTHER RECOMMENDATIONS

A large liver mass is visualized on today's exam. Based on the appearance and size of this mass, I suspect it is a primary liver mass. These can have a relatively favorable prognosis if they can be surgically resected.

- Recommend 3-view thoracic radiographs.
- Consider a contrast CT scan to further evaluate the scope of this mass effect for surgical planning and to look for evidence of metastasis.

While this mass could very well be the source of the PU/PD described, it could also be early renal insufficiency causing an increase.





The information and recommendations provided are based on the images presented by the referring veterinarian. No evaluation can be communicated regarding pathology that was not visible in the image/video clips provided.

Thank you for this referral. If the clinical or image interpretation does not parallel your findings or if I can be of any further assistance please contact me.

Kathleen Sennello DVM,MS, Diplomate ACVIM (Small animal Internal Medicine)
kathleen.sennello@sonopath.com