

**PATIENT**

Carmel Brutz

SPECIES

Canine

BREED

Shih Tzu

SEX

Neutered Male

AGE

13 Years

WEIGHT

17 Pounds

INTERPRETED BYKathleen Sennello DVM,
MS, Diplomate ACVIM
(Small Animal Internal
Medicine)**IMAGING
PERFORMED BY**

Amy Mayhew, LVT

HOSPITAL NAME

SVS Imaging Michigan

REFERRING VET

Wixom Family PC

INVOICE

33987

DATE

1/5/22

PRESENTING CLINICAL SIGNS

Recent elevation ALKP 187, was normal last year. No clinical signs. History of dry eye, on Cyclosporine drops. Patient was started on Denamarin, but owner reported constipation so she stopped supplement after 3 days. Patient needs a dental. Echo pending for anesthesia recommendations.

ULTRASONOGRAPHIC EXAMINATION OF THE ABDOMEN**Urinary System**

The urinary bladder is minimally distended with anechoic urine. The Bladder wall is diffusely mildly thickened and irregular, measuring 0.41 cm. The area of the trigone, ureteral papillae and visible urethra (to a depth of 2cm) appear free of calculi and mass effects. Findings are most consistent with diffuse cystitis and lack of urine distention, but underlying neoplasia cannot be excluded as a possibility.

The prostate is normal in size (1.2 cm) and shape for this neutered male dog. The parenchyma is homogenous and the external margins are smooth. The prostatic urethra appears normal with no evidence of irregularity, invasion, mass effect or calculi.

The left kidney has a normal shape and size (4.34 cm). Overall echogenicity is normal with adequate corticomedullary distinction and a typical 1:3 cortex:medulla ratio. There is no evidence of perinephric inflammation or effusion. There is no evidence of pyelectasia, nephroliths, infarcts or hydroureter. Renal vasculature is normal.

The right kidney has a normal shape and size (4.4 cm). Overall echogenicity is normal with adequate corticomedullary distinction and a typical 1:3 cortex:medulla ratio. There is no evidence of perinephric inflammation or effusion. There is no evidence of pyelectasia, nephroliths, infarcts or hydroureter. Renal vasculature is normal.

Adrenal Glands

The left adrenal gland is normal in size measuring 0.55 cm at the caudal pole. It is observed in its normal position cranial to the left renal artery. It is normal in appearance (uniformly hypoechoic) and shape with no evidence of a mass effect.

The right adrenal gland is normal in size measuring 0.43 cm at the caudal pole. It is observed in its normal position between the cranial aspect of the right kidney and the caudal vena cava. It is normal in appearance (uniformly hypoechoic) and shape with no evidence of a mass effect.

Spleen

The spleen is subjectively normal in size, echotexture is homogenous, and the splenic capsule is smooth with no irregularities. The blood flow through the hilus and splenic parenchyma appears normal. No focal parenchymal abnormalities are visualized.

Liver

The liver is subjectively normal in size, and echogenicity with smooth peripheral margins. The parenchyma is mildly heterogenous in echotexture with subtle, indistinct focal mottling. The visible portions of the vasculature and biliary tract appear normal. No focal nodules or cystic lesions are observed.

The gall bladder lumen is moderately distended. The wall of the gall bladder is not thickened and has a smooth mucosal surface. There is a moderate amount of non-organized echogenic debris. The cystic and common bile ducts are normal/not visible.

IMAGING PERFORMED BY

SVS Mobile Imaging MI 734-637-7711
svsimagingmi@gmail.com



EDUCATIONAL TELECONSULTATION SERVICES™
1-800-838-4268 info@sonopath.com SonoPath.com

PATIENT

Carmel Brutz

SPECIES

Canine

BREED

Shih Tzu

SEX

Neutered Male

AGE

13 Years

WEIGHT

17 Pounds

INTERPRETED BY

Kathleen Sennello DVM,
MS, Diplomate ACVIM
(Small Animal Internal
Medicine)

IMAGING PERFORMED BY

Amy Mayhew, LVT

HOSPITAL NAME

SVS Imaging Michigan

REFERRING VET

Wixom Family PC

INVOICE

33987

DATE

1/5/22

Gastrointestinal

The stomach contains minimal luminal contents. It measures at a normal thickness of <0.7cm with some variability due to the presence of rugal folds. The distinction of the gastric wall layers is adequate and there is no impression of reduced peristaltic activity. No masses or focal lesions were observed.

The visualized areas of duodenum, jejunum and ileum have a relatively uniform diameter with minimal fluid distension. Wall thickness is normal. Bowel loops follow a curvilinear path with distinct wall layering maintaining the typical 1:3 muscularis:mucosa layer ratio. Duodenum wall measured 0.53 cm. Jejunum wall measured 0.36 cm. Visualized peristalsis appears appropriate. There were no focal lesions consistent with obstruction or a mass effect observed.

The ileocecal junction was visualized and exhibited normal intact wall layering and is subjectively of normal thickness. Sections of colon are visualized with formed fecal material and gas shadowing distally. There is no observed focal or generalized colon wall thickening or loss of layering.

Pancreas

The pancreas is normal and isoechoic to surrounding mesentery. There is no evidence of nodules or cystic lesions. There is no evidence of regional mesenteric inflammation or fluid.

Free Abdomen

Evaluation of the peritoneal cavity did not reveal any evidence of effusion, or subjective lymphadenomegaly. The Medial iliac nodes appear normal and there was no evidence of a caudal aortic thrombus at the bifurcation. The omentum is of normal uniform echogenicity.

ULTRASONOGRAPHIC FINDINGS

- Mildly heterogeneous liver – The diffuse hepatic changes are non-specific and could be consistent with vacuolar hepatopathy, nodular hyperplasia, inflammatory/immune-mediated disease, fibrosis, extramedullary hematopoiesis, toxic hepatopathy (e.g., copper), infiltrative neoplasia (less likely) or other hepatopathy.
- Mild gallbladder sludge – The significance of the aggregated gallbladder sludge is unclear. This could represent an early mucocele, cholestasis, or may be secondary to fasting.
- Irregular thickened bladder mucosa – The bladder mucosal changes could be consistent with cystitis or artifactual due to lack of adequate luminal distension. Bladder neoplasia cannot be ruled out but is considered unlikely in this patient.

INTERPRETATION OF THE FINDINGS & FURTHER RECOMMENDATIONS

There were no focal lesions associated with the liver, and the gallbladder changes were very mild. Options moving forward include Denamarin or Denamarin like product if this dog did not tolerate it well, and continued monitoring. If you would like to be more proactive, you could consider a liver function test, as I would expect it to be normal. If liver values continue to rise, then reevaluation of the gallbladder and liver would be warranted. Also continued to monitor for signs of Cushing's disease.

The urinary bladder was minimally distended and appeared to be somewhat irregular. Recommend urinalysis and culture to look for signs of bacterial cystitis. If there is no infection present, recommend reevaluation of the bladder with more urine distention.

IMAGING PERFORMED BY

SVS Mobile Imaging MI 734-637-7711
svsimagingmi@gmail.com



PATIENT

Carmel Brutz

SPECIES

Canine

BREED

Shih Tzu

SEX

Neutered Male

AGE

13 Years

WEIGHT

17 Pounds

INTERPRETED BY

Kathleen Sennello DVM,
MS, Diplomate ACVIM
(Small Animal Internal
Medicine)

**IMAGING
PERFORMED BY**

Amy Mayhew, LVT

HOSPITAL NAME

SVS Imaging Michigan

REFERRING VET

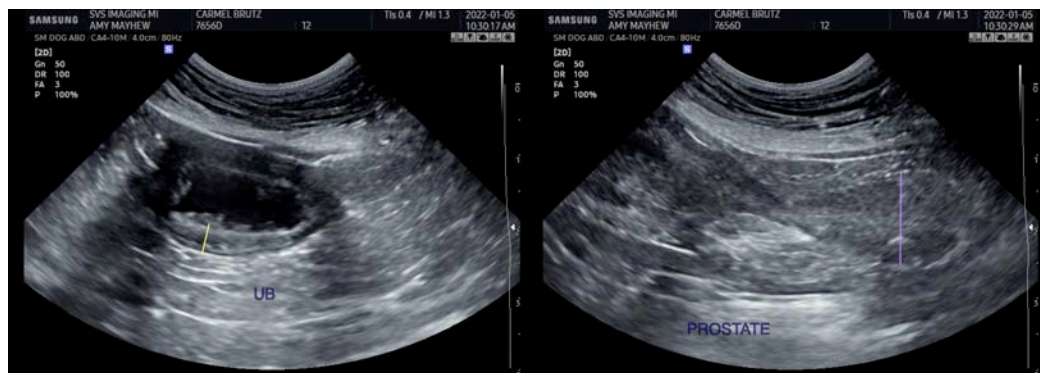
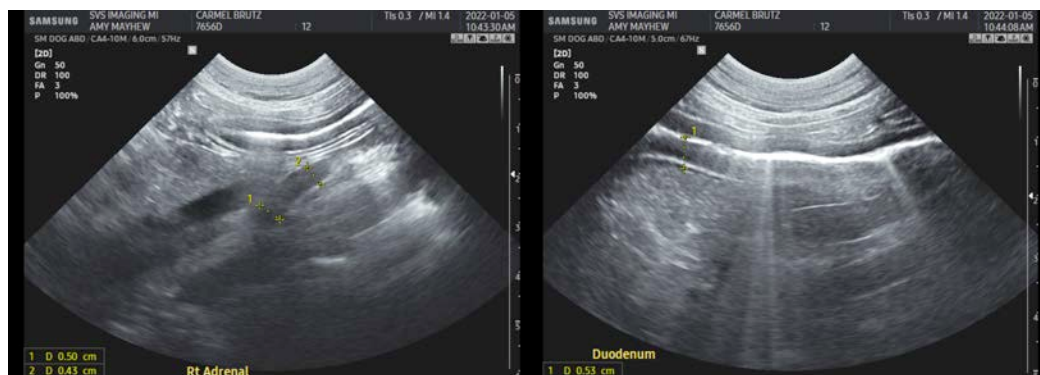
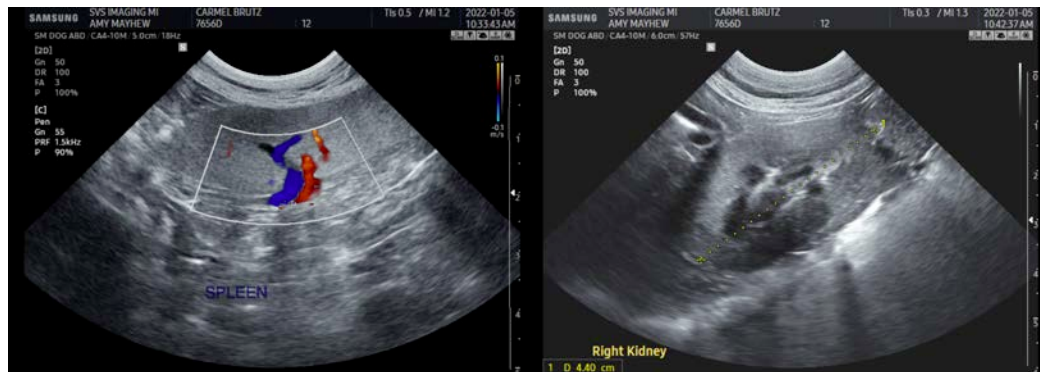
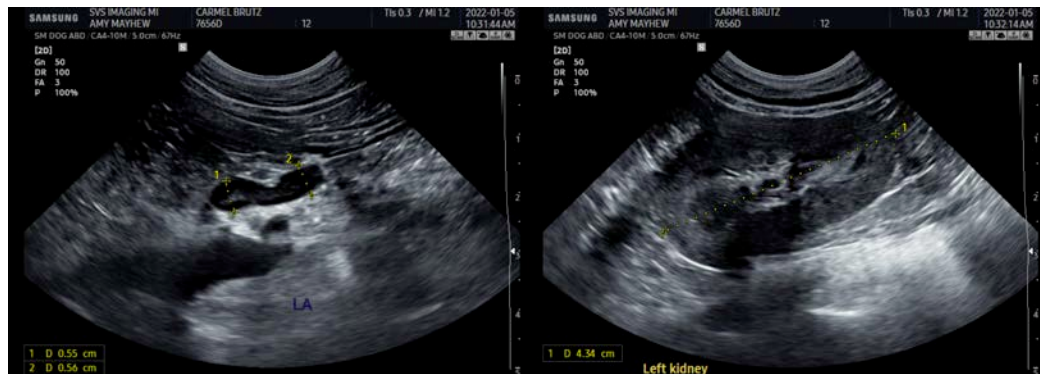
Wixom Family PC

INVOICE

33987

DATE

1/5/22



IMAGING PERFORMED BY

SVS Mobile Imaging MI 734-637-7711
svsimagingmi@gmail.com



EDUCATIONAL TELECONSULTATION SERVICES™
1-800-838-4268 info@sonopath.com SonoPath.com

PATIENT

Carmel Brutz

SPECIES

Canine

BREED

Shih Tzu

SEX

Neutered Male

AGE

13 Years

WEIGHT

17 Pounds

INTERPRETED BY

Kathleen Sennello DVM,
MS, Diplomate ACVIM
(Small Animal Internal
Medicine)

**IMAGING
PERFORMED BY**

Amy Mayhew, LVT

HOSPITAL NAME

SVS Imaging Michigan

REFERRING VET

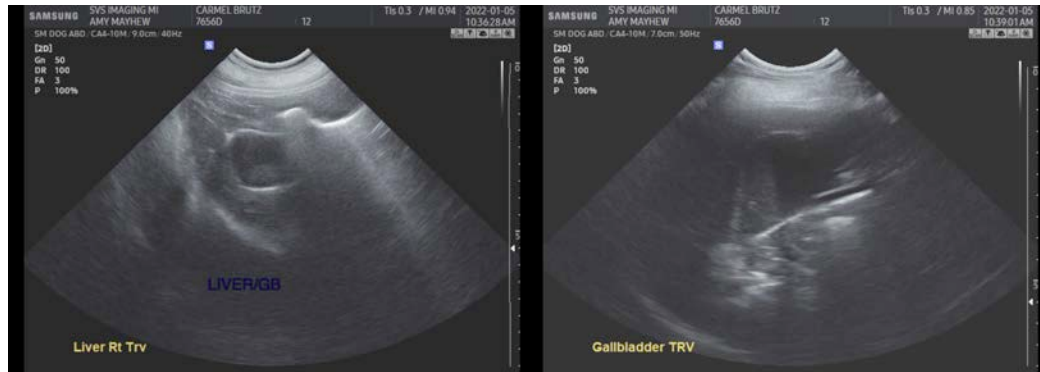Wixom Family PC

INVOICE

33987

DATE

1/5/22



The information and recommendations provided are based on the images presented by the referring veterinarian. No evaluation can be communicated regarding pathology that was not visible in the image/video clips provided.

Thank you for this referral. If the clinical or image interpretation does not parallel your findings or if I can be of any further assistance please contact me.

Kathleen Sennello DVM,MS, Diplomate ACVIM (Small animal Internal Medicine)

kathleen.sennello@sonopath.com