

**PATIENT**

Luna Elliott 47253A

SPECIES

Canine

BREED

Labrador Retriever

SEX

Spayed Female

AGE

10 Years

WEIGHT

33.7 kg

INTERPRETED BYKathleen Sennello DVM,
MS, Diplomate ACVIM
(Small Animal Internal
Medicine)**IMAGING
PERFORMED BY**

Tom McNeill

HOSPITAL NAME

SVS Imaging CT

REFERRING VETMadison VS – Dr.
Graham**INVOICE**

43945

DATE

1/4/23

PRESENTING CLINICAL SIGNS

Luna presented to the MVS Emergency Service on Dec 13, 2021, at 11am, for evaluation of ADR. Last week Monday, Luna was coughing so Michael took her to her pcDVM. They prescribed cough tablets and Luna's cough got better. Yesterday, Luna was acting off and lethargic; her eyes were glassy and she seemed nauseous (pacing a lot, not being able to get comfortable). She did not come begging for food like she normally does, so Michael added ground turkey and water to her food and then she ate well. She is maybe drinking less than normal but urinating the same amount. Luna has a history of reaction to NSAID's; she was put on an NSAID for knee issues and her liver enzymes became very elevated. She was hospitalized at VCA and recovered well after a couple of days.

Abnormal PE/Chem/CBC/UA Results: AFAST- abdominal effusion. Abdominocentesis confirmed hemoabdomen.

ULTRASONOGRAPHIC EXAMINATION OF THE ABDOMEN**Urinary System**

The urinary bladder is moderately distended with anechoic urine. The Bladder wall is diffusely mildly thickened (0.34 cm), and the mucosa is mildly irregular. The trigone, ureteral papillae, and visible urethra (to a depth of 2cm) appear normal with no evidence of severe mucosal irregularities, masses or cystic calculi. Findings are most consistent with bacterial cystitis or lack of urine distension. Recommend urinalysis and culture.

The left kidney has a normal shape and size (6.09 cm). Overall echogenicity is normal with adequate corticomedullary distinction and a typical 1:3 cortex:medulla ratio. There is no evidence of focal perinephric inflammation or effusion. There is no evidence of pyelectasia, nephroliths, infarcts or hydroureter. Renal vasculature is normal.

The right kidney has a normal shape and size (7.07 cm). Overall echogenicity is normal with adequate corticomedullary distinction and a typical 1:3 cortex:medulla ratio. There is no evidence of focal perinephric inflammation or effusion. There is no evidence of pyelectasia, nephroliths, infarcts or hydroureter. Renal vasculature is normal.

Adrenal Glands

The left adrenal gland is normal in size measuring 0.72 cm at the caudal pole. It is observed in its normal position cranial to the left renal artery. It is normal in appearance (uniformly hypoechoic) and shape with no evidence of a mass effect.

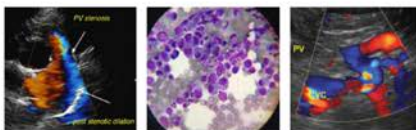
The right adrenal gland is normal in size measuring 0.47 cm at the caudal pole. It is observed in its normal position between the cranial aspect of the right kidney and the caudal vena cava. It is normal in appearance (uniformly hypoechoic) and shape with no evidence of a mass effect.

Spleen

The spleen is large and irregular. The spleen echotexture is heterogenous and mottled. The blood flow through the hilus and splenic parenchyma appears normal. There is a large mixed echogenic, somewhat pedunculated mass effect visualized near the head of the spleen measuring >6.35 cm x 6.0 cm.

Liver

The liver is subjectively normal in size, and echogenicity with smooth peripheral margins. The parenchyma is heterogenous in echotexture with subtle, indistinct focal mottling. The visible portions of the vasculature and biliary tract appear normal. There are numerous variably echogenic nodules visualized in the liver. There is a larger hyperechoic nodule on the left side measuring 2.53 cm x 2.32 cm,

**PATIENT**

Luna Elliott 47253A

SPECIES

Canine

BREED

Labrador Retriever

SEX

Spayed Female

AGE

10 Years

WEIGHT

33.7 kg

INTERPRETED BYKathleen Sennello DVM,
MS, Diplomate ACVIM
(Small Animal Internal
Medicine)**IMAGING
PERFORMED BY**

Tom McNeill

HOSPITAL NAME

SVS Imaging CT

REFERRING VETMadison VS - Dr.
Graham**INVOICE**

43945

DATE

1/4/23

a small hypoechoic lesion measuring 0.73 cm on the left, and an isoechoic nodule measuring 1.48 cm x 1.56 cm.

The gallbladder lumen is moderately distended. The wall of the gall bladder is not thickened and has a smooth mucosal surface. Luminal contents are mild and primarily anechoic. The cystic and common bile ducts are normal/not visible.

Gastrointestinal

The stomach contains minimal luminal contents. It measures at a normal thickness of 0.29 cm with some variability due to the presence of rugal folds. The distinction of the gastric wall layers is adequate and there is no impression of reduced peristaltic activity. No masses or focal lesions were observed.

The visualized areas of duodenum, jejunum and ileum have a relatively uniform diameter with minimal fluid distension. Wall thickness is normal. Bowel loops follow a curvilinear path with distinct wall layering maintaining the typical 1:3 muscularis:mucosa layer ratio. Jejunum wall measures 0.34 cm. Duodenum wall measures 0.38 cm. Visualized peristalsis appears appropriate. There were no focal lesions consistent with obstruction or a mass effect observed.

The ileocecal junction was visualized and exhibited normal intact wall layering and is subjectively of normal thickness. Sections of colon are visualized with formed fecal material and gas shadowing distally. There is no observed focal or generalized colon wall thickening or loss of layering. Colon wall measures 0.15 cm.

Pancreas

The pancreas is normal and isoechoic to surrounding mesentery. There is no evidence of nodules or cystic lesions. There is no evidence of regional mesenteric inflammation or fluid.

Free Abdomen

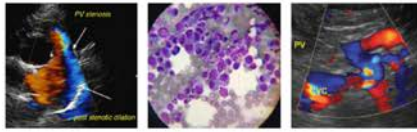
There is a large amount of echogenic free fluid. No lymphadenopathy. The omentum is of increased echogenicity.

ULTRASONOGRAPHIC FINDINGS

- Large, mixed echogenic splenic mass – A focal solid mixed echogenicity mass is visualized associate with the spleen. This mass distorts the splenic capsule. Differentials include : benign lesions (lymphoid hyperplasia, hemangioma etc..) or cancerous lesions (hemangiosarcoma, lymphoma, histocytic sarcoma etc..)
- Subjectively mildly thickened and irregular urinary bladder wall – The bladder mucosal changes could be consistent with cystitis or artifactual due to lack of adequate luminal distension. Bladder neoplasia cannot be ruled out but is considered unlikely in this patient.
- Heterogeneous liver with variably echogenic nodules – The diffuse hepatic changes are non-specific and could be consistent with vacuolar hepatopathy, nodular hyperplasia, inflammatory/immune-mediated disease, fibrosis, extramedullary hematopoiesis, toxic hepatopathy (e.g., copper), infiltrative neoplasia (less likely) or other hepatopathy. Most of these lesions have a somewhat benign appearance, but given the splenic lesion, metastasis cannot be excluded as a possibility.
- Large volume echogenic abdominal fluid – Sampling post-ultrasound revealed a hemoabdomen.

IMAGING PERFORMED BY

SVS Mobile Imaging CT 262-366-5970
fredgromalak@gmail.com



Clinical Sonography & Telecytology

EDUCATIONAL TELECONSULTATION SERVICES™

1-800-838-4268 info@sonopath.com SonoPath.com

PATIENT

Luna Elliott 47253A

SPECIES

Canine

BREED

Labrador Retriever

SEX

Spayed Female

AGE

10 Years

WEIGHT

33.7 kg

INTERPRETED BY

Kathleen Sennello DVM,
MS, Diplomate ACVIM
(Small Animal Internal
Medicine)

IMAGING PERFORMED BY

Tom McNeill

HOSPITAL NAME

SVS Imaging CT

REFERRING VET

Madison VS - Dr.
Graham

INVOICE

43945

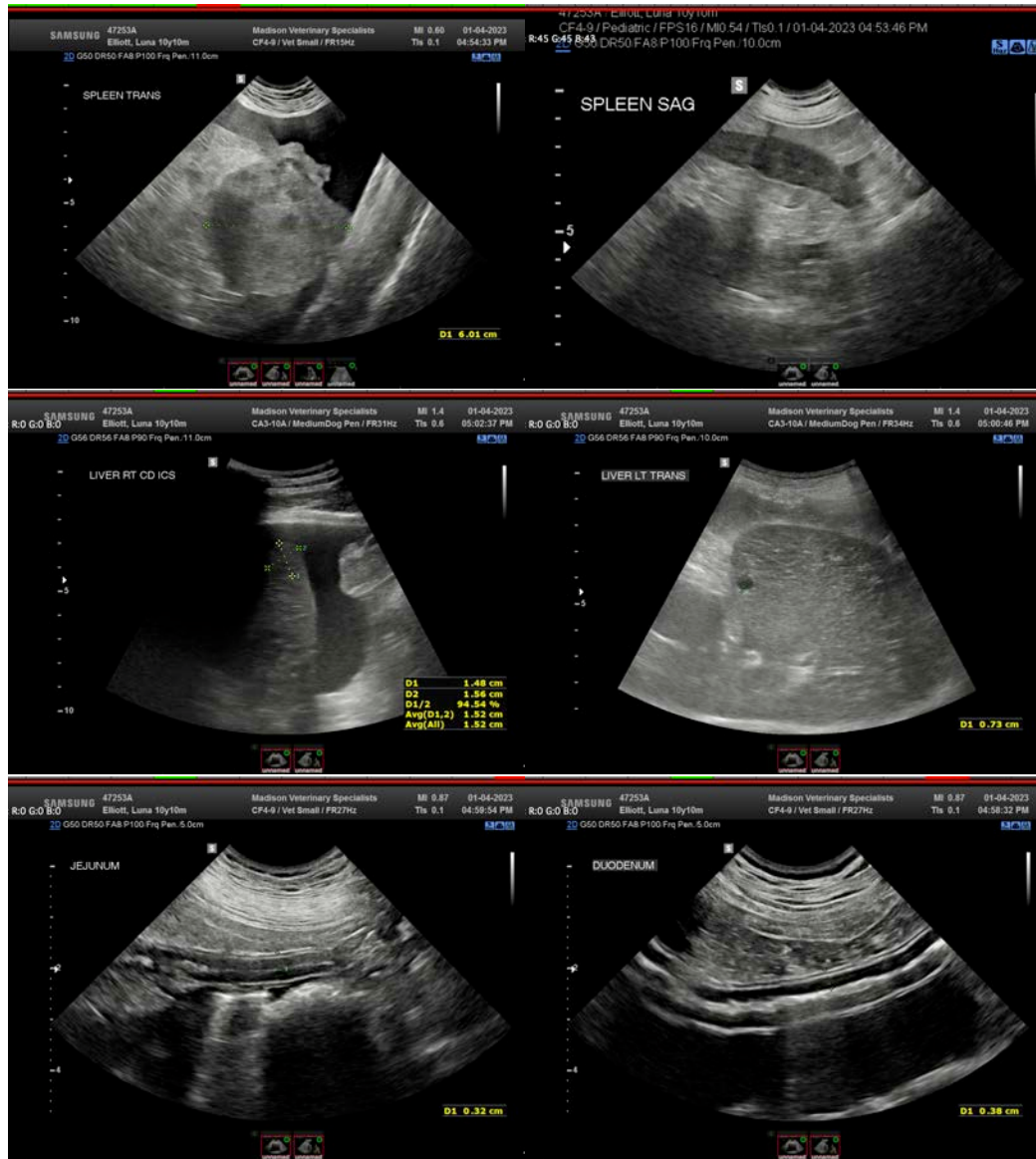
DATE

1/4/23

INTERPRETATION OF THE FINDINGS & FURTHER RECOMMENDATIONS

There is a large mixed echogenic splenic mass in addition to a hemoabdomen. Consider splenectomy for both diagnostic and therapeutic purposes. There is no overt evidence of metastasis, but there are nodules visualized in the liver. These could be sampled at the time of surgery. Additionally, recommend 3-view thoracic radiographs.

The bladder wall appears slightly thickened and irregular. This could be due to lack of full urine distention. Consider urinalysis and culture.



IMAGING PERFORMED BY

SVS Mobile Imaging CT 262-366-5970
fredgromalak@gmail.com



PATIENT

Luna Elliott 47253A

SPECIES

Canine

BREED

Labrador Retriever

SEX

Spayed Female

AGE

10 Years

WEIGHT

33.7 kg

INTERPRETED BY

Kathleen Sennello DVM,
MS, Diplomate ACVIM
(Small Animal Internal
Medicine)

**IMAGING
PERFORMED BY**

Tom McNeill

HOSPITAL NAME

SVS Imaging CT

REFERRING VET

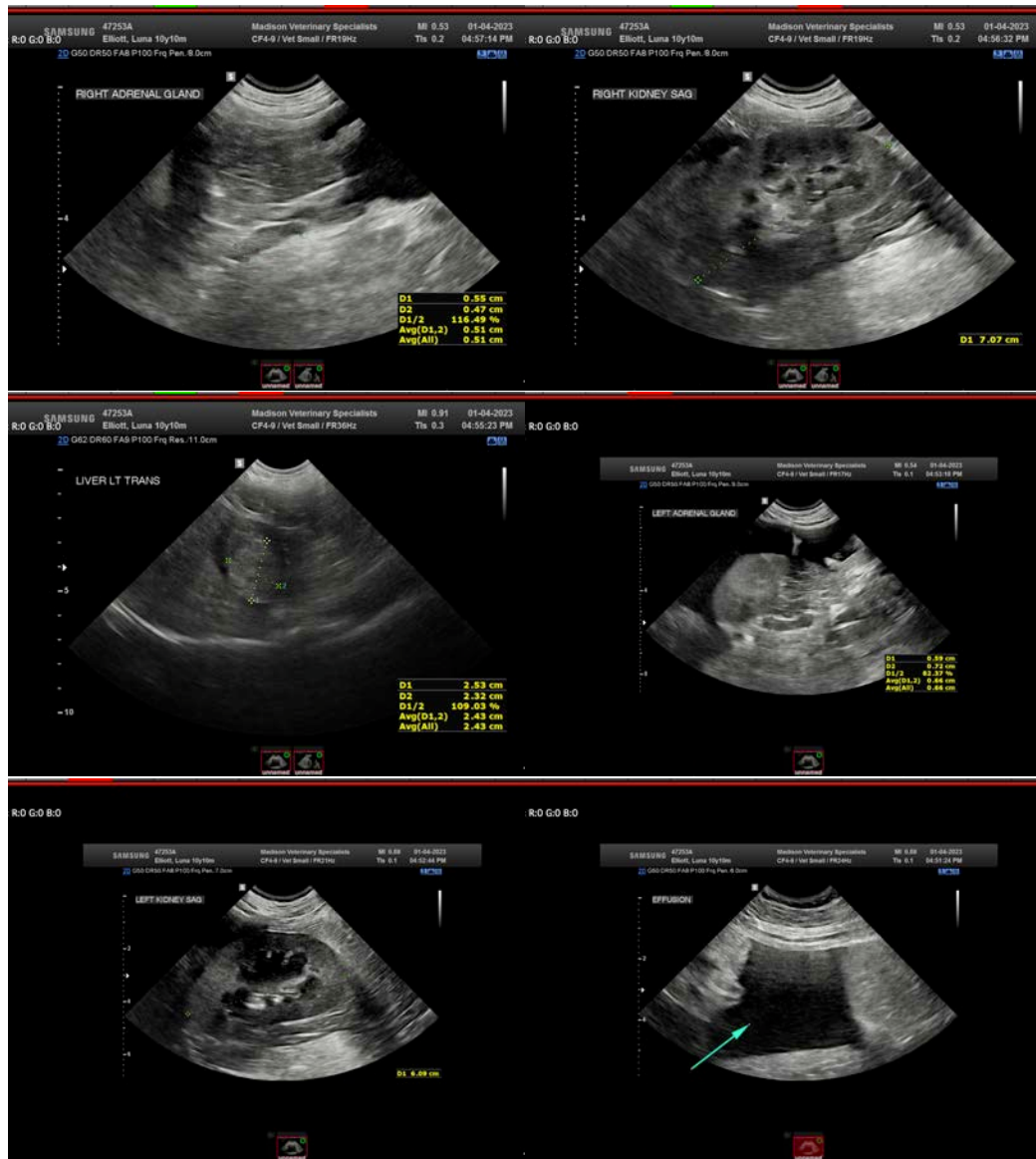
Madison VS - Dr.
Graham

INVOICE

43945

DATE

1/4/23



The information and recommendations provided are based on the images presented by the referring veterinarian/sonographer. No evaluation can be communicated regarding pathology that was not visible in the image/video clips provided.

Thank you for this referral. If the clinical or image interpretation does not parallel your findings or if I can be of any further assistance please contact me.

Kathleen Sennello DVM,MS, Diplomate ACVIM (Small animal Internal Medicine)

kathleen.sennello@sonopath.com