

**PATIENT PRESENTING CLINICAL SIGNS**

Bowser Skaggs

No sedation- No medications- HR 120- RR 70- Heart murmur went from NO murmur in 7/2019, 3/6 in 03/2022 to 5/6 LAS 12.27.2022. Owner came in for skin check ( 6 small pigmented skin masses on ventral abdomen ) and AUS request for MCT (removed from Scrotum April 2022 )met check follow up AUS. Asymptomatic for heart disease.

**SPECIES**

Canine

**BREED**

Mastiff/Lab X

**SEX**

Neutered Male

**AGE**

6 Years 5 Months

**WEIGHT**

42.2 kg

**INTERPRETED BY**

Kathleen Sennello DVM,  
MS, Diplomate ACVIM  
(Small Animal Internal  
Medicine)

**IMAGING PERFORMED BY**

Loetitia Saint-Jacques,  
LVT

**HOSPITAL NAME**

VCA Lakeside AH

**REFERRING VET**

Dr.

**INVOICE**

43931

**DATE**

1/4/23

**ULTRASONOGRAPHIC EXAMINATION OF THE ABDOMEN**

**Urinary System**

The urinary bladder is moderately distended with anechoic urine. The Bladder wall, trigone, ureteral papillae and visible urethra (to a depth of 2cm) appear normal with no evidence of wall thickening, mucosal irregularities, masses or cystic calculi.

The prostate is normal in size (1.47 cm) and shape for this neutered male dog. The parenchyma is homogenous and the external margins are smooth. The prostatic urethra appears normal with no evidence of irregularity, invasion, mass effect or calculi.

The left kidney has a normal shape and size (7.87 cm). Overall echogenicity is normal with adequate corticomedullary distinction and a typical 1:3 cortex:medulla ratio. There is no evidence of focal perinephric inflammation or effusion. There is no evidence of pyelectasia, nephroliths, infarcts or hydroureter. Renal vasculature is normal.

The right kidney has a normal shape and size (8.16 cm) with a cyst in the cortex of the caudal pole measuring 2.21 cm x 1.77 cm (previous measurement 4/19/22 was 2.0 cm x 1.7 cm). Overall echogenicity is normal with adequate corticomedullary distinction and a typical 1:3 cortex:medulla ratio. There is no evidence of focal perinephric inflammation or effusion. There is no evidence of pyelectasia, nephroliths, infarcts or hydroureter. Renal vasculature is normal.

**Adrenal Glands**

The left adrenal gland is normal in size measuring 0.85 cm at the caudal pole. It is observed in its normal position cranial to the left renal artery. It is normal in appearance (uniformly hypoechoic) and shape with no evidence of a mass effect.

The right adrenal gland is normal in size measuring 0.76 cm at the caudal pole. It is observed in its normal position between the cranial aspect of the right kidney and the caudal vena cava. It is normal in appearance (uniformly hypoechoic) and shape with no evidence of a mass effect.

**Spleen**

The spleen is subjectively normal in size, echotexture is homogenous, and the splenic capsule is smooth with no irregularities. The blood flow through the hilus and splenic parenchyma appears normal. No focal parenchymal abnormalities are visualized.

**Liver**

The liver is subjectively normal in size, and echogenicity with smooth peripheral margins. The parenchyma is homogenous echotexture. The visible portions of the vasculature and biliary tract appear normal. No focal nodules or cystic lesions are observed.



**PATIENT**

Bowser Skaggs

The gallbladder lumen is moderately distended. The wall of the gall bladder is not thickened and has a smooth mucosal surface. Luminal contents are mild and primarily anechoic. The cystic and common bile ducts are normal/not visible.

**SPECIES**

**Gastrointestinal**

Canine

The stomach contains minimal luminal contents. It measures at a normal thickness of <0.7cm with some variability due to the presence of rugal folds. The distinction of the gastric wall layers is adequate and there is no impression of reduced peristaltic activity. No masses or focal lesions were observed.

**BREED**

Mastiff/Lab X

The visualized areas of duodenum, jejunum and ileum have a relatively uniform diameter with minimal fluid distension. Wall thickness is normal. Bowel loops follow a curvilinear path with distinct wall layering maintaining the typical 1:3 muscularis:mucosa layer ratio. The duodenum measured as normal (between 0.3-0.5cm in wall thickness) and the jejunum measured as normal (between 0.2-0.47cm.)

**SEX**

Neutered Male

Visualized peristalsis appears appropriate. There were no focal lesions consistent with obstruction or a mass effect observed.

**AGE**

6 Years 5 Months

The ileocecal junction was visualized and exhibited normal intact wall layering and is subjectively of normal thickness. Sections of colon are visualized with formed fecal material and gas shadowing distally. There is no observed focal or generalized colon wall thickening or loss of layering.

**WEIGHT**

42.2 kg

**Pancreas**

The pancreas is normal and isoechoic to surrounding mesentery. There is no evidence of nodules or cystic lesions. There is no evidence of regional mesenteric inflammation or fluid.

**INTERPRETED BY**

Kathleen Sennello DVM,  
MS, Diplomate ACVIM  
(Small Animal Internal  
Medicine)

**Free Abdomen**

Evaluation of the peritoneal cavity did not reveal any evidence of effusion. There is no significant lymphadenopathy. The left sublumbar lymph node measures 0.87 cm. The right measures 0.74 cm. (Previous measurement was 0.98 cm on the left and 0.70 cm on the right) There is a mesenteric lymph node measuring 0.73 cm. The omentum is of normal echogenicity.

**IMAGING PERFORMED BY**

Loetitia Saint-Jacques,  
LVT

**ULTRASONOGRAPHIC FINDINGS**

- Stable caudal right renal cyst

**HOSPITAL NAME**

VCA Lakeside AH

**INTERPRETATION OF THE FINDINGS & FURTHER RECOMMENDATIONS**

Today's scan is stable. There is no new evidence consistent with previous lesions or metastatic disease. The sublumbar lymph nodes appear stable to slightly improved.

**REFERRING VET**

Dr.

**INVOICE**

43931

**DATE**

1/4/23



**PATIENT**

Bowser Skaggs

**SPECIES**

Canine

**BREED**

Mastiff/Lab X

**SEX**

Neutered Male

**AGE**

6 Years 5 Months

**WEIGHT**

42.2 kg

**INTERPRETED BY**

Kathleen Sennello DVM,  
MS, Diplomate ACVIM  
(Small Animal Internal  
Medicine)

**IMAGING  
PERFORMED BY**

Loetitia Saint-Jacques,  
LVT

**HOSPITAL NAME**

VCA Lakeside AH

**REFERRING VET**

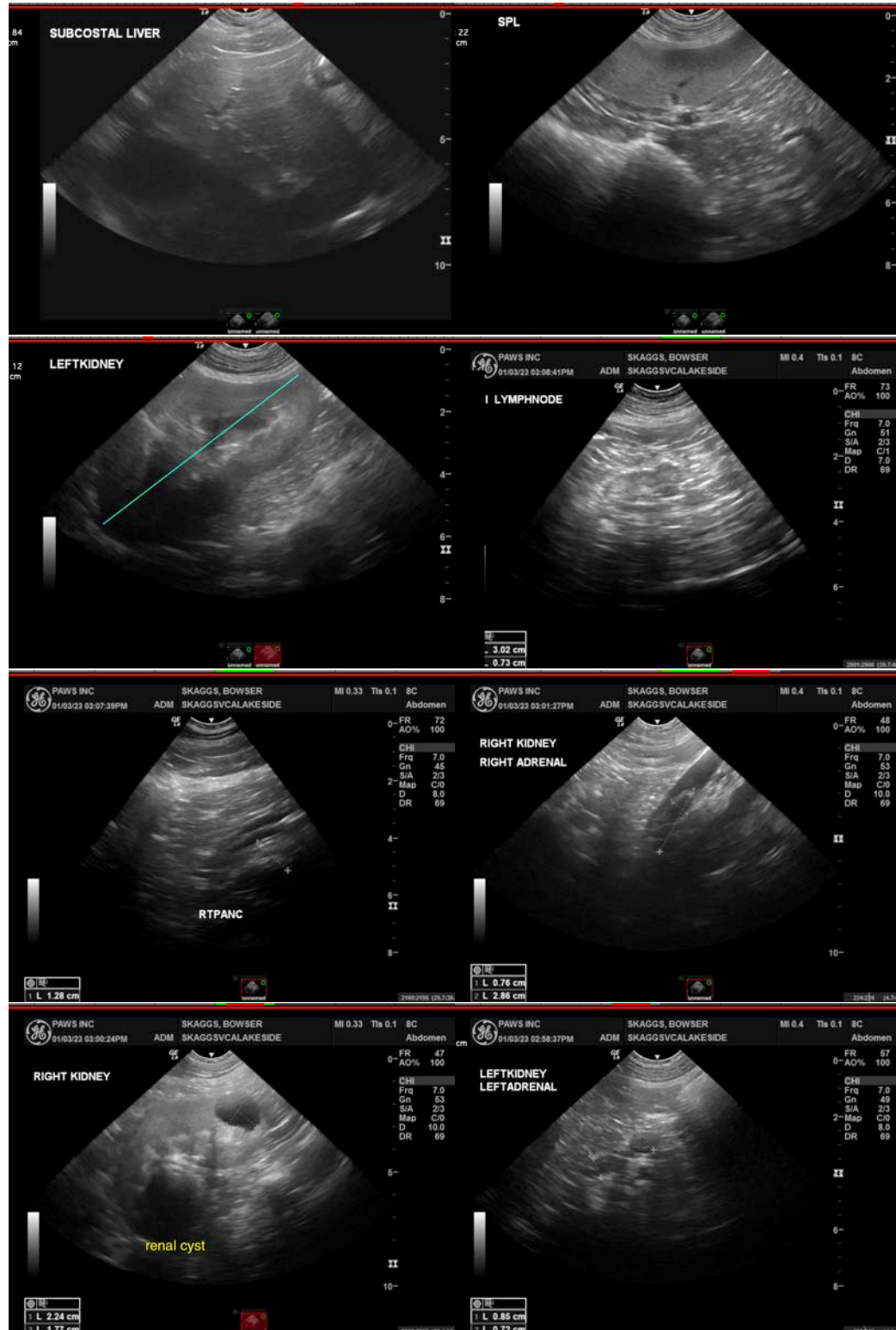
Dr.

**INVOICE**

43931

**DATE**

1/4/23





**PATIENT**

Bowser Skaggs

**SPECIES**

Canine

**BREED**

Mastiff/Lab X

**SEX**

Neutered Male

**AGE**

6 Years 5 Months

**WEIGHT**

42.2 kg

**INTERPRETED BY**

Kathleen Sennello DVM,  
MS, Diplomate ACVIM  
(Small Animal Internal  
Medicine)

**IMAGING  
PERFORMED BY**

Loetitia Saint-Jacques,  
LVT

**HOSPITAL NAME**

VCA Lakeside AH

**REFERRING VET**

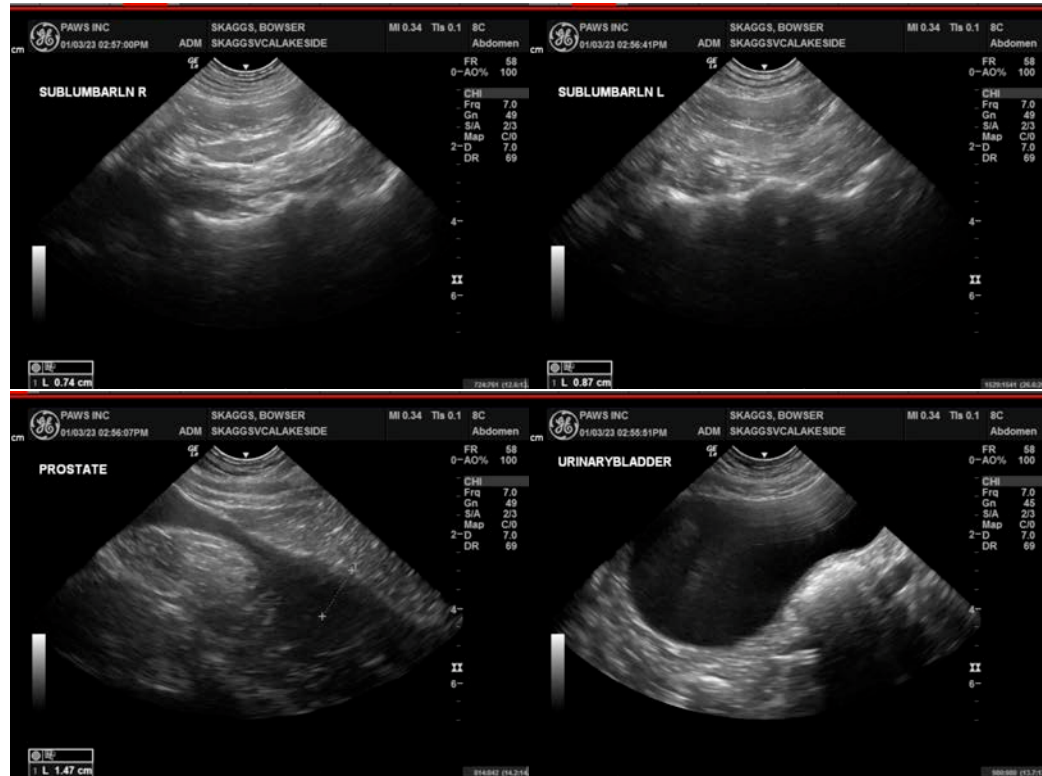
Dr.

**INVOICE**

43931

**DATE**

1/4/23



The information and recommendations provided are based on the images presented by the referring veterinarian/sonographer. No evaluation can be communicated regarding pathology that was not visible in the image/video clips provided.

Thank you for this referral. If the clinical or image interpretation does not parallel your findings or if I can be of any further assistance please contact me.

Kathleen Sennello DVM,MS, Diplomate ACVIM (Small animal Internal Medicine)

kathleen.sennello@sonopath.com