

**PATIENT**

Tula Hughes

PRESENTING CLINICAL SIGNS

Possible pseudo pregnancy. History of false pregnancy not resolving, mammary development. Decreased appetite. BW WNL. Last heat cycle in sept.

SPECIES

Canine

ULTRASONOGRAPHIC EXAMINATION OF THE ABDOMEN**Urinary System**

The urinary bladder is moderately distended with anechoic urine. The Bladder wall, trigone, ureteral papillae and visible urethra (to a depth of 2cm) appear normal with no evidence of wall thickening, mucosal irregularities, masses or cystic calculi.

BREED

Pit Bull X

The left kidney has a normal shape and size (6.27 cm). Overall echogenicity is normal with adequate corticomedullary distinction and a typical 1:3 cortex:medulla ratio. There is no evidence of perinephric inflammation or effusion. There is no evidence of pyelectasia, nephroliths, infarcts or hydroureter. Renal vasculature is normal.

SEX

Intact Female

The right kidney has a normal shape and size (7.04 cm). Overall echogenicity is normal with adequate corticomedullary distinction and a typical 1:3 cortex:medulla ratio. There is no evidence of perinephric inflammation or effusion. There is no evidence of pyelectasia, nephroliths, infarcts or hydroureter. Renal vasculature is normal.

AGE

1 Year

Adrenal Glands

The left adrenal gland is normal in size measuring 0.44 at the caudal pole. It is observed in its normal position cranial to the left renal artery. It is normal in appearance (uniformly hypoechoic) and shape with no evidence of a mass effect.

WEIGHT

65 Pounds

The right adrenal gland is normal in size measuring 0.57 cm at the caudal pole. It is observed in its normal position between the cranial aspect of the right kidney and the caudal vena cava. It is normal in appearance (uniformly hypoechoic) and shape with no evidence of a mass effect.

INTERPRETED BY

Kathleen Sennello DVM,
MS, Diplomate ACVIM
(Small Animal Internal
Medicine)

Spleen

The spleen is subjectively normal in size, echotexture is homogenous, and the splenic capsule is smooth with no irregularities. The blood flow through the hilus and splenic parenchyma appears normal. No focal parenchymal abnormalities are visualized.

IMAGING PERFORMED BY

Amy Mayhew, LVT

Liver

The liver is subjectively normal in size, and echogenicity with smooth peripheral margins. The parenchyma is homogenous echotexture. The visible portions of the vasculature and biliary tract appear normal. No focal nodules or cystic lesions are observed.

HOSPITAL NAME

SVS Imaging Michigan

The gallbladder lumen is moderately distended. The wall of the gall bladder is not thickened and has a smooth mucosal surface. Luminal contents are primarily anechoic. The cystic and common bile ducts are normal/not visible.

REFERRING VET

Family Pet Practice

Gastrointestinal**INVOICE**

33939

The stomach contains minimal luminal contents. It measures at a normal thickness of <0.7cm with some variability due to the presence of rugal folds. The distinction of the gastric wall layers is adequate and there is no impression of reduced peristaltic activity. No masses or focal lesions were observed.

DATE

1/4/22

IMAGING PERFORMED BYSVS Mobile Imaging MI 734-637-7711
svsimagingmi@gmail.comEDUCATIONAL TELECONSULTATION SERVICES™
1-800-838-4268 info@sonopath.com SonoPath.com**PATIENT**

Tula Hughes

SPECIES

Canine

BREED

Pit Bull X

SEX

Intact Female

AGE

1 Year

WEIGHT

65 Pounds

INTERPRETED BYKathleen Sennello DVM,
MS, Diplomate ACVIM
(Small Animal Internal
Medicine)**IMAGING PERFORMED BY**

Amy Mayhew, LVT

HOSPITAL NAME

SVS Imaging Michigan

REFERRING VET

Family Pet Practice

INVOICE

33939

DATE

1/4/22

The visualized areas of duodenum, jejunum and ileum have a relatively uniform diameter with minimal fluid distension. Wall thickness is normal. Bowel loops follow a curvilinear path with distinct wall layering maintaining the typical 1:3 muscularis:mucosa layer ratio. The duodenum measured as normal (between 0.3-0.5cm in wall thickness) and the jejunum measured as normal (between 0.2-0.47cm.) Visualized peristalsis appears appropriate. There were no focal lesions consistent with obstruction or a mass effect observed.

The ileocecal junction was visualized and exhibited normal intact wall layering and is subjectively of normal thickness. Sections of colon are visualized with formed fecal material and gas shadowing distally. There is no observed focal or generalized colon wall thickening or loss of layering.

Pancreas

The pancreas is normal and isoechoic to surrounding mesentery. There is no evidence of nodules or cystic lesions. There is no evidence of regional mesenteric inflammation or fluid.

Free Abdomen

Evaluation of the peritoneal cavity did not reveal any evidence of effusion, or subjective lymphadenomegaly. The Medial iliac nodes appear normal and there was no evidence of a caudal aortic thrombus at the bifurcation. The omentum is of normal uniform echogenicity.

Other

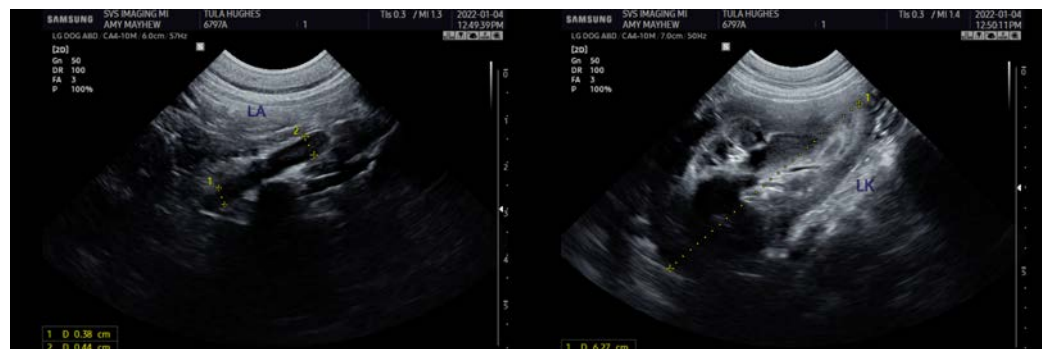The left and right ovaries are visualized and appear within normal limits.

ULTRASONOGRAPHIC FINDINGS

- No significant ultrasonographic abnormalities visualized

INTERPRETATION OF THE FINDINGS & FURTHER RECOMMENDATIONS

No obvious lesions were visualized associated with the reproductive tract, GI tract, etc. Consider consultation with a veterinary reproductive specialist, as I believe some dogs can have a decreased appetite during a pseudopregnancy. Consider placing a T-Shirt if this female is licking her mammary glands, as this can prolong lactation. Additionally, consider removal of any toys or objects that she may be "nesting" with. If the pseudopregnancy is extending beyond 2-3 weeks, medications could be considered, but only under the advice of a reproductive specialist. Additionally, continue to monitor general health with routine/recheck bloodwork, screening for Addison's disease, GI parasites, etc.



IMAGING PERFORMED BY

SVS Mobile Imaging MI 734-637-7711
svsimagingmi@gmail.com



PATIENT

Tula Hughes

SPECIES

Canine

BREED

Pit Bull X

SEX

Intact Female

AGE

1 Year

WEIGHT

65 Pounds

INTERPRETED BY

Kathleen Sennello DVM,
MS, Diplomate ACVIM
(Small Animal Internal
Medicine)

**IMAGING
PERFORMED BY**

Amy Mayhew, LVT

HOSPITAL NAME

SVS Imaging Michigan

REFERRING VET

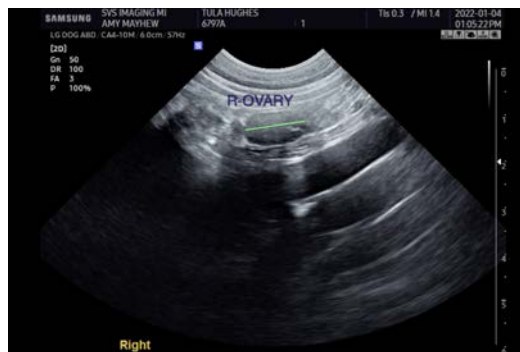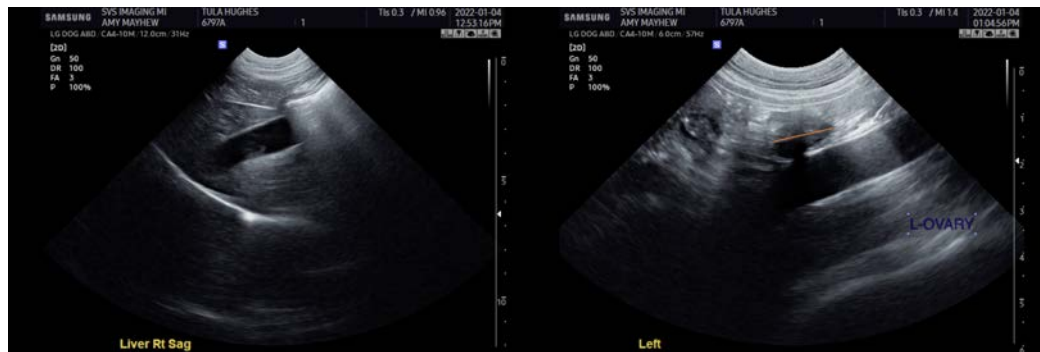
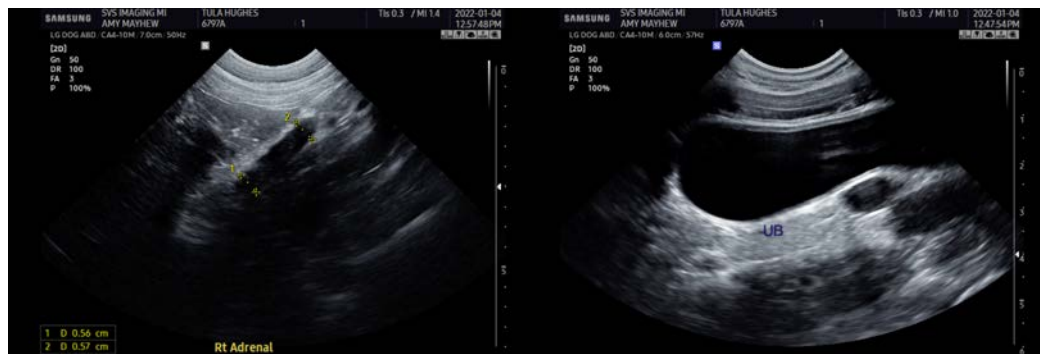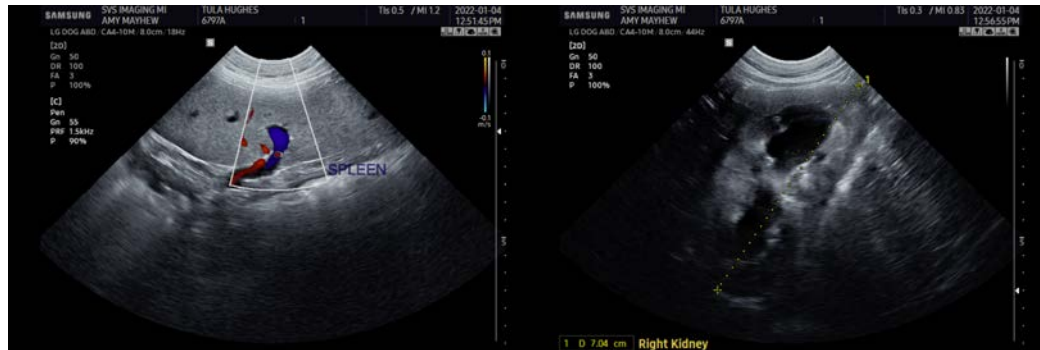
Family Pet Practice

INVOICE

33939

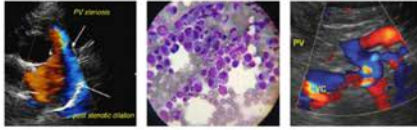
DATE

1/4/22



IMAGING PERFORMED BY

SVS Mobile Imaging MI 734-637-7711
svsimagingmi@gmail.com



PATIENT

Tula Hughes

The information and recommendations provided are based on the images presented by the referring veterinarian. No evaluation can be communicated regarding pathology that was not visible in the image/video clips provided.

SPECIES

Canine

Thank you for this referral. If the clinical or image interpretation does not parallel your findings or if I can be of any further assistance please contact me.

Kathleen Sennello DVM,MS, Diplomate ACVIM (Small animal Internal Medicine)

kathleen.sennello@sonopath.com

BREED

Pit Bull X

SEX

Intact Female

AGE

1 Year

WEIGHT

65 Pounds

INTERPRETED BY

Kathleen Sennello DVM,
MS, Diplomate ACVIM
(Small Animal Internal
Medicine)

**IMAGING
PERFORMED BY**

Amy Mayhew, LVT

HOSPITAL NAME

SVS Imaging Michigan

REFERRING VET

Family Pet Practice

INVOICE

33939

DATE

1/4/22