

**DATE PRESENTING CLINICAL SIGNS**

1/4/22

History: Indoor only cat. No change in diet (ProPlan Urinary Tract Health) Aug 5, 2021- seen for diarrhea. Weighs 16 lbs, 5 oz. Bloodwork unremarkable. Significant dental issues noted. Responded well to Metronidazole and probiotic. Aug 10, 2021 - dental cleaning and extractions performed. Convenia and Gabapentin. Sept 14, 2021- black, tarry stools but formed. Eating well. BAR. Fecal – negative; treated with Sucralfate 1/4 gram BID. Dec 30, 2021 - Ongoing dark, tarry stools. No vomit. 1.5 lb weight loss.

**PATIENT**

Squeeks Opitz

**SPECIES**

Feline

Lab Results: Bloodwork unremarkable except for mild monocytosis.  
Date of Previous IntraPet Ultrasound: No previous IntraPet scans.  
Sedation: Not required to complete full diagnostic ultrasound.  
Stat Report: Not requested.

**BREED**

DSH

**ULTRASONOGRAPHIC EXAMINATION OF THE ABDOMEN****SEX**

Spayed Female

**Urinary System**

The urinary bladder is moderately distended with mild primarily suspended echogenic debris present. The Bladder wall, trigone, ureteral papillae and visible urethra (to a depth of 2cm) appear normal with no evidence of wall thickening, mucosal irregularities, masses or calculi. Echogenic debris of this type can be associated with small crystals, cellular debris and proteinaceous debris.

**AGE**

6/1/13

The left kidney has a normal shape and size (4.49 cm) with a small cortical cyst measuring 0.52 cm. Overall echogenicity is normal with adequate corticomedullary distinction and a typical 1:3 cortex:medulla ratio. There is no evidence of perinephric inflammation or effusion. There is no evidence of pyelectasia, nephroliths, infarcts or hydroureter. Renal vasculature is normal.

**WEIGHT**

14 lb 14 oz

The right kidney has a normal shape and size (4.05 cm). Overall echogenicity is normal with adequate corticomedullary distinction and a typical 1:3 cortex:medulla ratio. There is no evidence of perinephric inflammation or effusion. There is no evidence of pyelectasia, nephroliths, infarcts or hydroureter. Renal vasculature is normal.

**INTERPRETED BY**

Kathleen Sennello DVM,  
MS, Diplomate ACVIM  
(Small Animal Internal  
Medicine)

**Adrenal Glands**

The left adrenal gland is normal in size measuring 0.37 cm at the caudal pole. It is observed in its normal position cranial to the left renal artery. It is normal in appearance (uniformly hypoechoic) and shape with no evidence of a mass effect.

**IMAGING PERFORMED BY**

Stephanie Pearce  
RDMS, RVT

The right adrenal gland is normal in size measuring 0.36 cm at the caudal pole. It is observed in its normal position between the cranial aspect of the right kidney and the caudal vena cava. It is normal in appearance (uniformly hypoechoic) and shape with no evidence of a mass effect.

**HOSPITAL NAME**

Chadwell AH

**Spleen**

The spleen is subjectively normal in size, echotexture is homogenous, and the splenic capsule is smooth with no irregularities. The blood flow through the hilus and splenic parenchyma appears normal. No focal parenchymal abnormalities are visualized.

**REFERRING VET**

Dr. Schaupp

**Liver**

The liver is subjectively normal in size, and echogenicity with smooth peripheral margins. The parenchyma is homogenous echotexture. The visible portions of the vasculature and biliary tract appear normal. No focal nodules or cystic lesions are observed.

**INVOICE**

33953

The gallbladder lumen is moderately distended. The wall of the gall bladder is not thickened and has a smooth mucosal surface. Luminal contents are primarily anechoic. The cystic and common bile ducts are normal/not visible.

### ***Gastrointestinal***

The stomach contains minimal luminal contents. It measures at a normal thickness of <0.36cm with some variability due to the presence of rugal folds. The distinction of the gastric wall layers is adequate and there is no impression of reduced peristaltic activity. No masses or focal lesions were observed.

The visualized areas of duodenum, jejunum and ileum have a uniform diameter with minimal fluid distension. Wall thickness is normal to slightly increased. Bowel loops follow a typical curvilinear path with distinct wall layering, but some areas display a prominent muscularis layer which does not display the typical 1:3 muscularis:mucosa layer ratio. Duodenum wall measured 0.25 cm. Jejunum wall measured 0.21 cm. Visualized peristalsis appears appropriate. There were no focal lesions consistent with obstruction or a mass effect observed.

The ileocecal junction was visualized and exhibited normal intact wall layering and is subjectively of normal thickness. Sections of colon are visualized with formed fecal material and gas shadowing distally. There is no observed focal or generalized colon wall thickening or loss of layering.

### ***Pancreas***

The pancreas is prominent and hypoechoic as compared to the surrounding isoechoic mesentery. There is no evidence of nodules or cystic lesions. There is no evidence of regional mesenteric inflammation or fluid.

### ***Free Abdomen***

Evaluation of the peritoneal cavity did not reveal any evidence of effusion. There are mildly prominent mesenteric lymph nodes observed, measuring 0.42 cm and 0.37 cm. The omentum is generally of normal echogenicity.

## **PRIMARY FINDINGS**

- Hypoechoic, prominent pancreas – The pancreatic changes are most consistent with mild pancreatitis or a recent episode of pancreatic inflammation.
- Prominent muscularis layer to the small intestine – The small intestinal wall changes are most consistent with an inflammatory process (i.e., inflammatory bowel disease) with a low possibility of emerging lymphoma.
- Prominent mesenteric lymph nodes – The prominent abdominal lymph nodes are most consistent with reactive lymphadenitis or lymphoid hyperplasia. Neoplastic infiltration is considered less likely.

## **SECONDARY FINDINGS**

- The echogenic debris in the bladder lumen could be consistent with cells, crystals, and/or mucus.
- Left renal cyst – likely an incidental finding.

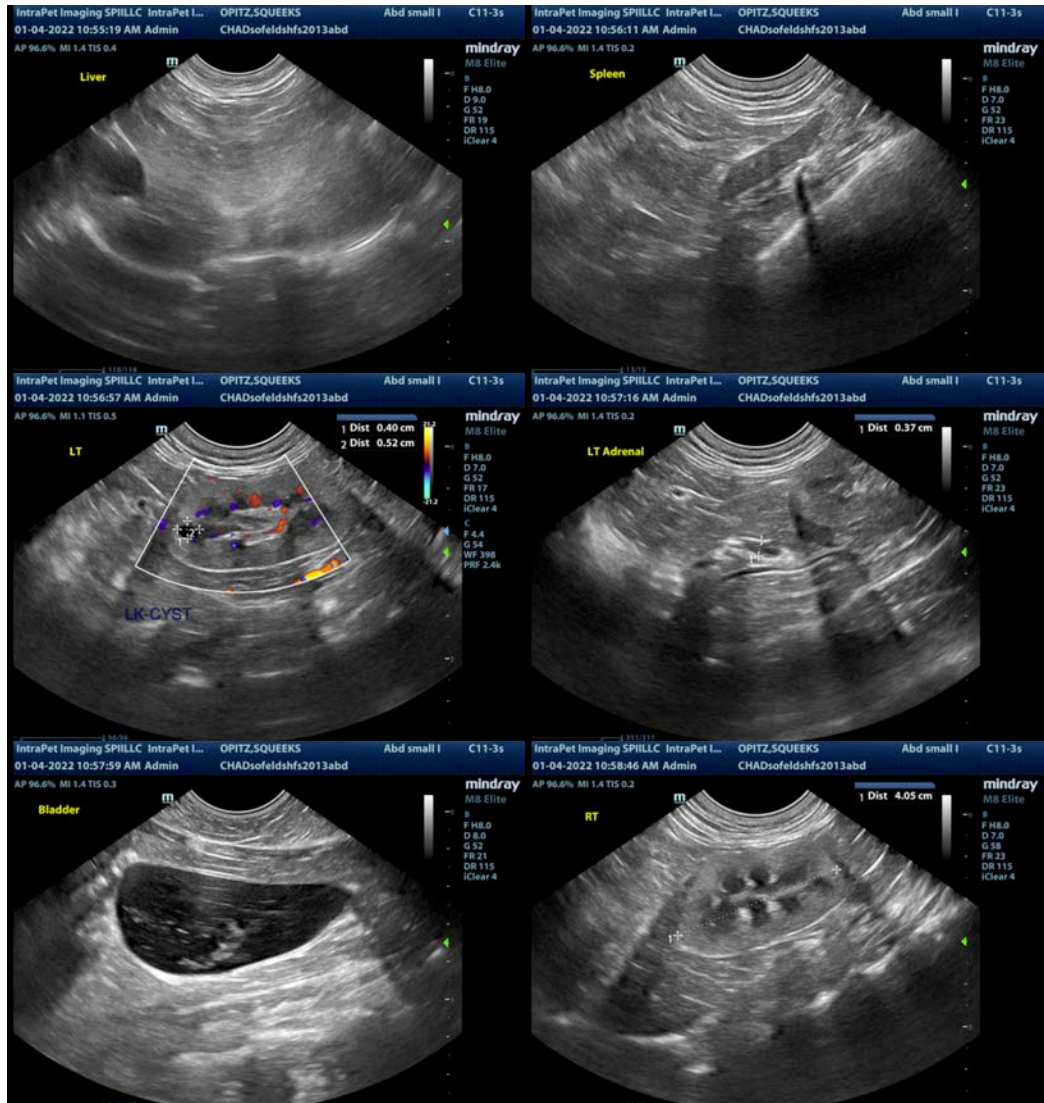
## **INTERPRETATION OF THE FINDINGS & FURTHER RECOMMENDATIONS**

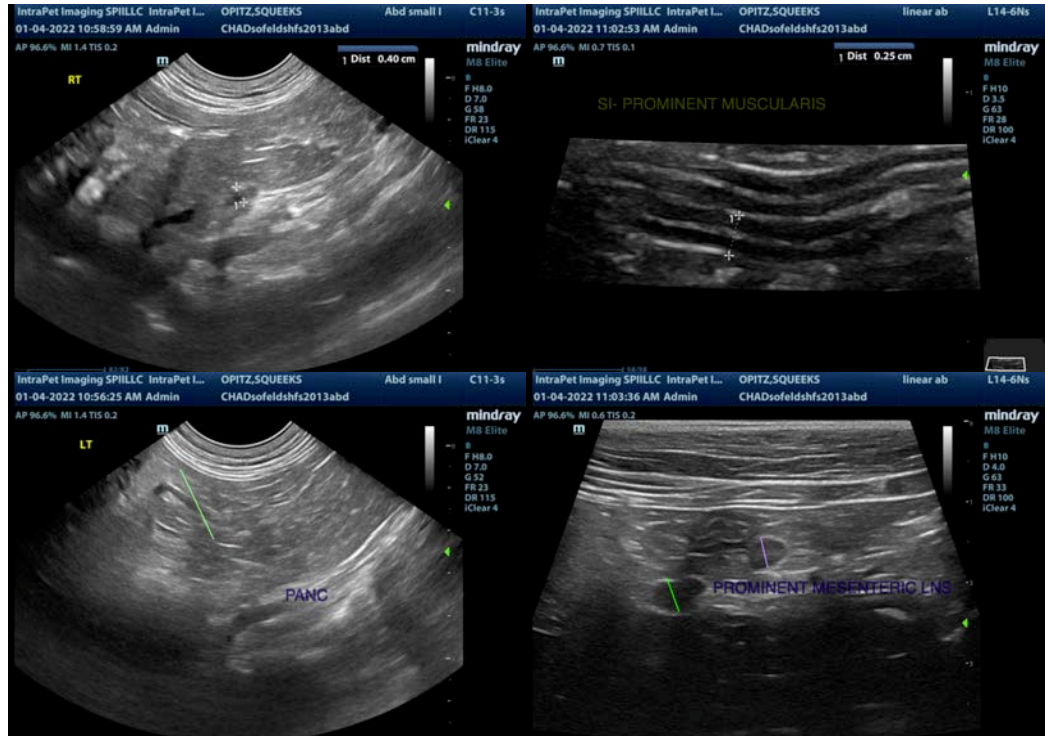
No large gastric or small bowel lesions were visualized to explain the black tarry stools described. The description would most fit a gastric or small bowel lesion.

- Consider a GI panel sent to Texas A&M for qualitative fPLI, TLI, cobalamin and folate to further evaluate for small intestinal disease and pancreatitis.
- Recommend 3-view thoracic radiographs to further evaluate for concurrent intrathoracic disease.
- Based on the chronicity of symptoms, consider upper GI endoscopy to further evaluate the gastric

and duodenal mucosa Unfortunately, this will not evaluate for more distal lesions, but I feel it is a good start.

- If not already done, consider diet trial with a novel protein/hydrolyzed protein prescription diet.
- Consider empirical deworming and testing for GI parasites if appropriate.
- Consider urinalysis and culture to further evaluate the echogenic debris in the urinary bladder.





The information and recommendations provided are based on the images presented by the referring veterinarian. No evaluation can be communicated regarding pathology that was not visible in the image/video clips provided.

Thank you for this referral. If the clinical or image interpretation does not parallel your findings or if I can be of any further assistance please contact me.

Kathleen Sennello DVM,MS, Diplomate ACVIM (Small animal Internal Medicine)  
 kathleen.sennello@sonopath.com