



PATIENT

Layla Halladay

SPECIES

Canine

BREED

Mixed

SEX

Spayed Female

AGE

11 Years

WEIGHT

34 kg

INTERPRETED BY

Kathleen Sennello DVM,
MS, Diplomate ACVIM
(Small Animal Internal
Medicine)

IMAGING PERFORMED BY

Dr. Brian Barnes

HOSPITAL NAME

Westview VH

REFERRING VET

Dr. Brian Barnes

INVOICE

33938

DATE

1/4/22

PRESENTING CLINICAL SIGNS

Acute onset vomiting,
Abnormal PE/Chem/CBC/UA Results: CBC polycythemia rbc 8.92 (5.65-8.87), hgb 208 (131-205)- likely dehydration mild neutrophilia 12.3 (2.9-11.6), mild monocytosis 1.68 (0.16-1.12)- likely a stress leukogram elevated platelets (mild) 539 (148-484)- hemoconcentration/dehydration CHEM TP elevated 84 (52-82) hyperglobulinemia 51 (25-45) albumin high normal suspect aspect of dehydration mild elevation alt 229 (10-125) marked elevation alp 1238 (23-212) suspect pancreatitis, cushings, cholestasis, neoplasia, cholangiohepatitis elevated cholesterol 9.68 (2.8-8.26) Abnormal SNAP Low normal TT4

ULTRASONOGRAPHIC EXAMINATION OF THE ABDOMEN

Urinary System

The urinary bladder is moderately distended with anechoic urine. The Bladder wall, trigone, ureteral papillae and visible urethra (to a depth of 2cm) appear normal with no evidence of wall thickening, mucosal irregularities, masses or cystic calculi.

The left kidney has a normal shape and size (7.35 cm). Overall echogenicity is normal with adequate corticomedullary distinction and a typical 1:3 cortex:medulla ratio. There is no evidence of perinephric inflammation or effusion. There is no evidence of pyelectasia, nephroliths, infarcts or hydroureter. Renal vasculature is normal.

The right kidney has a normal shape and size (7.9 cm). Overall echogenicity is normal with adequate corticomedullary distinction and a typical 1:3 cortex:medulla ratio. There is no evidence of perinephric inflammation or effusion. There is no evidence of pyelectasia, nephroliths, infarcts or hydroureter. Renal vasculature is normal.

Adrenal Glands

The left adrenal gland is normal/borderline large in size measuring 1.0 cm in diameter at the caudal pole. It is observed in its normal position cranial to the left renal artery. It is normal in appearance (uniformly hypoechoic) and shape with no evidence of a mass effect.

The right adrenal gland is normal/borderline large in size measuring 0.95 cm at the caudal pole. It is observed in its normal position between the cranial aspect of the right kidney and the caudal vena cava. It is normal in appearance (uniformly hypoechoic) and shape with no evidence of a mass effect.

Spleen

The spleen is subjectively normal in size, echotexture is homogenous, and the splenic capsule is smooth with no irregularities. The blood flow through the hilus and splenic parenchyma appears normal. No focal parenchymal abnormalities are visualized.

Liver

The liver is large in size, and normal in echogenicity with smooth peripheral margins. The parenchyma is heterogenous in echotexture with subtle, indistinct focal mottling. The visible portions of the vasculature and biliary tract appear normal. There is an isoechoic rounded, bulging area on the left side of the liver measuring 4.7 cm. This could be consistent with a rounded liver lobe or an isoechoic mass effect.

The gallbladder lumen is moderately distended. The wall of the gall bladder is not thickened and has a smooth mucosal surface. Luminal contents are primarily anechoic. The cystic and common bile ducts are normal/not visible.



PATIENT

Layla Halladay

Gastrointestinal

The stomach contains minimal luminal contents. It measures at a normal thickness of <0.7cm with some variability due to the presence of rugal folds. The distinction of the gastric wall layers is adequate and there is no impression of reduced peristaltic activity. No masses or focal lesions were observed.

SPECIES

Canine

The visualized areas of duodenum, jejunum and ileum have a relatively uniform diameter with minimal fluid distension. Wall thickness is normal. Bowel loops follow a curvilinear path with distinct wall layering maintaining the typical 1:3 muscularis:mucosa layer ratio. The duodenum measured as normal (between 0.3-0.5cm in wall thickness) and the jejunum measured as normal (between 0.2-0.47cm.)

BREED

Mixed

Visualized peristalsis appears appropriate. There were no focal lesions consistent with obstruction or a mass effect observed.

SEX

Spayed Female

The ileocecal junction was visualized and exhibited normal intact wall layering and is subjectively of normal thickness. Sections of colon are visualized with formed fecal material and gas shadowing distally. There is no observed focal or generalized colon wall thickening or loss of layering.

Pancreas

AGE

11 Years

The pancreas is large and hypoechoic to surrounding mesentery, particularly in the left limb. There is no evidence of nodules or cystic lesions. There is evidence of regional mesenteric inflammation. Consistent with moderate pancreatitis.

Free Abdomen

WEIGHT

34 kg

Evaluation of the peritoneal cavity did not reveal any evidence of effusion, or subjective lymphadenomegaly. The Medial iliac nodes appear normal and there was no evidence of a caudal aortic thrombus at the bifurcation. The omentum is of normal uniform echogenicity.

INTERPRETED BY

Kathleen Sennello DVM,
MS, Diplomate ACVIM
(Small Animal Internal
Medicine)

PRIMARY FINDINGS

- Large, heterogeneous liver with ill-defined mass effect/rounded liver lobe – The diffuse hepatic changes are non-specific and could be consistent with vacuolar hepatopathy, nodular hyperplasia, inflammatory/immune-mediated disease, fibrosis, extramedullary hematopoiesis, toxic hepatopathy (e.g., copper), infiltrative neoplasia (less likely) or other hepatopathy.
- Hypoechoic left limb of the pancreas with surrounding hyperechoic mesentery – The pancreatic changes are most consistent with mild/moderate pancreatitis/pancreatic inflammation. Recommend fPLI testing and continued monitoring for improvement or possible development of a pancreatic abscess. Consider fine needle aspirate if not improving.

IMAGING PERFORMED BY

Dr. Brian Barnes

SECONDARY FINDINGS

- Borderline bilateral adrenal enlargement – The bilateral adrenomegaly could be consistent with bilateral hyperplasia (e.g., secondary to pituitary-dependent hyperadrenocorticism), bilateral infiltrative neoplasia, inflammatory adrenal disease, other. Correlation with clinical findings is recommended.

HOSPITAL NAME

Westview VH

REFERRING VET

Dr. Brian Barnes

INTERPRETATION OF THE FINDINGS & FURTHER RECOMMENDATIONS

INVOICE

33938

The left limb of the pancreas appears prominent and somewhat inflamed. I suspect this could be a source of the acute vomiting noted, although a primary gastrointestinal issue cannot be ruled out, and if radiographs are concerning, or vomiting continues, I cannot definitively rule out the possibility of foreign material, etc.

DATE

1/4/22



PATIENT

Layla Halladay

The liver appears large and heterogeneous, and there is a rounded area that is isoechoic and subtle. This could be consistent with a rounded, irregular liver lobe, or with an isoechoic mass effect. Options include a contrast CT scan to better evaluate the liver as a whole, a fine needle aspirate of the rounded section of liver lobe, or continued monitoring with ultrasound.

SPECIES

Canine

The adrenal glands both measure as borderline enlarged, but subjectively seem relatively normal. If symptoms of Cushing's disease are present, you could consider adrenal function testing once this pet is feeling better and over the acute illness.

BREED

Mixed

Consider a GI panel with quantitative PLI, TLI, cobalamin and folate to follow this dog's hopeful recovery.

SEX

Spayed Female

AGE

11 Years

WEIGHT

34 kg

INTERPRETED BY

Kathleen Sennello DVM,
MS, Diplomate ACVIM
(Small Animal Internal
Medicine)

IMAGING PERFORMED BY

Dr. Brian Barnes

HOSPITAL NAME

Westview VH

REFERRING VET

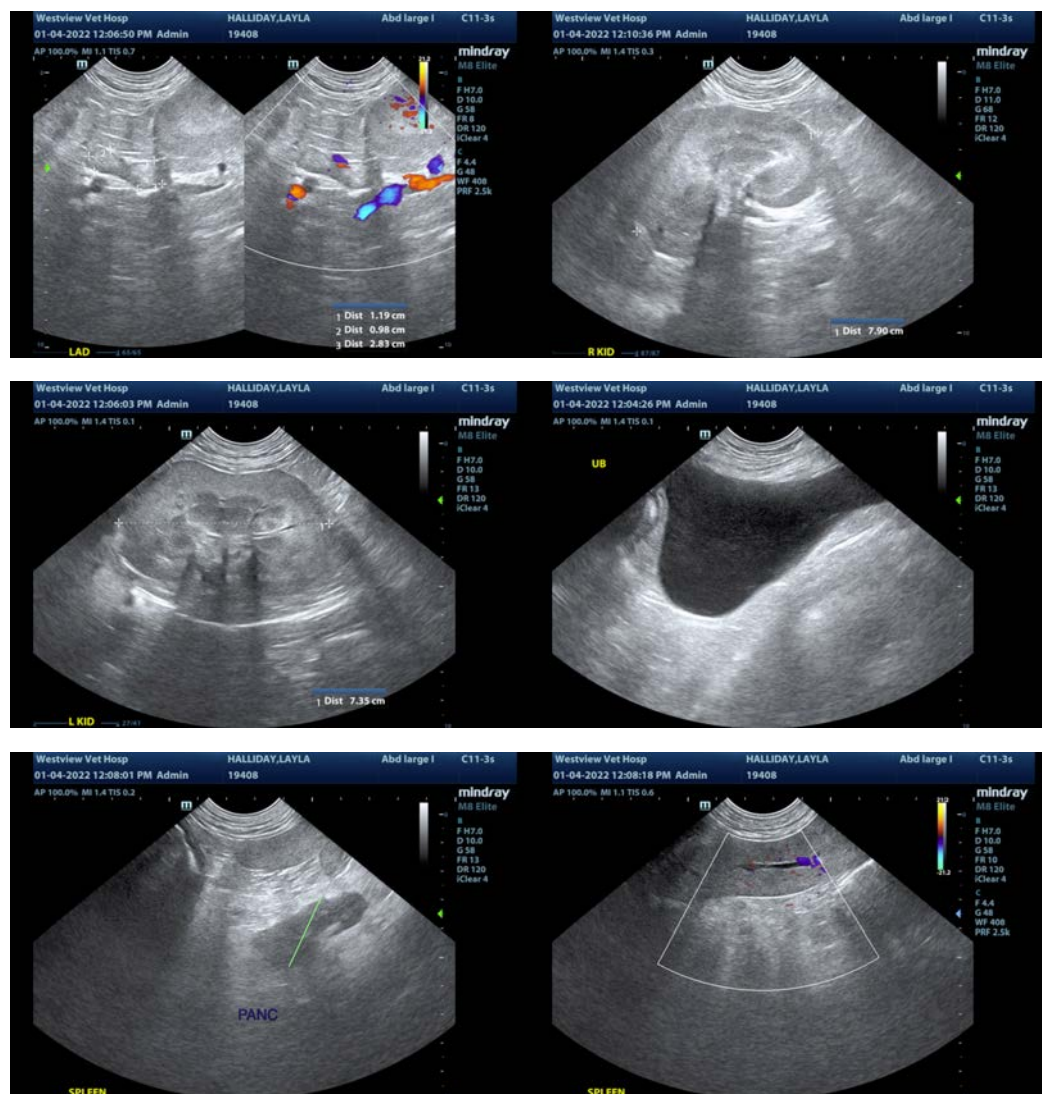
Dr. Brian Barnes

INVOICE

33938

DATE

1/4/22





PATIENT

Layla Halladay

SPECIES

Canine

BREED

Mixed

SEX

Spayed Female

AGE

11 Years

WEIGHT

34 kg

INTERPRETED BY

Kathleen Sennello DVM,
MS, Diplomate ACVIM
(Small Animal Internal
Medicine)

**IMAGING
PERFORMED BY**

Dr. Brian Barnes

HOSPITAL NAME

Westview VH

REFERRING VET

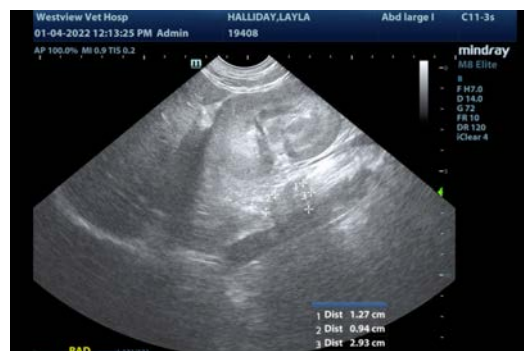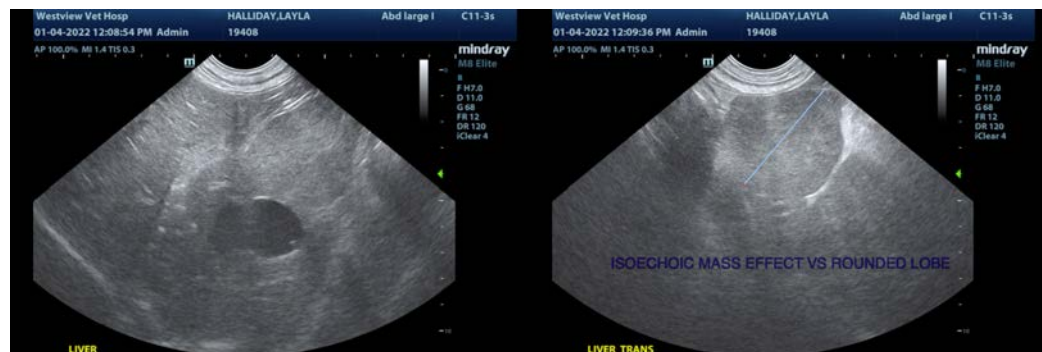Dr. Brian Barnes

INVOICE

33938

DATE

1/4/22



The information and recommendations provided are based on the images presented by the referring veterinarian. No evaluation can be communicated regarding pathology that was not visible in the image/video clips provided.

Thank you for this referral. If the clinical or image interpretation does not parallel your findings or if I can be of any further assistance please contact me.

Kathleen Sennello DVM,MS, Diplomate ACVIM (Small animal Internal Medicine)
kathleen.sennello@sonopath.com