



PATIENT PRESENTING CLINICAL SIGNS

Lucy Wells Elevated liver enzymes- started l/d formula diet and hepatic liver support supplement-

SPECIES Abnormal PE/Chem/CBC/UA Results: ALT went from 149 in November to 123 this month. ALKP went from 399 to 962. Chol from 340 to 510. Lymph 414.

Canine

BREED ULTRASONOGRAPHIC EXAMINATION OF THE ABDOMEN

Shetland Sheepdog

SEX Urinary System

The urinary bladder is moderately distended with anechoic urine. The Bladder wall, trigone, ureteral papillae and visible urethra (to a depth of 2cm) appear normal with no evidence of wall thickening, mucosal irregularities, masses or cystic calculi.

Spayed Female

AGE The left kidney has a normal shape and size (5.36 cm). Overall echogenicity is normal with adequate corticomedullary distinction and a typical 1:3 cortex:medulla ratio. There is no evidence of focal perinephric inflammation or effusion. There is no evidence of pyelectasia, nephroliths, infarcts or hydroureter. Renal vasculature is normal.

9.3 Years

WEIGHT The right kidney is absent.

19.2 Pounds

Adrenal Glands

The left adrenal gland is normal in size measuring 0.61 cm at the caudal pole. It is observed in its normal position cranial to the left renal artery. It is normal in appearance (uniformly hypoechoic) and shape with no evidence of a mass effect.

INTERPRETED BY

Kathleen Sennello DVM,
MS, Diplomate ACVIM
(Small Animal Internal
Medicine)

The right adrenal gland is normal in size measuring 0.59 cm at the caudal pole. It is observed in its normal position between the cranial aspect of the right kidney and the caudal vena cava. It is normal in appearance (uniformly hypoechoic) and shape with no evidence of a mass effect.

IMAGING PERFORMED BY

Loetitia Saint-Jacques,
LVT

Spleen

The spleen is subjectively normal in size, echotexture is homogenous, and the splenic capsule is smooth with no irregularities. The blood flow through the hilus and splenic parenchyma appears normal. No focal parenchymal abnormalities are visualized.

HOSPITAL NAME

Truckee Meadows VH

Liver

The liver is large in size, and echogenicity with smooth peripheral margins. The parenchyma is severely heterogenous in echotexture with subtle, indistinct focal mottling. The visible portions of the vasculature and biliary tract appear normal. There are too numerous to count ill-defined hypoechoic nodules throughout the hepatic parenchyma, varying in size from approximately 0.25-1.5 cm.

REFERRING VET

Dr. Rachel Zsumel

INVOICE

44650

DATE

1/31/23

The gall bladder lumen is moderately distended. The wall of the gall bladder is not thickened and has a smooth mucosal surface. There is a moderate amount of non-organized echogenic debris. The cystic and common bile ducts are normal/not visible.



PATIENT

Lucy Wells

SPECIES

Canine

BREED

Shetland Sheepdog

SEX

Spayed Female

AGE

9.3 Years

WEIGHT

19.2 Pounds

INTERPRETED BY

Kathleen Sennello DVM,
MS, Diplomate ACVIM
(Small Animal Internal
Medicine)

**IMAGING
PERFORMED BY**

Loetitia Saint-Jacques,
LVT

HOSPITAL NAME

Truckee Meadows VH

REFERRING VET

Dr. Rachel Zsumel

INVOICE

44650

DATE

1/31/23

Gastrointestinal

The stomach contains minimal luminal contents. It measures at a normal thickness of <0.7cm with some variability due to the presence of rugal folds. The distinction of the gastric wall layers is adequate and there is no impression of reduced peristaltic activity. No masses or focal lesions were observed.

The visualized areas of duodenum, jejunum and ileum have a relatively uniform diameter with minimal fluid distension. Wall thickness is normal. Bowel loops follow a curvilinear path with distinct wall layering maintaining the typical 1:3 muscularis:mucosa layer ratio. Jejunal wall measures 0.36 cm. Visualized peristalsis appears appropriate. There were no focal lesions consistent with obstruction or a mass effect observed.

The ileocecal junction was visualized and exhibited normal intact wall layering and is subjectively of normal thickness. Sections of colon are visualized with formed fecal material and gas shadowing distally. There is no observed focal or generalized colon wall thickening or loss of layering.

Pancreas

The pancreas is prominent and hypoechoic as compared to the surrounding isoechoic mesentery. There is no evidence of nodules or cystic lesions. There is no evidence of regional mesenteric inflammation or fluid.

Free Abdomen

There is a small amount of free abdominal fluid. No lymphadenopathy. The omental is of normal echogenicity.

PRIMARY FINDINGS

- Large, heterogeneous nodular liver – The diffuse hepatic changes are non-specific and could be consistent with vacuolar hepatopathy, nodular hyperplasia, inflammatory/immune-mediated disease, fibrosis, extramedullary hematopoiesis, toxic hepatopathy (e.g., copper), infiltrative neoplasia (less likely) or other hepatopathy. The nodules observed trend toward a more benign process, but underlying neoplasia cannot be ruled out.
- Moderate to large gallbladder debris – The significance of the aggregated gallbladder debris is unclear. This could represent an early mucocele, cholestasis, or may be secondary to fasting but seems unlikely to be causing a current issue. Recommend continued monitoring.
- Small amount of free abdominal fluid

SECONDARY FINDINGS

- Prominent, hypoechoic pancreas – The pancreatic changes are most consistent with age-related parenchymal remodeling, potentially secondary to a prior inflammatory episode, early fibrosis or chronic pancreatitis.
- Absent right kidney – This is likely a congenital issue.

INTERPRETATION OF THE FINDINGS & FURTHER RECOMMENDATIONS

The liver is severely heterogeneous and nodular. The general appearance of the nodules trends towards a more benign etiology such as regenerative nodules, etc. These are my recommendations for further



PATIENT

Lucy Wells

SPECIES

Canine

BREED

Shetland Sheepdog

SEX

Spayed Female

AGE

9.3 Years

WEIGHT

19.2 Pounds

INTERPRETED BY

Kathleen Sennello DVM,
MS, Diplomate ACVIM
(Small Animal Internal
Medicine)

IMAGING PERFORMED BY

Loetitia Saint-Jacques,
LVT

HOSPITAL NAME

Truckee Meadows VH

REFERRING VET

Dr. Rachel Zsumel

INVOICE

44650

DATE

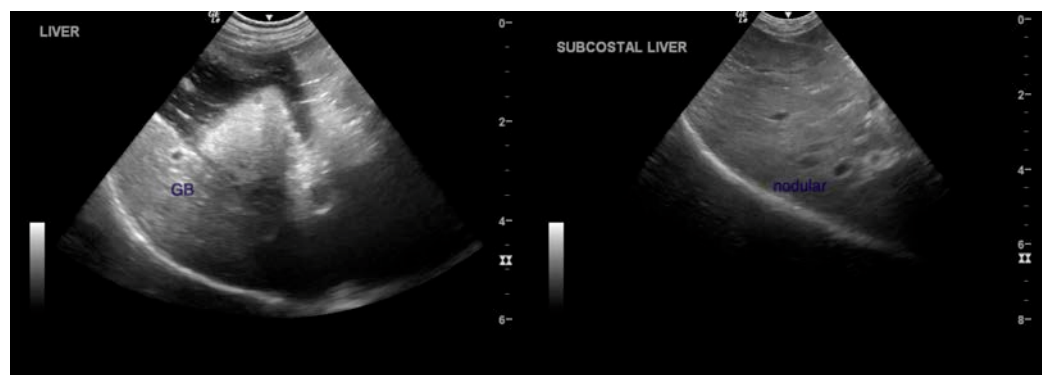
1/31/23

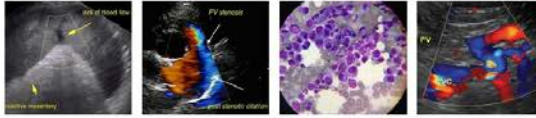
evaluation of a primary ALP elevation:

- Induction phenomena are the most common cause for an elevation in ALP. These are systemic illnesses that 'turn on' the liver enzyme. Causes of this include Cushing's disease, dental disease, arthritis, and numerous others. In many cases the exact cause is unclear but as long as ultrasound and bile acids tests are normal most patients do not have progressive changes in their liver. While liver biopsy is not routinely performed, vacuolar hepatopathy, is noted on most biopsies. This is often non-progressive but in rare cases can be more severe and lead to liver failure.
- If signs of cushings disease are present recommend endocrine function testing to evaluate for cushings disease.
- Consider fine needle aspirate to rule out round cell neoplasia -if this is a concern.
- If a cause for the ALP elevation is not identified: I recommend recheck general blood work every 6 months, ultrasound once per year, and bile acids test every 1-2 years based on other results. If the ALP continues to climb a biopsy could be considered.
- Consider long term use of denamarin, and monitoring for the signs of cushings developing.
- A primary vacuolar hepatopathy can be breed related and is seen in Scottish Terriers, Schnauzers, Cocker spaniels etc..

The cause of the small amount of free abdominal fluid visualized is unknown. Hepatic vasculature is prominent, but this can be seen with the use of Dexdomitor. Correlate with albumin levels, a liver function test, and possibly a cardiac evaluation (cardiac ultrasound and thoracic radiographs).

There is a moderate amount of debris visualized in the gallbladder, although the gallbladder wall appears relatively healthy and there is no surrounding inflammation. Consider chronic Ursodiol therapy and continued monitoring of the gallbladder.





PATIENT

Lucy Wells

SPECIES

Canine

BREED

Shetland Sheepdog

SEX

Spayed Female

AGE

9.3 Years

WEIGHT

19.2 Pounds

INTERPRETED BY

Kathleen Sennello DVM,
MS, Diplomate ACVIM
(Small Animal Internal
Medicine)

IMAGING PERFORMED BY

Loetitia Saint-Jacques,
LVT

HOSPITAL NAME

Truckee Meadows VH

REFERRING VET

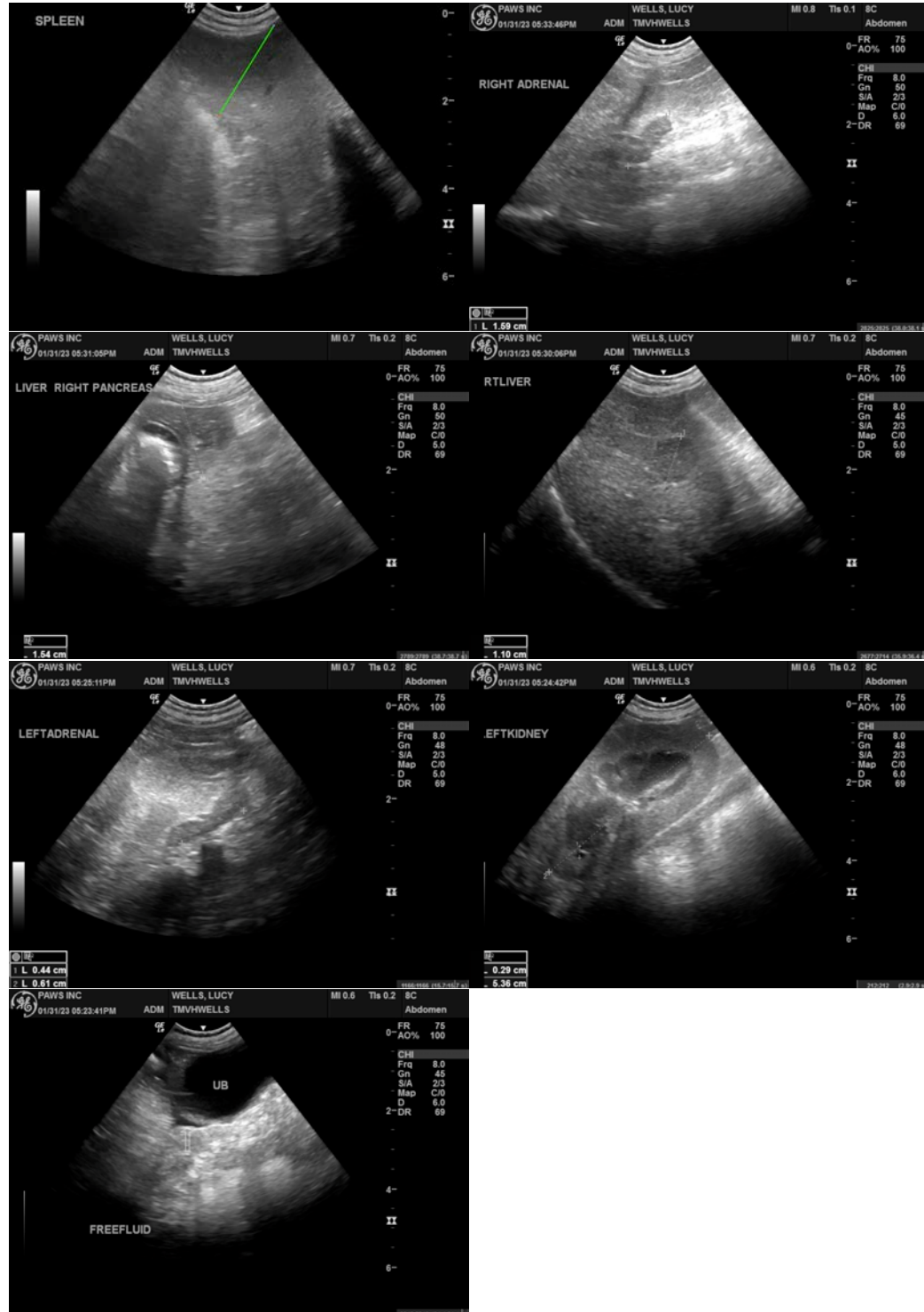
Dr. Rachel Zsumel

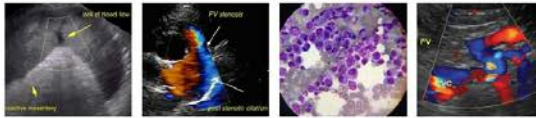
INVOICE

44650

DATE

1/31/23





PATIENT

Lucy Wells

The information and recommendations provided are based on the images presented by the referring veterinarian/sonographer. No evaluation can be communicated regarding pathology that was not visible in the image/video clips provided.

SPECIES

Canine

Thank you for this referral. If the clinical or image interpretation does not parallel your findings or if I can be of any further assistance please contact me.

Kathleen Sennello DVM,MS, Diplomate ACVIM (Small animal Internal Medicine)

BREED

Shetland Sheepdog

kathleen.sennello@sonopath.com

SEX

Spayed Female

AGE

9.3 Years

WEIGHT

19.2 Pounds

INTERPRETED BY

Kathleen Sennello DVM,
MS, Diplomate ACVIM
(Small Animal Internal
Medicine)

**IMAGING
PERFORMED BY**

Loetitia Saint-Jacques,
LVT

HOSPITAL NAME

Truckee Meadows VH

REFERRING VET

Dr. Rachel Zsumel

INVOICE

44650

DATE

1/31/23