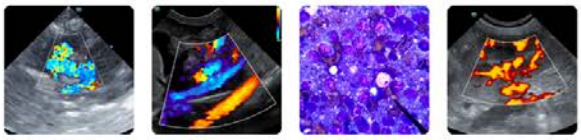

DATE
1/30/26

PATIENT
Baby Girl McGuirk

SPECIES
Feline

BREED
DSH

SEX
Spayed Female

AGE
4/1/14

WEIGHT
8 lbs

INTERPRETED BY
Kathleen Sennello DVM, MS, Diplomate ACVIM (Small Animal Internal Medicine)

HOSPITAL NAME
Cat Sense Feline Hospital

REFERRING VET
Dr. Sinclair

INVOICE
72602

PRESENTING CLINICAL SIGNS

Patient History: I saw Baby Girl for a second opinion for gradually losing weight over the past 2 years. She lost almost 1# since May 2025. Bloodwork was normal. On PE her intestines feel a bit thickened. She has just recently been placed on a food allergy diet trial. We will be drawing blood for a gi panel when she is here for the
ultrasound.

Current Medications: Miratazz.
Labwork Results: Labwork attached. SI appear potentially thickened on the radiographs from May 2025
Date of Previous IntraPet Ultrasound: No previous.
Sedation: Torbugesic.
Stat Report: Requested.
Imaging Performed by: Stephanie Warga RDCS, RVT.

ULTRASONOGRAPHIC EXAMINATION OF THE ABDOMEN

Urinary System

The urinary bladder is moderately distended with anechoic urine. The Bladder wall, trigone, ureteral papillae and visible urethra (to a depth of 2cm) appear normal with no evidence of wall thickening, mucosal irregularities, masses or cystic calculi.

The left kidney has a normal shape and size (3.26 cm). Overall echogenicity is slightly hyperechoic with poor corticomedullary distinction and a typical 1:3 cortex:medulla ratio. There is no evidence of focal perinephric inflammation or effusion. There is no evidence of pyelectasia, nephroliths, infarcts or hydroureter. Renal vasculature is normal.

The right kidney has a normal shape and size (3.37 cm). Overall echogenicity is slightly hyperechoic with mildly reduced corticomedullary distinction and a typical 1:3 cortex:medulla ratio. There is no evidence of focal perinephric inflammation or effusion. There is no evidence of pyelectasia, nephroliths, infarcts or hydroureter. Renal vasculature is normal.

Adrenal Glands

The left adrenal gland is normal in size measuring 0.32 cm at the caudal pole. It is observed in its normal position cranial to the left renal artery. It is normal in appearance (uniformly hypoechoic) and shape with no evidence of a mass effect.

The right adrenal gland is normal in size measuring 0.34 cm at the caudal pole. It is observed in its normal position between the cranial aspect of the right kidney and the caudal vena cava. It is normal in appearance (uniformly hypoechoic) and shape with no evidence of a mass effect.

Spleen

The spleen is subjectively normal in size (0.83 cm), echotexture is homogenous, and the splenic capsule is smooth with no irregularities. The blood flow through the hilus and splenic parenchyma appears normal. No focal parenchymal abnormalities are visualized.

Liver

The liver is subjectively normal in size, and echogenicity with smooth peripheral margins. The parenchyma is homogenous echotexture. The visible portions of the vasculature and biliary tract appear normal. No focal nodules or cystic lesions are observed.

The gall bladder lumen is moderately distended. The wall of the gall bladder is not thickened and has a smooth mucosal surface. There is a moderate amount of non-organized echogenic debris. The cystic and common bile ducts are normal/not visible.

Gastrointestinal

The stomach contains minimal luminal contents. It measures at a normal thickness of <0.36cm with some variability due to the presence of rugal folds. The distinction of the gastric wall layers is adequate and there is no impression of reduced peristaltic activity. No masses or focal lesions were observed.

The visualized areas of duodenum, jejunum and ileum have a uniform diameter with minimal fluid distension. Wall thickness is increased. Bowel loops follow a typical curvilinear path. Some areas have reduced detail of wall layering. Duodenum wall measures 0.36 cm. Jejunum wall measures 0.29 cm. Visualized peristalsis appears appropriate. There are significant segments of small intestine that have greatly diminished wall layering. This area is associated with abnormal mesenteric tissue described under “other”. The areas with reduced detail of wall layering up to 0.40 cm in thickness.

The ileocecal junction was visualized and exhibited normal intact wall layering and is subjectively of normal thickness. Sections of colon are visualized with formed fecal material and gas shadowing distally. There is no observed focal or generalized colon wall thickening or loss of layering.

Pancreas

The pancreas is normal and isoechoic to surrounding mesentery. There is no evidence of nodules or cystic lesions. There is no evidence of regional mesenteric inflammation or fluid.

Free Abdomen

There is scant free fluid noted. There is a significant mesenteric lymphadenopathy with large mesenteric lymph nodes. A pair visualized measure 0.73 cm x 2.34 cm and 0.73 cm x 1.65 cm. The omentum is diffusely hyperechoic.

Other

There is some somewhat poorly defined, irregular, nodular vascular tissue visualized associated with the most severely affected sections of bowel. This could represent omental metastasis. Other lesions are possible.

PRIMARY FINDINGS

- Diffusely thickened small intestine generally with a prominent muscularis layer, and some extensive sections of bowel with complete loss of wall layering – Findings are concerning for neoplastic transformation. Severe inflammation is possible.

- Severely enlarged, hypoechoic, irregular mesenteric lymph nodes – Findings are most consistent with metastatic lymph nodes. Highly reactive lymph nodes are possible.

- Irregular mottled/nodular vascular tissue visualized associated with the abnormal sections of small intestine – Findings are suggestive of a mesenteric lesion possibly consistent with omental metastasis(?)

SECONDARY FINDINGS

- Age related changes visualized associated with both kidneys.

- Moderate gallbladder debris – The significance of the aggregated gallbladder debris is unclear. This could represent an early mucocele, cholestasis, or may be secondary to fasting. Incidental gall bladder debris is less common in cats.

INTERPRETATION OF THE FINDINGS & FURTHER RECOMMENDATIONS

The small intestine is diffusely thickened with some areas exhibiting a prominent muscularis layer. There is a section of bowel in the right caudal abdomen that appears severely thickened with significantly reduced detail of wall layering and significant surrounding inflammation and lymphadenopathy. Additionally in this area there is abnormal, somewhat poorly defined vascular nodular tissue of uncertain nature, but there is concern that this could represent omental metastasis.

Recommend fine needle aspirate of a large mesenteric lymph node +/- a section of small intestine that has loss of layering. Additionally, you could consider a fine needle aspirate of the poorly defined omental lesion.

If a diagnosis is obtained, recommend consultation with a veterinary oncologist regarding the best treatment options and prognosis. Based on the diffuse nature of this lesion, I suspect surgical options will be limited.

Recommend three view thoracic radiographs to evaluate for possible concurrent thoracic disease/involvement (disregard if this has already been done).

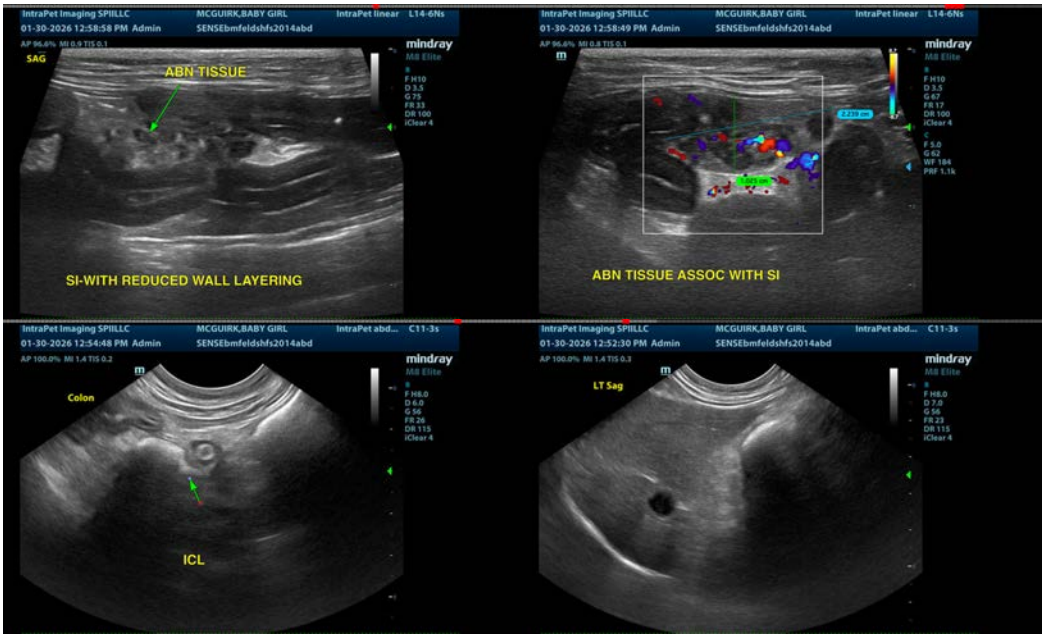

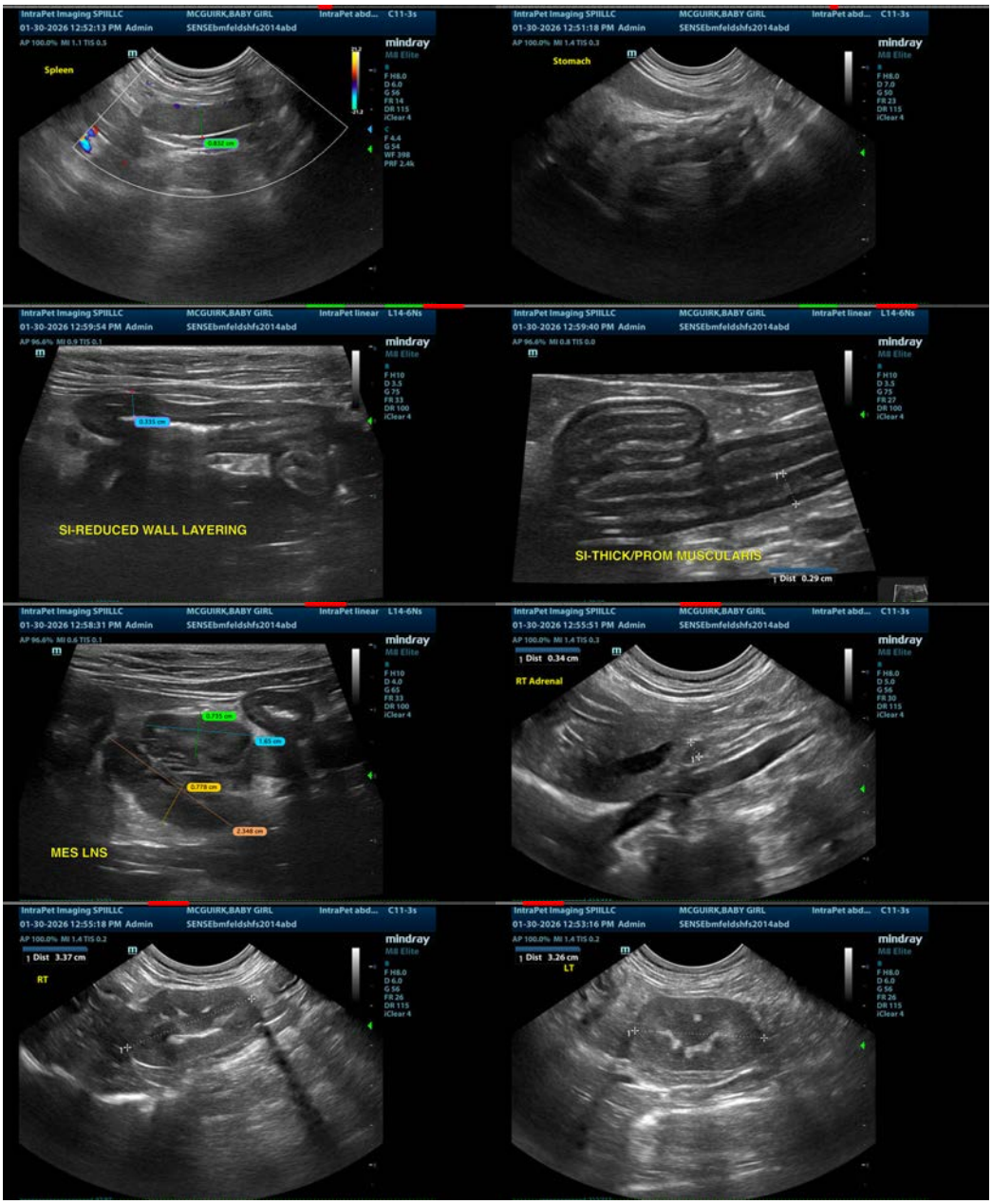
IntraPet Imaging SPIIILLC
MCGUIRK,BABY GIRL
IntraPet abd...
C11-3s
01-30-2026 12:52:13 PM Admin
SENSEbmfeldshfs2014abd
Spleen
IntraPet Imaging SPIIILLC
MCGUIRK,BABY GIRL
IntraPet abd...
C11-3s
01-30-2026 12:51:18 PM Admin
SENSEbmfeldshfs2014abd
Stomach
IntraPet Imaging SPIIILLC
MCGUIRK,BABY GIRL
IntraPet linear
L14-6Ns
01-30-2026 12:59:54 PM Admin
SENSEbmfeldshfs2014abd
SI-REDUCED WALL LAYERING
IntraPet Imaging SPIIILLC
MCGUIRK,BABY GIRL
IntraPet linear
L14-6Ns
01-30-2026 12:59:40 PM Admin
SENSEbmfeldshfs2014abd
SI-THICK/PROM MUSCULARIS
Dist 0.29 cm
IntraPet Imaging SPIIILLC
MCGUIRK,BABY GIRL
IntraPet linear
L14-6Ns
01-30-2026 12:58:31 PM Admin
SENSEbmfeldshfs2014abd
MES LNS
IntraPet Imaging SPIIILLC
MCGUIRK,BABY GIRL
IntraPet abd...
C11-3s
01-30-2026 12:55:51 PM Admin
SENSEbmfeldshfs2014abd
Dist 0.34 cm
RT Adrenal
IntraPet Imaging SPIIILLC
MCGUIRK,BABY GIRL
IntraPet abd...
C11-3s
01-30-2026 12:55:18 PM Admin
SENSEbmfeldshfs2014abd
Dist 3.37 cm
RT
IntraPet Imaging SPIIILLC
MCGUIRK,BABY GIRL
IntraPet abd...
C11-3s
01-30-2026 12:53:16 PM Admin
SENSEbmfeldshfs2014abd
Dist 3.26 cm
LT

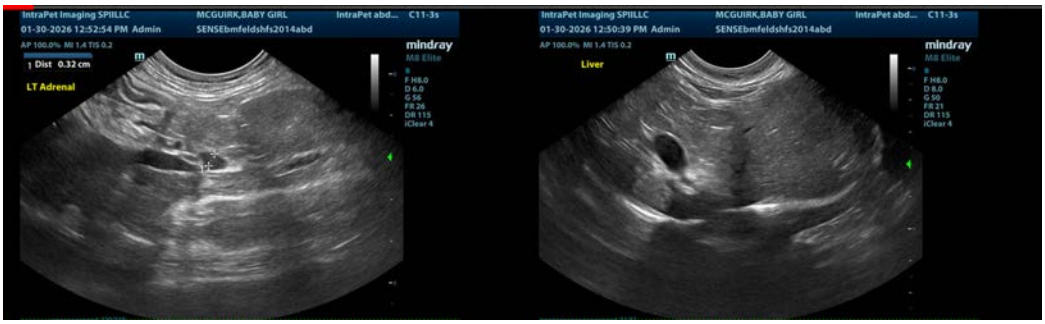

The information and recommendations provided are based on the images presented by the referring veterinarian/sonographer. No evaluation can be communicated regarding pathology that was not visible in the image/video clips provided.

Thank you for this referral. If the clinical or image interpretation does not parallel your findings or if I can be of any further assistance please contact me.

Kathleen Sennello DVM,MS, Diplomate ACVIM (Small animal Internal Medicine)
info@sonopath.com