

PATIENT PRESENTING CLINICAL SIGNS

Max Hongo

Chief Concern/Provisional Diagnosis: P has always had a tendency toward PU/PU but the last few weeks has been drinking significantly more.

SPECIES

Canine

Abnormal PE/Chem/CBC/UA Results: Labwork run 12/30/22 showed elevated ALT=241 (was WNL at 10/6/22); PSL=166 (was not fasted), BUN=23-WNL, Creatinine=1.0-WNL, Platelets=552,000, USG=1.005 & Bacteria (Rods) 10-25. Urine culture is pending. March 2022 when urine was collected via cystocentesis there had been concern for a bladder mass. A BRAF test was run & was negative

BREED

Basset Hound

ULTRASONOGRAPHIC EXAMINATION OF THE ABDOMEN

SEX

Urinary System

Neutered Male

The urinary bladder is significantly distended with anechoic urine. The Bladder wall, trigone, ureteral papillae and visible urethra (to a depth of 2cm) appear normal with no evidence of wall thickening, mucosal irregularities, masses or cystic calculi.

AGE

13 Years

The prostate is normal in size (1.29 cm) and shape for this neutered male dog. The parenchyma is homogenous and the external margins are smooth. The prostatic urethra appears normal with no evidence of irregularity, invasion, mass effect or calculi.

WEIGHT

48.4 Pounds

The left kidney has a normal shape and size (4.94 cm) with occasional small cortical cysts, one of which measures at 0.45 cm. Overall echogenicity is normal with mildly reduced corticomedullary distinction and a typical 1:3 cortex:medulla ratio. There is no evidence of focal perinephric inflammation or effusion. There is no evidence of pyelectasia, nephroliths, infarcts or hydroureter. Renal vasculature is normal.

INTERPRETED BY

Kathleen Sennello DVM,
MS, Diplomate ACVIM
(Small Animal Internal
Medicine)

The right kidney has a normal shape and size (5.85 cm). Overall echogenicity is normal with mildly reduced corticomedullary distinction and a typical 1:3 cortex:medulla ratio. There is no evidence of focal perinephric inflammation or effusion. There is no evidence of pyelectasia, nephroliths, infarcts or hydroureter. Renal vasculature is normal.

IMAGING PERFORMED BY

Loetitia Saint-Jacques,
LVT

Adrenal Glands

HOSPITAL NAME

Desert Hills AH

The left adrenal gland is normal/borderline "plump", measuring 0.95 cm at the caudal pole. It is observed in its normal position cranial to the left renal artery. It is normal in appearance (uniformly hypoechoic) and shape with no evidence of a mass effect.

REFERRING VET

Dr. Amanda Coats

The right adrenal gland is normal/borderline "plump", measuring 0.70 cm at the caudal pole. It is observed in its normal position between the cranial aspect of the right kidney and the caudal vena cava. It is normal in appearance (uniformly hypoechoic) and shape with no evidence of a mass effect.

Spleen

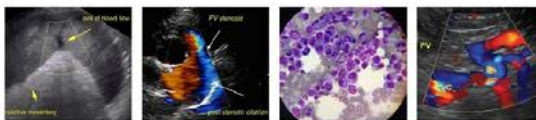
INVOICE

43902

The spleen is subjectively normal in size, echotexture is homogenous, and the splenic capsule is smooth with no irregularities. The blood flow through the hilus and splenic parenchyma appears normal. There is a small hyperechoic nodule visualized measuring 0.60 cm.

DATE

1/3/23



PATIENT *Liver*

Max Hongo The liver is subjectively normal in size, and echogenicity with smooth peripheral margins. The parenchyma is homogenous echotexture. The visible portions of the vasculature and biliary tract appear normal. No focal nodules or cystic lesions are observed.

SPECIES

Canine The gallbladder lumen is moderately distended. The wall of the gall bladder is not thickened and has a smooth mucosal surface. Luminal contents are mild and primarily anechoic. The cystic and common bile ducts are normal/not visible.

BREED

Basset Hound ***Gastrointestinal***

SEX

Neutered Male The stomach contains minimal luminal contents. It measures at a normal thickness of <0.7cm with some variability due to the presence of rugal folds. The distinction of the gastric wall layers is adequate and there is no impression of reduced peristaltic activity. No masses or focal lesions were observed.

AGE

13 Years The visualized areas of duodenum, jejunum and ileum have a relatively uniform diameter with minimal fluid distension. Wall thickness is normal. Bowel loops follow a curvilinear path with distinct wall layering maintaining the typical 1:3 muscularis:mucosa layer ratio. Duodenum wall measures 0.48 cm. Jejunum wall measures 0.37 cm. Visualized peristalsis appears appropriate. There were no focal lesions consistent with obstruction or a mass effect observed.

WEIGHT

48.4 Pounds The ileocecal junction was visualized and exhibited normal intact wall layering and is subjectively of normal thickness. Sections of colon are visualized with formed fecal material and gas shadowing distally. There is no observed focal or generalized colon wall thickening or loss of layering.

INTERPRETED BY

Kathleen Sennello DVM,
MS, Diplomate ACVIM
(Small Animal Internal
Medicine)

Pancreas

The pancreas is normal and isoechoic to surrounding mesentery. There is no evidence of nodules or cystic lesions. There is no evidence of regional mesenteric inflammation or fluid.

IMAGING PERFORMED BY

Loetitia Saint-Jacques,
LVT

Free Abdomen

Evaluation of the peritoneal cavity did not reveal any evidence of effusion. There are visible mesenteric lymph nodes, one of which measures 0.86 cm. The omentum is of normal echogenicity.

PRIMARY FINDINGS

HOSPITAL NAME

Desert Hills AH

- Borderline bilateral adrenomegaly – The bilateral adrenomegaly could be consistent with bilateral hyperplasia (e.g., secondary to pituitary-dependent hyperadrenocorticism), bilateral infiltrative neoplasia, inflammatory adrenal disease, other. Correlation with clinical findings is recommended.

REFERRING VET

Dr. Amanda Coats

- Small, hyperechoic nodule in the spleen – The appearance of this nodule trends towards a benign lesion, although an underlying neoplastic process lesion cannot be ruled out.

INVOICE

43902

SECONDARY FINDINGS

- Decreased corticomedullary distinction in both kidneys with occasional cortical cysts – The bilateral renal findings are consistent with age-related change.

DATE

1/3/23



PATIENT

Max Hongo

SPECIES

Canine

BREED

Basset Hound

SEX

Neutered Male

AGE

13 Years

WEIGHT

48.4 Pounds

INTERPRETATION OF THE FINDINGS & FURTHER RECOMMENDATIONS

Today's scan is relatively normal. Both adrenal glands are uniformly hypoechoic and slightly prominent. If symptoms for Cushing's are present, you could consider adrenal function testing, although an ALT elevation is somewhat atypical. Consider screening for Leptospirosis, and a liver function test +/- fine needle aspirate of the liver, and a urine culture (I believe this is already pending).

Recommend three view thoracic radiographs to evaluate for possible concurrent thoracic disease/involvement.

INTERPRETED BY

Kathleen Sennello DVM,
MS, Diplomate ACVIM
(Small Animal Internal
Medicine)

IMAGING PERFORMED BY

Loetitia Saint-Jacques,
LVT

HOSPITAL NAME

Desert Hills AH

REFERRING VET

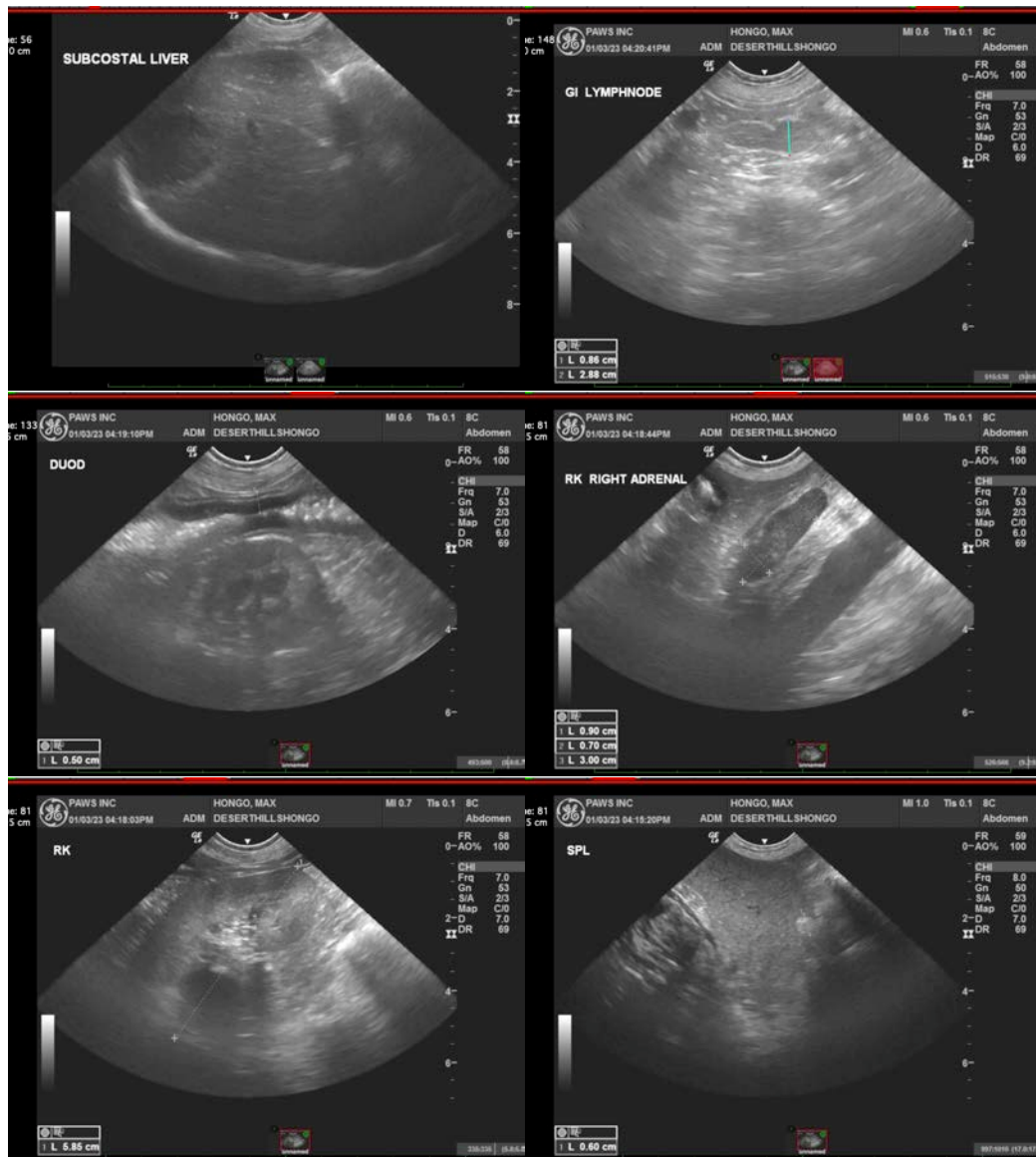
Dr. Amanda Coats

INVOICE

43902

DATE

1/3/23





PATIENT

Max Hongo

SPECIES

Canine

BREED

Basset Hound

SEX

Neutered Male

AGE

13 Years

WEIGHT

48.4 Pounds

INTERPRETED BY

Kathleen Sennello DVM,
MS, Diplomate ACVIM
(Small Animal Internal
Medicine)

**IMAGING
PERFORMED BY**

Loetitia Saint-Jacques,
LVT

HOSPITAL NAME

Desert Hills AH

REFERRING VET

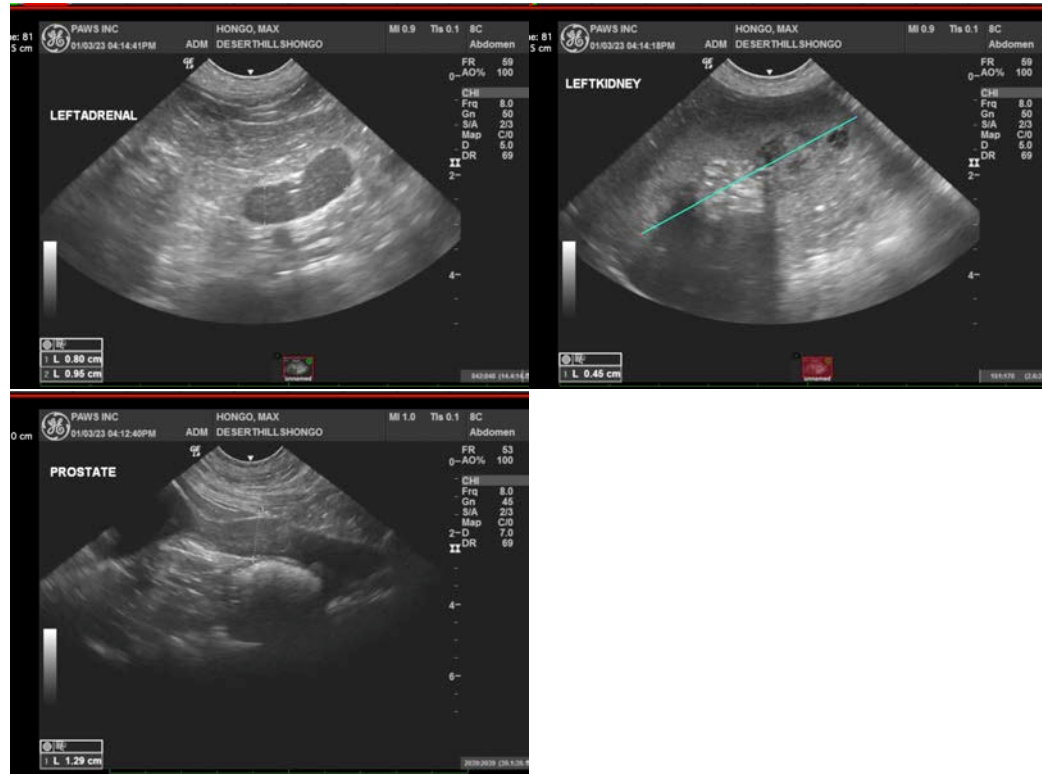
Dr. Amanda Coats

INVOICE

43902

DATE

1/3/23



The information and recommendations provided are based on the images presented by the referring veterinarian/sonographer. No evaluation can be communicated regarding pathology that was not visible in the image/video clips provided.

Thank you for this referral. If the clinical or image interpretation does not parallel your findings or if I can be of any further assistance please contact me.

Kathleen Sennello DVM,MS, Diplomate ACVIM (Small animal Internal Medicine)

kathleen.sennello@sonopath.com