

**DATE PRESENTING CLINICAL SIGNS**

1/29/26 **Patient History:** 12/16/25 presented for annual exam and routine bloodwork

PATIENT

Peanut Cushman

Current Medications: 12/16/25- Rx Ursodiol 300mg 1/4 PO SID #8, Rx Denamarin sm/med 1/2 PO SID 1 bottle

Labwork Results: Labwork not attached, reported as: 12/16/25- ALT 189 (18-121), ALP 676 (5-160), GGT 26 (0-13). 1/27/26- ALT 245 (10-125), ALP 631 (23-212), GGT 21 (0-11)

SPECIES

Canine

Date of Previous IntraPet Ultrasound: No previous.

Sedation: Not required to complete full diagnostic ultrasound.

Stat Report: Not requested.

Imaging Performed by: Stephanie Warga RDCS, RVT.

BREED

Dachshund x

ULTRASONOGRAPHIC EXAMINATION OF THE ABDOMEN**SEX**

Spayed Female

Urinary System

The urinary bladder is moderately distended with anechoic urine. The Bladder wall, trigone, ureteral papillae and visible urethra (to a depth of 2cm) appear normal with no evidence of wall thickening, mucosal irregularities, masses or cystic calculi.

AGE

9/1/13

The left kidney has a normal shape and size (4.77 cm) with occasional small pinpoint cortical mineralizations. Overall echogenicity is slightly hyperechoic with mildly reduced corticomedullary distinction and a typical 1:3 cortex:medulla ratio. There is no evidence of focal perinephric inflammation or effusion. There is no evidence of pyelectasia, infarcts or hydroureter. Renal vasculature is normal.

WEIGHT

18 lbs

The right kidney has a normal shape and size (5.46 cm). Overall echogenicity is slightly hyperechoic with mildly reduced corticomedullary distinction and a typical 1:3 cortex:medulla ratio. There is no evidence of focal perinephric inflammation or effusion. There is no evidence of pyelectasia, nephroliths, infarcts or hydroureter. Renal vasculature is normal.

INTERPRETED BY

Kathleen Sennello DVM,
MS, Diplomate ACVIM
(Small Animal Internal
Medicine)

Adrenal Glands

The left adrenal gland is "plump", measuring 0.61 cm at the cranial pole and 0.75 cm at the caudal pole. It is observed in its normal position cranial to the left renal artery. It is normal in appearance (uniformly hypoechoic) and shape with no evidence of a mass effect.

HOSPITAL NAME

Timonium Animal
Hospital

The right adrenal gland is "plump" measuring 1.04 cm at the cranial pole and 0.73 cm at the caudal pole. It is observed in its normal position between the cranial aspect of the right kidney and the caudal vena cava. It is normal in appearance (uniformly hypoechoic) and shape with no evidence of a mass effect.

REFERRING VET

Dr. Brand

Spleen

The spleen is subjectively normal in size (1.47 cm), echotexture is homogenous, and the splenic capsule is smooth with no irregularities. The blood flow through the hilus and splenic parenchyma appears normal. No focal parenchymal abnormalities are visualized.

INVOICE

72592

Liver

The liver is large in size, and normal in echogenicity with smooth peripheral margins. The parenchyma is heterogenous in echotexture with subtle, indistinct focal mottling. The visible portions of the vasculature and biliary tract appear normal. There is a hyperechoic nodule on the right side of the liver measuring 0.52 cm.

The gall bladder lumen is moderately distended. There is a moderate amount of non-organized echogenic debris. Some of the debris appears mineralized, most consistent with small choleliths. The gallbladder wall is slightly hyperechoic and prominent. The cystic and common bile ducts are normal/not visible.

Gastrointestinal

The stomach contains minimal luminal contents. It measures at a normal thickness of <0.7cm with some variability due to the presence of rugal folds. The distinction of the gastric wall layers is adequate and there is no impression of reduced peristaltic activity. No masses or focal lesions were observed.

The visualized areas of duodenum, jejunum and ileum have a relatively uniform diameter with minimal fluid distension. Wall thickness is normal. Bowel loops follow a curvilinear path with distinct wall layering maintaining the typical 1:3 muscularis:mucosa layer ratio. Duodenum wall measures 0.47 cm. Jejunum wall measures 0.35 cm. Visualized peristalsis appears appropriate. There were no focal lesions consistent with obstruction or a mass effect observed.

Sections of colon are visualized with formed fecal material and gas shadowing distally. There is no observed focal or generalized colon wall thickening or loss of layering.

Pancreas

The pancreas is prominent, hyperechoic and mottled in the right limb. There is no evidence of nodules or cystic lesions. There is no evidence of regional mesenteric inflammation or fluid.

Free Abdomen

Evaluation of the peritoneal cavity did not reveal any evidence of effusion, or subjective lymphadenomegaly. The Medial iliac nodes appear normal and there was no evidence of a caudal aortic thrombus at the bifurcation. The omentum is of normal uniform echogenicity.

ULTRASONOGRAPHIC FINDINGS

- Bilaterally “plump” adrenal glands – Findings could be consistent with anatomic variation or bilateral hyperplasia.
- Age related changes visualized associated with both kidneys.
- Hyperechoic, mottled right limb of the pancreas – Findings could be consistent with chronic pancreatic remodeling and chronic pancreatitis.
- Large, heterogeneous liver with a hyperechoic nodule on the right side – The diffuse hepatic changes are non-specific and could be consistent with vacuolar hepatopathy, nodular hyperplasia, inflammatory/immune-mediated disease, fibrosis, extramedullary hematopoiesis, toxic hepatopathy (e.g., copper), infiltrative neoplasia (less likely) or other hepatopathy. The hyperechoic nodule has a somewhat benign appearance. Recommend continued monitoring.
- Moderate gallbladder debris with occasional small choleliths and a prominent hyperechoic gallbladder wall – The significance of this debris is uncertain. Mild cholecystitis is possible.

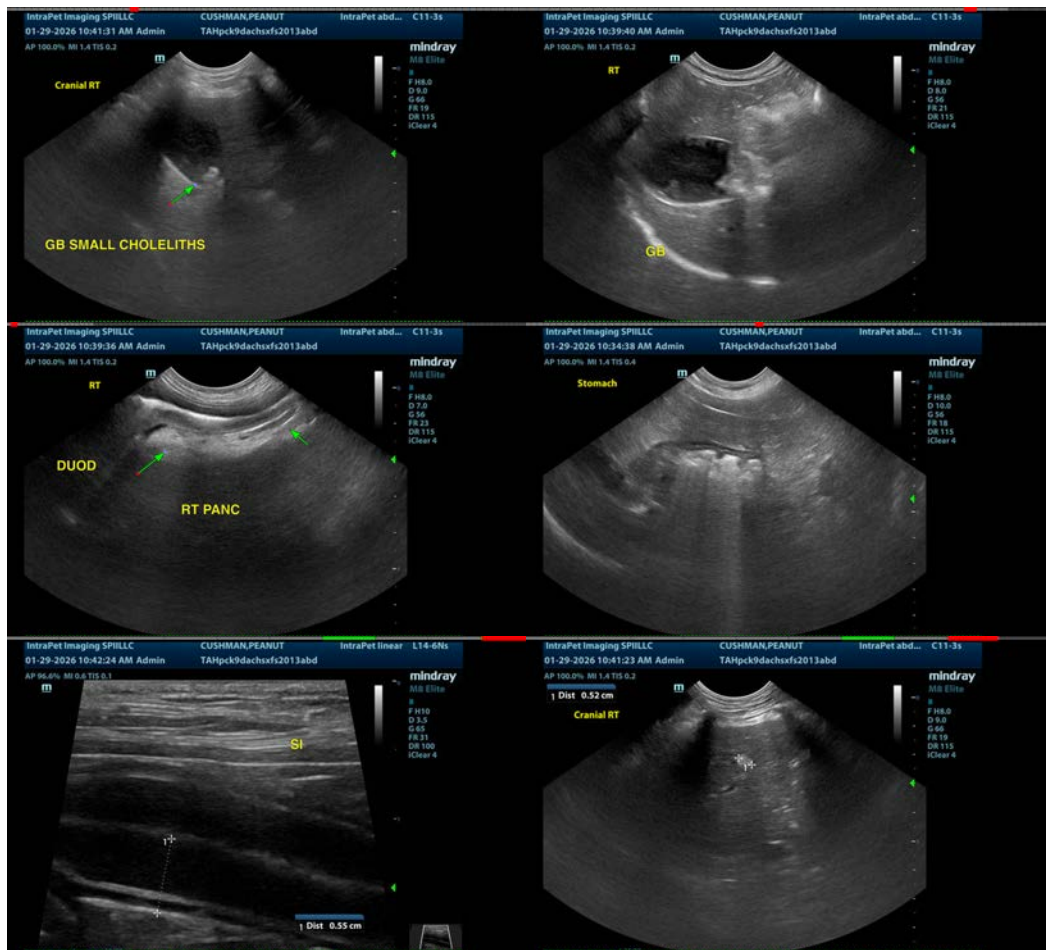
INTERPRETATION OF THE FINDINGS & FURTHER RECOMMENDATIONS

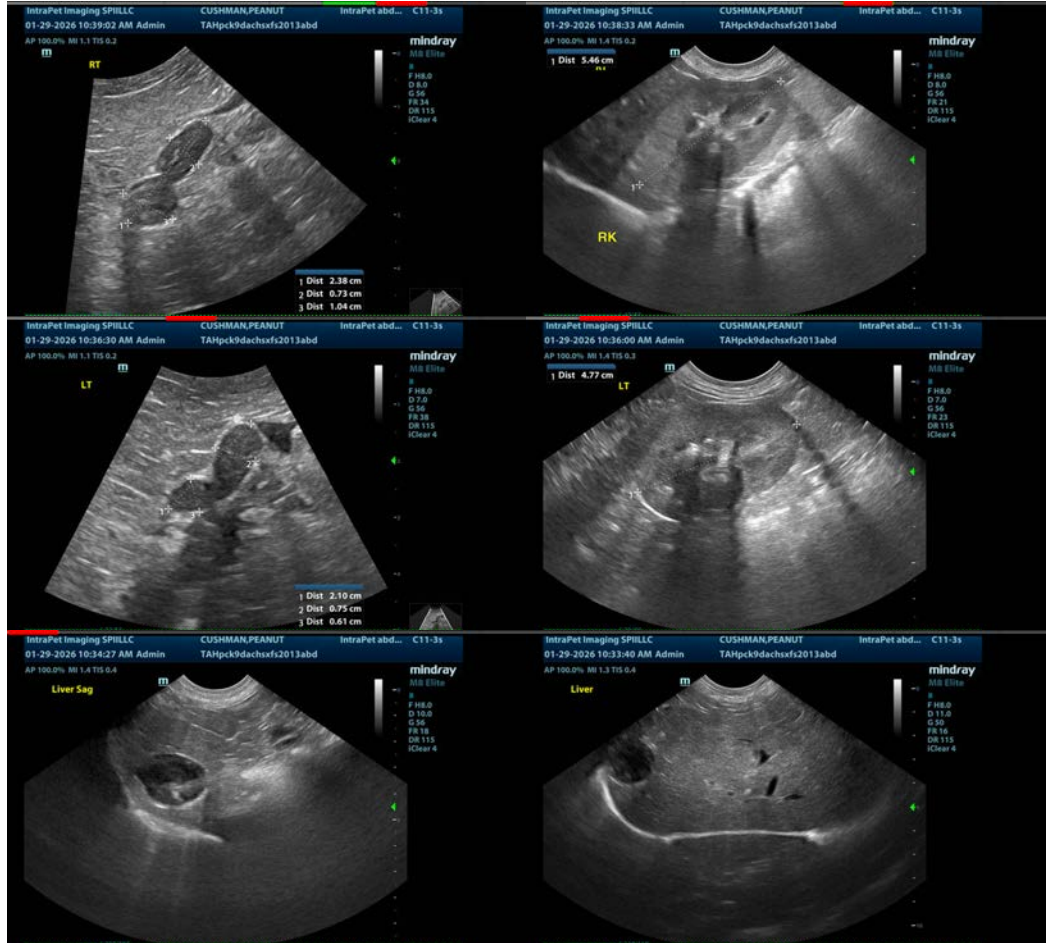
The liver is large and heterogeneous. This is a non-specific finding, but it generally has the appearance most consistent with vacuolar hepatopathy, although other hepatopathies are possible. Additionally, both adrenals

are “plump”. If symptoms consistent with Cushing’s disease are present, you could consider adrenal function testing. Additionally, consider pre- and post-prandial bile acids to assess liver function, and a fine needle aspirate of the liver, looking for evidence of underlying round cell neoplasia or similar.

The gallbladder has a moderate amount of a debris and a prominent hyperechoic wall. This patient is already on Ursodiol. If active cholecystitis is suspected, you could consider a course of antibiotics to see if liver values improve.

The right limb of the pancreas is mottled and hyperechoic. Correlate findings with a PLI level. If active pancreatitis is suspected, consider empirical therapy.





The information and recommendations provided are based on the images presented by the referring veterinarian/sonographer. No evaluation can be communicated regarding pathology that was not visible in the image/video clips provided.

Thank you for this referral. If the clinical or image interpretation does not parallel your findings or if I can be of any further assistance please contact me.

Kathleen Sennello DVM,MS, Diplomate ACVIM (Small animal Internal Medicine)
info@sonopath.com