



## PATIENT

Ruby Stephenson

## SPECIES

Canine

## BREED

Pug

## SEX

Spayed Female

## AGE

6 Years

## WEIGHT

17.1 lbs

## INTERPRETED BY

Kathleen Sennello DVM,  
MS, Diplomate ACVIM  
(Small Animal Internal  
Medicine)

## IMAGING PERFORMED BY

Dr. Mary Pearce

## HOSPITAL NAME

Chambersburg Animal  
Hospital

## REFERRING VET

Dr. Mary Pearce

## INVOICE

72539

## DATE

1/28/26

## PRESENTING CLINICAL SIGNS

Apparently healthy/asymptomatic at home, hx multiple small cutaneous masses. Recent FNA of larger one just below the vulva consistent with MCT. O is pursuing oncology consultation, ultrasound and thoracic radiographs recommended for met check/staging. P was fasted for ultrasound since last night. gabapentin/trazodone given prior to ultrasound appt. No concerns for v/d, no hx gastrointestinal symptoms.

Abnormal PE/Chem/CBC/UA Results: CBC/chem17/lytes all normal 1/28/26. BW roughly once yearly, and historically has been normal as well. Thoracic radiographs show some increased interstitial patterning, pending radiology review on these as well.

## ULTRASONOGRAPHIC EXAMINATION OF THE ABDOMEN

### Urinary System

The urinary bladder is moderately distended with anechoic urine. The Bladder wall, trigone, ureteral papillae and visible urethra (to a depth of 2cm) appear normal with no evidence of wall thickening, mucosal irregularities, masses or cystic calculi.

The left kidney has a normal shape and size (4.23 cm). Overall echogenicity is slightly hyperechoic with mildly reduced corticomedullary distinction and a typical 1:3 cortex:medulla ratio. There is no evidence of focal perinephric inflammation or effusion. There is no evidence of pyelectasia, nephroliths, infarcts or hydroureter. Renal vasculature is normal.

The right kidney has a normal shape and size (4.24 cm). Overall echogenicity is slightly hyperechoic with mildly reduced corticomedullary distinction and a typical 1:3 cortex:medulla ratio. There is no evidence of focal perinephric inflammation or effusion. There is no evidence of pyelectasia, nephroliths, infarcts or hydroureter. Renal vasculature is normal.

### Adrenal Glands

The left adrenal gland is normal in size measuring 0.34 cm at the cranial pole and 0.37 cm at the caudal pole. It is observed in its normal position cranial to the left renal artery. It is normal in appearance (uniformly hypoechoic) and shape with no evidence of a mass effect.

The right adrenal gland is normal in size measuring 0.36 cm at the cranial pole and 0.45 cm at the caudal pole. It is observed in its normal position between the cranial aspect of the right kidney and the caudal vena cava. It is normal in appearance (uniformly hypoechoic) and shape with no evidence of a mass effect.

### Spleen

The spleen is subjectively normal in size (1.44 cm), echotexture is homogenous, and the splenic capsule is smooth with no irregularities. The blood flow through the hilus and splenic parenchyma appears normal. No focal parenchymal abnormalities are visualized.

### Liver

The liver is subjectively normal in size, and echogenicity with smooth peripheral margins. The parenchyma is homogenous echotexture. The visible portions of the vasculature and biliary tract appear normal. No focal nodules or cystic lesions are observed.



## PATIENT

Ruby Stephenson

The gall bladder lumen is significantly distended. Some areas of the wall appear mildly thickened with adherent debris. There is a large amount of primarily non-organized echogenic debris. There is no evidence of bile duct dilation.

## SPECIES

Canine

### ***Gastrointestinal***

The stomach contains a large amount of fluid/shadowing ingesta. It measures at a normal thickness of 0.24 cm with some variability due to the presence of rugal folds. The distinction of the gastric wall layers is adequate and there is no impression of reduced peristaltic activity. No masses or focal lesions were observed.

## BREED

Pug

The visualized areas of duodenum, jejunum and ileum have a relatively uniform diameter with minimal fluid distension. Wall thickness is normal. Bowel loops follow a curvilinear path with distinct wall layering maintaining the typical 1:3 muscularis:mucosa layer ratio. Duodenum wall measures 0.35 cm. Jejunum wall measures 0.25 cm. Visualized peristalsis appears appropriate. There were no focal lesions consistent with obstruction or a mass effect observed.

## SEX

Spayed Female

Sections of colon are visualized with formed fecal material and gas shadowing distally. There is no observed focal or generalized colon wall thickening or loss of layering.

## AGE

6 Years

### ***Pancreas***

The area of the pancreas is normal and isoechoic to surrounding mesentery. There is no evidence of nodules or cystic lesions. There is no evidence of regional mesenteric inflammation or fluid.

## WEIGHT

17.1 lbs

## INTERPRETED BY

Kathleen Sennello DVM,  
MS, Diplomate ACVIM  
(Small Animal Internal  
Medicine)

### ***Free Abdomen***

Evaluation of the peritoneal cavity did not reveal any evidence of effusion, or subjective lymphadenomegaly. The Medial iliac nodes appear normal and there was no evidence of a caudal aortic thrombus at the bifurcation. The omentum is of normal uniform echogenicity.

## IMAGING PERFORMED BY

Dr. Mary Pearce

## ULTRASONOGRAPHIC FINDINGS

- Mildly reduced corticomedullary distinction associated with both kidneys – Findings could be consistent with anatomic variation or early chronic renal changes.
- Large gallbladder debris – A large amount of debris is evident in the gall bladder with no evidence of a mucocele or associated inflammation at this time. This could represent an early mucocele or cholestasis, with minimal evidence of associated inflammation at this time. Continued monitoring of labwork and ultrasound are warranted for progression of this lesion. Ursodiol therapy could be considered.
- Large fluid/ingesta distended stomach – Correlate with the feeding history. If the patient was adequately fasted, consider such differentials as delayed gastric emptying or a partial outflow tract obstruction (none observed).

## HOSPITAL NAME

Chambersburg Animal  
Hospital

## REFERRING VET

Dr. Mary Pearce

## INVOICE

72539

## **INTERPRETATION OF THE FINDINGS & FURTHER RECOMMENDATIONS**

## DATE

1/28/26

The changes observed on today's scan are mild. No significant concern for metastatic mast cell disease is visualized.

The gallbladder has a large amount of intraluminal debris, and some debris adhered to the gallbladder wall. Correlate with current lab work. Consider starting chronic Ursodiol therapy and continued



**PATIENT**

monitoring of the gallbladder.

Ruby Stephenson

**SPECIES**

Canine

**BREED**

Pug

**SEX**

Spayed Female

**AGE**

6 Years

**WEIGHT**

17.1 lbs

**INTERPRETED BY**

Kathleen Sennello DVM,  
MS, Diplomate ACVIM  
(Small Animal Internal  
Medicine)

**IMAGING  
PERFORMED BY**

Dr. Mary Pearce

**HOSPITAL NAME**

Chambersburg Animal  
Hospital

**REFERRING VET**

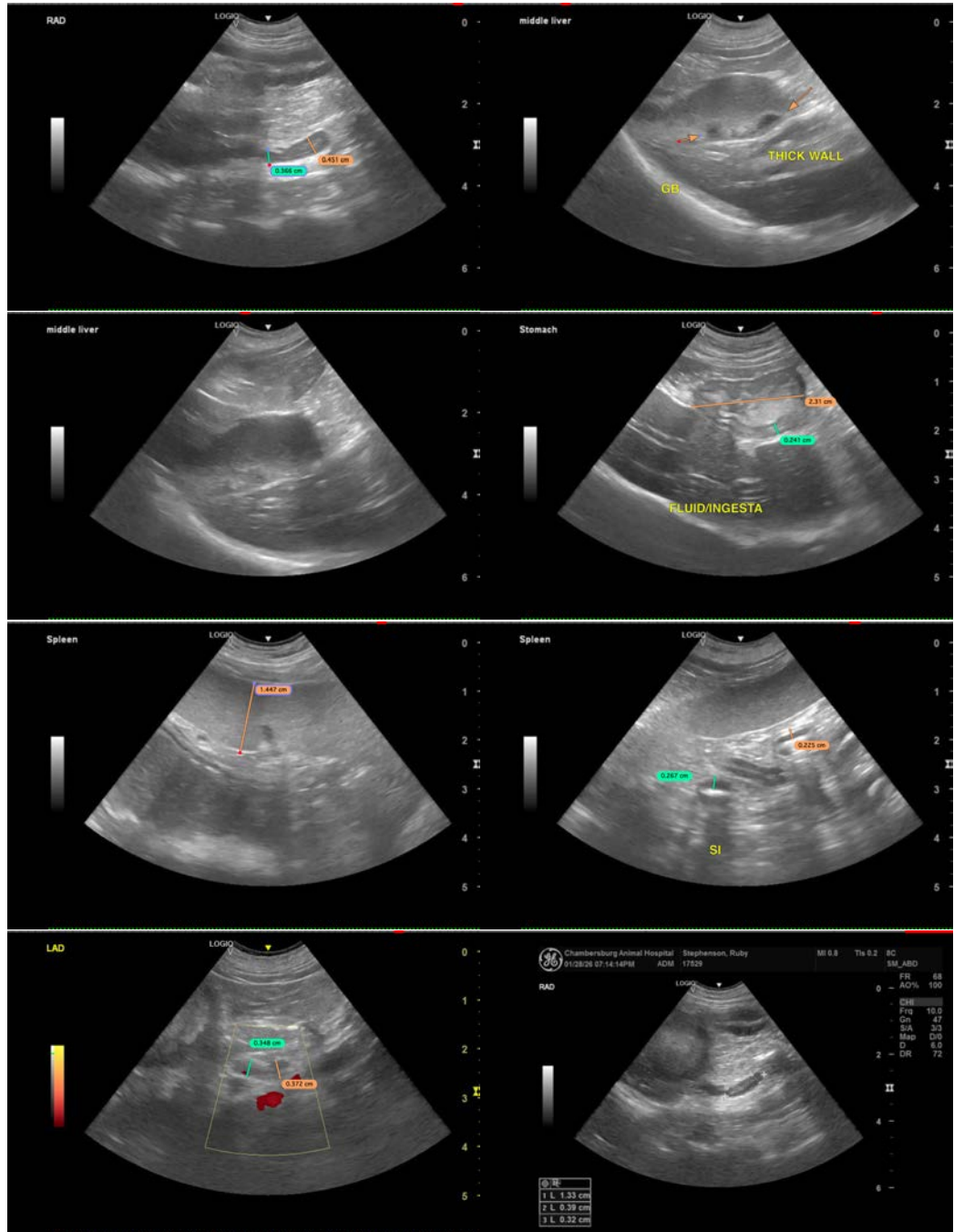
Dr. Mary Pearce

**INVOICE**

72539

**DATE**

1/28/26





## PATIENT

Ruby Stephenson

## SPECIES

Canine

## BREED

Pug

## SEX

Spayed Female

## AGE

6 Years

## WEIGHT

17.1 lbs

## INTERPRETED BY

Kathleen Sennello DVM,  
MS, Diplomate ACVIM  
(Small Animal Internal  
Medicine)

## IMAGING PERFORMED BY

Dr. Mary Pearce

## HOSPITAL NAME

Chambersburg Animal  
Hospital

## REFERRING VET

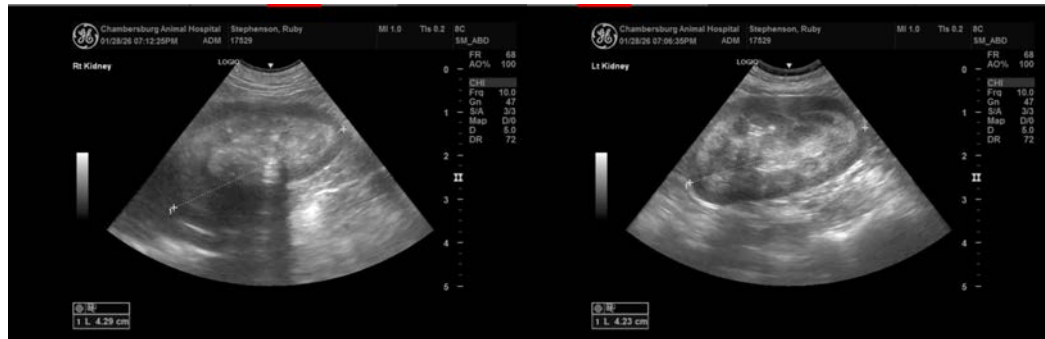
Dr. Mary Pearce

## INVOICE

72539

## DATE

1/28/26



The information and recommendations provided are based on the images presented by the referring veterinarian/sonographer. No evaluation can be communicated regarding pathology that was not visible in the image/video clips provided.

Thank you for this referral. If the clinical or image interpretation does not parallel your findings or if I can be of any further assistance please contact me.

Kathleen Sennello DVM,MS, Diplomate ACVIM (Small animal Internal Medicine)

info@sonopath.com