



**DATE PRESENTING CLINICAL SIGNS**

1/27/26 **Patient History:** Pre-anesthetic screening.

**PATIENT Current Medications:** None listed.

Mimzy Mancini **Labwork Results:** Labwork not attached.

**Date of Previous IntraPet Ultrasound:** No previous.

**Sedation:** Not required to complete full diagnostic ultrasound.

**Stat Report:** Not requested.

**SPECIES Imaging Performed by:** Stephanie Warga RDCS, RVT.

Canine

**ULTRASONOGRAPHIC EXAMINATION OF THE ABDOMEN**

**BREED *Urinary System***

Cavalier King Charles  
Spaniel

The urinary bladder is moderately distended with mild primarily suspended echogenic debris present. The Bladder wall, trigone, ureteral papillae and visible urethra (to a depth of 2cm) appear normal with no evidence of wall thickening, mucosal irregularities, masses or calculi. Echogenic debris of this type can be associated with small crystals, cellular debris and proteinaceous debris.

**SEX**

Spayed Female

The left kidney has a normal shape and size (4.73 cm). Overall echogenicity is normal with adequate corticomedullary distinction and a typical 1:3 cortex:medulla ratio. There is no evidence of focal perinephric inflammation or effusion. There is no evidence of pyelectasia, nephroliths, infarcts or hydroureter. Renal vasculature is normal.

**AGE**

9/24/17

**WEIGHT**

23.5 lbs

The right kidney has a normal shape and size (5.14 cm). Overall echogenicity is normal with adequate corticomedullary distinction and a typical 1:3 cortex:medulla ratio. There is no evidence of focal perinephric inflammation or effusion. There is no evidence of pyelectasia, nephroliths, infarcts or hydroureter. Renal vasculature is normal.

**INTERPRETED BY**

Kathleen Sennello DVM,  
MS, Diplomate ACVIM  
(Small Animal Internal  
Medicine)

***Adrenal Glands***

The left adrenal gland is normal in size measuring 0.25 cm at the cranial pole and 0.44 cm at the caudal pole. It is observed in its normal position cranial to the left renal artery. It is normal in appearance (uniformly hypoechoic) and shape with no evidence of a mass effect.

**HOSPITAL NAME**

Hickory Veterinary  
Hospital

The right adrenal gland is normal in size measuring 0.62 cm at the cranial pole and 0.42 cm at the caudal pole. It is observed in its normal position between the cranial aspect of the right kidney and the caudal vena cava. It is normal in appearance (uniformly hypoechoic) and shape with no evidence of a mass effect.

**REFERRING VET**

Dr. McCourt

***Spleen***

The spleen is subjectively normal in size (1.75 cm), echotexture is homogenous, and the splenic capsule is smooth with no irregularities. The blood flow through the hilus and splenic parenchyma appears normal. No focal parenchymal abnormalities are visualized.

**INVOICE**

72511

***Liver***

The liver is subjectively small in size, and normal in echogenicity with smooth peripheral margins. The parenchyma is homogenous echotexture. The visible portions of the vasculature and biliary tract appear normal. No focal nodules or cystic lesions are observed.

The gall bladder lumen is moderately distended. The wall of the gall bladder is not thickened and has a smooth mucosal surface. Luminal contents are mild and likely incidental at this time. The cystic and common bile ducts are normal/not visible.

### ***Gastrointestinal***

The stomach contains moderate gas. It measures at a normal thickness of <0.7cm with some variability due to the presence of rugal folds. The distinction of the gastric wall layers is adequate and there is no impression of reduced peristaltic activity. Gas artifact interferes with full evaluation of some areas of the stomach and cranial abdomen (likely due to panting/vocalizing?).

The visualized areas of duodenum, jejunum and ileum have a relatively uniform diameter with minimal fluid distension. Wall thickness is normal. Bowel loops follow a curvilinear path with distinct wall layering maintaining the typical 1:3 muscularis:mucosa layer ratio. Jejunum wall measure 0.29 cm. Visualized peristalsis appears appropriate. There were no focal lesions consistent with obstruction or a mass effect observed.

Sections of colon are visualized with formed fecal material and gas shadowing distally. There is no observed focal or generalized colon wall thickening or loss of layering.

### ***Pancreas***

The pancreas is visible and mildly mottled in the right limb. There is no evidence of nodules or cystic lesions. There is no evidence of regional mesenteric inflammation or fluid.

### ***Free Abdomen***

Evaluation of the peritoneal cavity did not reveal any evidence of effusion, or subjective lymphadenomegaly. The Medial iliac nodes appear normal and there was no evidence of a caudal aortic thrombus at the bifurcation. The omentum is of normal uniform echogenicity.

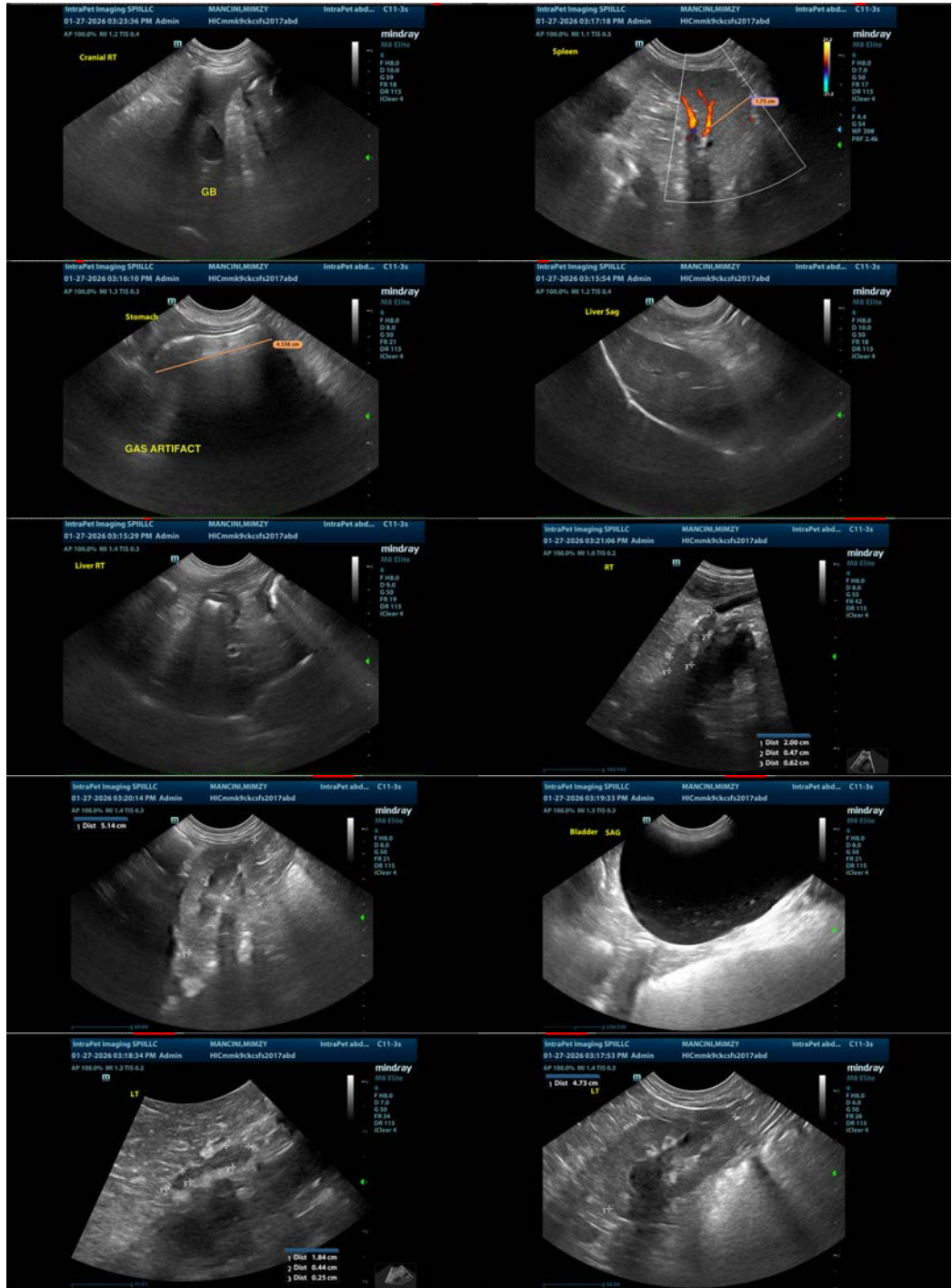
## **ULTRASONOGRAPHIC FINDINGS**

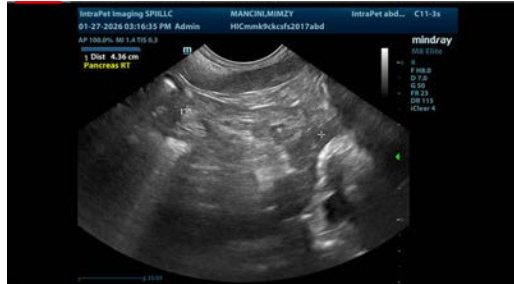- Mild suspended echogenic debris in the urinary bladder – The echogenic debris in the bladder lumen could be consistent with cells, crystals, and/or mucus.
- Prominent, mottled right limb of the pancreas – Findings are most consistent with mild pancreatic remodeling.
- Subjectively small liver – The significance of this is uncertain. Correlate with clinical findings.

## **INTERPRETATION OF THE FINDINGS & FURTHER RECOMMENDATIONS**

No focal lesions are visualized on today's exam. Subjectively, the liver appears somewhat small. Correlate with clinical findings, current lab work, etc. If there is concern for a hepatopathy, consider pre- and post-prandial bile acids to further evaluate.

There is mild echogenic debris visualized suspended in the urinary bladder. Correlate with urinalysis +/- culture results.





**The information and recommendations provided are based on the images presented by the referring veterinarian/sonographer. No evaluation can be communicated regarding pathology that was not visible in the image/video clips provided.**

Thank you for this referral. If the clinical or image interpretation does not parallel your findings or if I can be of any further assistance please contact me.

Kathleen Sennello DVM,MS, Diplomate ACVIM (Small animal Internal Medicine)  
info@sonopath.com