

**DATE PRESENTING CLINICAL SIGNS**

1/27/23 PU/PD with accidents. History of mild ALKP elevation, now markedly elevated.

PATIENT

Maggie Dawson

Current Medications: None.

Lab Results: 4/22- ALKP 283, ALT 193. 1/23- ALKP 849, ALT 252, Tbil 1.6. U/A- SG 1.010.

Date of Previous IntraPet Ultrasound: No previous.

Sedation: Not required to complete full diagnostic ultrasound.

SPECIES

Canine

Stat Report: Not requested.

Imaging Performed By: Rachel Brillhart, RDMS.

BREED

Dachshund Mix

ULTRASONOGRAPHIC EXAMINATION OF THE ABDOMEN**SEX**

Spayed Female

Urinary System

The urinary bladder is moderately distended with anechoic urine. The bladder wall, trigone, ureteral papillae and visible urethra (to a depth of 2.0 cm) appear normal with no evidence of wall thickening, mucosal irregularities, masses or cystic calculi.

AGE

7/8/09

The left kidney has a normal shape and size (5.66 cm). Overall echogenicity is slightly hyperechoic with poor corticomedullary distinction and a typical 1:3 cortex:medulla ratio. There is no evidence of focal perinephric inflammation or effusion. There is no evidence of pyelectasia, infarcts or hydroureter. Renal vasculature is normal. Small nonobstructive nephroliths were present, one of which measures at 0.39 cm.

WEIGHT

41.1 Pounds

The right kidney has a normal shape and size (4.84 cm). Overall echogenicity is slightly hyperechoic with poor corticomedullary distinction and a typical 1:3 cortex:medulla ratio. There is no evidence of focal perinephric inflammation or effusion. There is no evidence of pyelectasia, infarcts or hydroureter. Renal vasculature is normal. Small nonobstructive nephroliths were present.

INTERPRETED BY

Kathleen Sennello DVM,
MS, Diplomate ACVIM
(Small Animal Internal
Medicine)

Adrenal Glands

The left adrenal gland is normal in size measuring 0.68 cm at the caudal pole. It is observed in its normal position cranial to the left renal artery. It is normal in appearance (uniformly hypoechoic) and shape with no evidence of a mass effect.

The right adrenal gland is normal in size measuring 0.76 cm at the caudal pole. It is observed in its normal position between the cranial aspect of the right kidney and the caudal vena cava. It is normal in appearance (uniformly hypoechoic) and shape with no evidence of a mass effect.

HOSPITAL NAME

Hickory VH

Spleen

The spleen is subjectively normal in size, echotexture is homogenous, and the splenic capsule is smooth with no irregularities. The blood flow through the hilus and splenic parenchyma appears normal. No focal parenchymal abnormalities are visualized.

REFERRING VET

Dr. Lyle

Liver

The liver is subjectively large in size, and echogenicity with smooth peripheral margins. The parenchyma is heterogenous in echotexture with subtle, indistinct focal mottling. The visible portions of the vasculature and biliary tract appear normal. No focal nodules or cystic lesions are observed

INVOICE

20801

The gall bladder lumen is moderately distended. The wall of the gall bladder is not thickened and has a smooth mucosal surface. There is a moderate amount of non-organized echogenic debris. The cystic and common bile ducts are normal/not visible.

Gastrointestinal

The stomach contains minimal luminal contents. It measures at a normal thickness of <0.7 cm with some variability due to the presence of rugal folds. The distinction of the gastric wall layers is adequate and there is no impression of reduced peristaltic activity. No masses or focal lesions were observed.

The visualized areas of duodenum, jejunum and ileum have a relatively uniform diameter with minimal fluid distension. Wall thickness is normal. Bowel loops follow a curvilinear path with distinct wall layering maintaining the typical 1:3 muscularis:mucosa layer ratio. The duodenum measured as normal (between 0.3-0.5 cm in wall thickness) and the jejunum measured as normal (between 0.2-0.47 cm.) Visualized peristalsis appears appropriate. There were no focal lesions consistent with obstruction or a mass effect observed.

The ileocecal junction was visualized and exhibited normal intact wall layering and is subjectively of normal thickness. Sections of colon are visualized with formed fecal material and gas shadowing distally. There is no observed focal or generalized colon wall thickening or loss of layering.

Pancreas

The pancreas is normal and isoechoic to surrounding mesentery. There is no evidence of nodules or cystic lesions. There is no evidence of regional mesenteric inflammation or fluid.

Free Abdomen

There is no free fluid present. There is a normal appearing sublumbar lymph node visualized, measuring 0.52 cm. The omentum is of normal echogenicity.

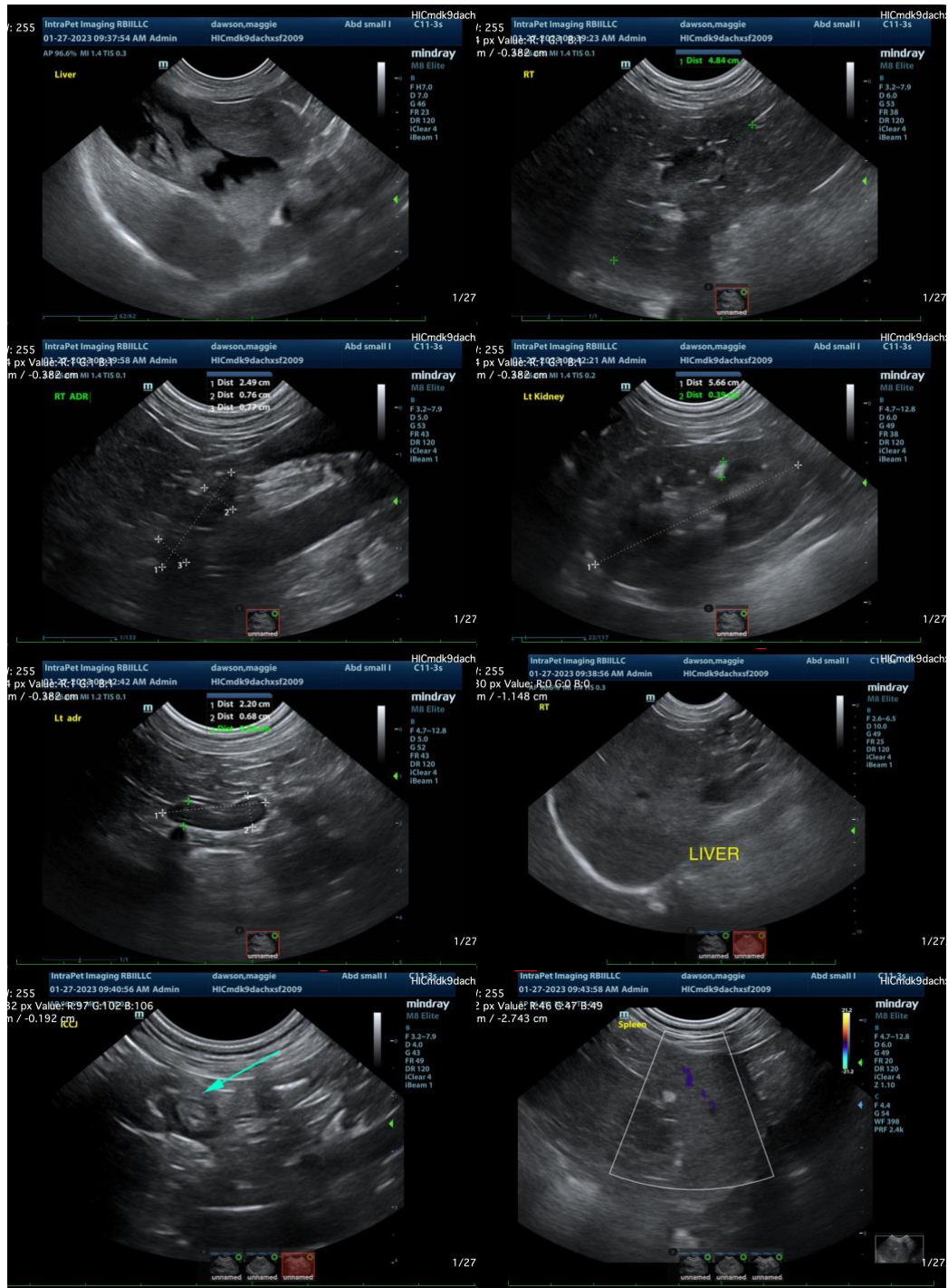
ULTRASONOGRAPHIC FINDINGS

- Decreased corticomedullary distinction in both kidneys with nonobstructive nephroliths. The bilateral renal findings are consistent with age-related change. Hyperechoic foci are visualized in the kidney most consistent with nephroliths. There is no current evidence of obstructive disease. Correlate findings with abdominal radiographs, urinalysis, and culture. Continued monitoring is warranted for progression/obstruction.
- Large heterogenous liver. The diffuse hepatic changes are non-specific and could be consistent with vacuolar hepatopathy, nodular hyperplasia, inflammatory/immune-mediated disease, fibrosis, extramedullary hematopoiesis, toxic hepatopathy (e.g., copper), infiltrative neoplasia (less likely) or other hepatopathy.
- Moderate gallbladder debris. The significance of the aggregated gallbladder debris is unclear. This could represent an early mucocele, cholestasis, or may be secondary to fasting but seems unlikely to be causing a current issue. Recommend continued monitoring.

INTERPRETATION OF THE FINDINGS & FURTHER RECOMMENDATIONS

No focal lesions are visualized associated with the liver and the gallbladder and bile ducts appear relatively normal. The adrenal glands are not overtly large, but this does not definitively rule out Cushings. Recommend further evaluation of the elevated bilirubin; is this real or could this be lab error due to hemolysis, lipemia, etc. (?). If this is real, then there is significant liver dysfunction and I would consider testing for Leptospirosis, performing a fine needle aspirate of the liver, and evaluating the history for any potential toxins, medications, etc., which may be causing liver dysfunction. If the bilirubin elevation is not

real/persistent and Cushings is high on your differential list based on clinical appearance, symptoms, etc., then you could consider adrenal function testing. Additionally, consider a urinalysis and culture and blood pressure evaluation due to the kidney changes observed.



The information and recommendations provided are based on the images presented by the

referring veterinarian. No evaluation can be communicated regarding pathology that was not visible in the image/video clips provided.

Thank you for this referral. If the clinical or image interpretation does not parallel your findings or if I can be of any further assistance please contact me.

Kathleen Sennello DVM,MS, Diplomate ACVIM (Small animal Internal Medicine)
kathleen.sennello@sonopath.com