



PATIENT

Jagger Bruno

SPECIES

Feline

BREED

Maine Coon

SEX

Neutered Male

AGE

4 Years

WEIGHT

23.8 Pounds

INTERPRETED BY

Kathleen Sennello DVM,
MS, Diplomate ACVIM
(Small Animal Internal
Medicine)

**IMAGING
PERFORMED BY**

Kelly Vazquez

HOSPITAL NAME

Sova Animal Hospital

REFERRING VET

Dr. Robert Sova

INVOICE

44549

DATE

1/26/23

PRESENTING CLINICAL SIGNS

Patient presents for generalized ADR, lethargy, sluggish, and agitated - mildly aggressive.
Abnormal PE/Chem/CBC/UA Results: Ca 8.1, monos 6%.

ULTRASONOGRAPHIC EXAMINATION OF THE ABDOMEN

Urinary System

The urinary bladder is moderately distended with anechoic urine. The Bladder wall, trigone, ureteral papillae and visible urethra (to a depth of 2cm) appear normal with no evidence of wall thickening, mucosal irregularities, masses or cystic calculi.

The left kidney has a normal shape and size (4.17 cm). Overall echogenicity is normal with adequate corticomedullary distinction and a typical 1:3 cortex:medulla ratio. There is no evidence of focal perinephric inflammation or effusion. There is no evidence of pyelectasia, nephroliths, infarcts or hydroureter. Renal vasculature is normal.

The right kidney has a normal shape and size (4.54 cm). Overall echogenicity is normal with adequate corticomedullary distinction and a typical 1:3 cortex:medulla ratio. There is no evidence of focal perinephric inflammation or effusion. There is no evidence of pyelectasia, nephroliths, infarcts or hydroureter. Renal vasculature is normal.

Adrenal Glands

The left adrenal gland is normal in size measuring 0.41 cm at the caudal pole. It is observed in its normal position cranial to the left renal artery. It is normal in appearance (uniformly hypoechoic) and shape with no evidence of a mass effect.

The region of the right adrenal (between right cranial kidney and vena cava) is unremarkable, but the adrenal is not distinctly visualized. No evidence of a mass effect is visualized.

Spleen

The spleen is normal/borderline large (1.23 cm), echotexture is homogenous, and the splenic capsule is smooth with no irregularities. The blood flow through the hilus and splenic parenchyma appears normal. No focal parenchymal abnormalities are visualized.

Liver

The liver is subjectively normal in size, and echogenicity with smooth peripheral margins. The parenchyma is homogenous echotexture. The visible portions of the vasculature and biliary tract appear normal. No focal nodules or cystic lesions are observed.

The gallbladder lumen is moderately distended. The wall of the gall bladder is not thickened and has a smooth mucosal surface. Luminal contents are mild and primarily anechoic. The cystic and common bile ducts are normal/not visible.

Gastrointestinal

The stomach contains minimal luminal contents. It measures at a normal thickness of <0.36cm with some variability due to the presence of rugal folds. The distinction of the gastric wall layers is adequate and there is no impression of reduced peristaltic activity. No masses or focal lesions were observed.

The visualized areas of duodenum, jejunum and ileum have a relatively uniform diameter with minimal fluid distension. Wall thickness is normal. Bowel loops follow a curvilinear path with distinct wall



PATIENT

Jagger Bruno

layering maintaining the typical 1:3 muscularis:mucosa layer ratio. Jejunum wall measures 0.20 cm. Visualized peristalsis appears appropriate. There were no focal lesions consistent with obstruction or a mass effect observed.

SPECIES

Feline

The ileocecal junction was visualized and exhibited normal intact wall layering and is subjectively of normal thickness. Sections of colon are visualized with formed fecal material and gas shadowing distally. There is no observed focal or generalized colon wall thickening or loss of layering.

BREED

Maine Coon

Pancreas

The pancreas is normal and isoechoic to surrounding mesentery. There is no evidence of nodules or cystic lesions. There is no evidence of regional mesenteric inflammation or fluid.

SEX

Neutered Male

Free Abdomen

Evaluation of the peritoneal cavity did not reveal any evidence of effusion, or subjective lymphadenomegaly. The Medial iliac nodes appear normal and there was no evidence of a caudal aortic thrombus at the bifurcation. The omentum is of normal uniform echogenicity.

AGE

4 Years

ULTRASONOGRAPHIC FINDINGS

WEIGHT

23.8 Pounds

- Borderline large spleen – I suspect this is within normal limits for this large cat.

INTERPRETATION OF THE FINDINGS & FURTHER RECOMMENDATIONS

INTERPRETED BY

Kathleen Sennello DVM, MS, Diplomate ACVIM (Small Animal Internal Medicine)

No focal lesions were visualized today to explain the clinical signs described. The spleen measures as large, but I suspect this is within normal limits for this large cat, and it is of normal echogenicity with no focal lesions. Correlate these findings with serial lab work and radiographs of the abdomen and thorax. Consider the possibility of ingested foreign material (none observed, but ultrasound can have low sensitivity for picking up some types of ingested foreign material), pancreatic inflammation not evident on today's scan (consider a quantitative fPLI), intrathoracic disease, metabolic disease (if a low calcium persists consider an ionized calcium and PTH level).

IMAGING PERFORMED BY

Kelly Vazquez

HOSPITAL NAME

Sova Animal Hospital

REFERRING VET

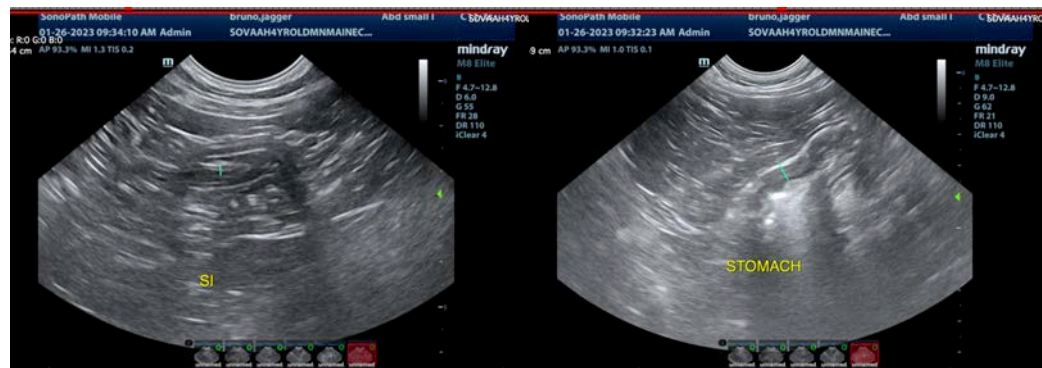
Dr. Robert Sova

INVOICE

44549

DATE

1/26/23





PATIENT

Jagger Bruno

SPECIES

Feline

BREED

Maine Coon

SEX

Neutered Male

AGE

4 Years

WEIGHT

23.8 Pounds

INTERPRETED BY

Kathleen Sennello DVM,
MS, Diplomate ACVIM
(Small Animal Internal
Medicine)

**IMAGING
PERFORMED BY**

Kelly Vazquez

HOSPITAL NAME

Sova Animal Hospital

REFERRING VET

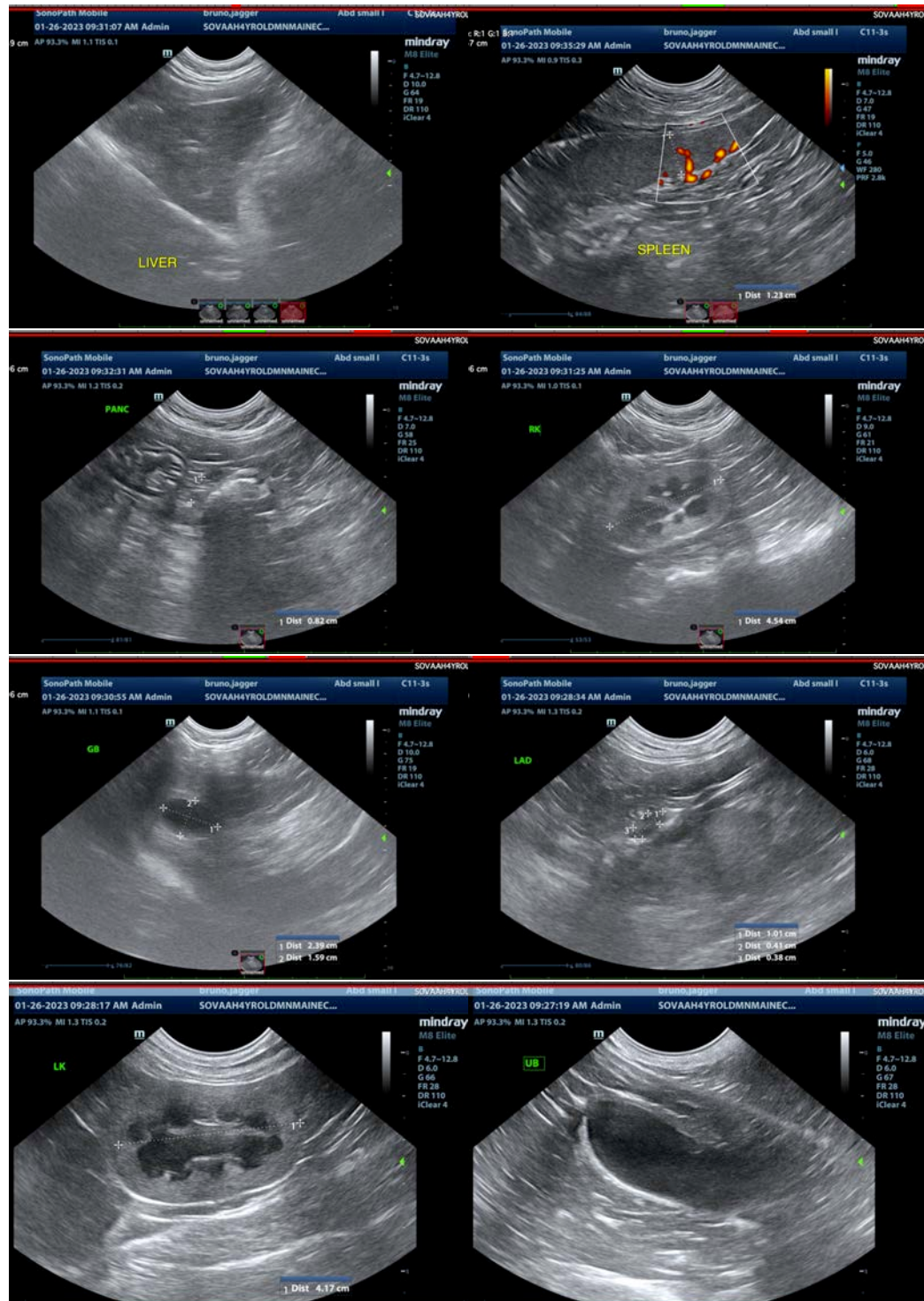
Dr. Robert Sova

INVOICE

44549

DATE

1/26/23





PATIENT

Jagger Bruno

SPECIES

Feline

BREED

Maine Coon

SEX

Neutered Male

AGE

4 Years

WEIGHT

23.8 Pounds

INTERPRETED BY

Kathleen Sennello DVM,
MS, Diplomate ACVIM
(Small Animal Internal
Medicine)

**IMAGING
PERFORMED BY**

Kelly Vazquez

HOSPITAL NAME

Sova Animal Hospital

REFERRING VET

Dr. Robert Sova

INVOICE

44549

DATE

1/26/23

The information and recommendations provided are based on the images presented by the referring veterinarian/sonographer. No evaluation can be communicated regarding pathology that was not visible in the image/video clips provided.

Thank you for this referral. If the clinical or image interpretation does not parallel your findings or if I can be of any further assistance please contact me.

Kathleen Sennello DVM,MS, Diplomate ACVIM (Small animal Internal Medicine)

kathleen.sennello@sonopath.com