



PATIENT

Cody Conlan

SPECIES

Feline

BREED

DSH

SEX

Neutered Male

AGE

9 Years 4 Months

WEIGHT

13.62 Pounds

INTERPRETED BY

Kathleen Sennello DVM,
MS, Diplomate ACVIM
(Small Animal Internal
Medicine)

**IMAGING
PERFORMED BY**

Dr. Rivera

HOSPITAL NAME

DPC Vet Hospital

REFERRING VET

Dr. Rivera

INVOICE

44563

DATE

1/26/23

PRESENTING CLINICAL SIGNS

Reason for Visit: LOOSE STOOL History: 9.5yr old nm dsh presenting for loos stool. O started p on proviable in December for loose stool, everytime o tries to take p off loose stool returns.

Abnormal PE/Chem/CBC/UA Results: CV/Respiratory: Normal heart rate and rhythm, no murmur, pulses strong and synchronous, normal bronchovesicular sounds. EENT: Clear OU and AU. No nasal discharge. No cough on tracheal palpation. Oral cavity: Not examined today Musculoskeletal: BCS = 5/9. Ambulatory x 4 Uro/Perineum: No significant lesions Abd/GI: Soft, non-painful. No masses or fluid wave palpated Lymph Nodes: No peripheral lymphadenopathy Neurological: Alert and appropriate. No significant abnormalities Skin: Sl unkempt hair coat. Flaky skin. No ectoparasites seen Mentation: QAR Hydration: N

ULTRASONOGRAPHIC EXAMINATION OF THE ABDOMEN

Urinary System

The urinary bladder is moderately distended with anechoic urine. The Bladder wall, trigone, ureteral papillae and visible urethra (to a depth of 2cm) appear normal with no evidence of wall thickening, mucosal irregularities, masses or cystic calculi.

The left kidney has a normal shape and size (4.28 cm). Overall echogenicity is normal with adequate corticomedullary distinction and a typical 1:3 cortex:medulla ratio. There is no evidence of focal perinephric inflammation or effusion. There is no evidence of pyelectasia, nephroliths, infarcts or hydroureter. Renal vasculature is normal.

The right kidney has a normal shape and size (4.49 cm). Overall echogenicity is normal with adequate corticomedullary distinction and a typical 1:3 cortex:medulla ratio. There is no evidence of focal perinephric inflammation or effusion. There is no evidence of pyelectasia, nephroliths, infarcts or hydroureter. Renal vasculature is normal.

Adrenal Glands

The region of left adrenal (Cranial to left renal artery) is unremarkable but the adrenal is not distinctly visualized. No evidence of a mass effect is visualized.

The region of the right adrenal (between right cranial kidney and vena cava) is unremarkable, but the adrenal is not distinctly visualized. No evidence of a mass effect is visualized.

Spleen

The spleen is subjectively normal in size, echotexture is homogenous, and the splenic capsule is smooth with no irregularities. The blood flow through the hilus and splenic parenchyma appears normal. No focal parenchymal abnormalities are visualized.

Liver

The liver is subjectively normal in size, and echogenicity with smooth peripheral margins. The parenchyma is homogenous echotexture. The visible portions of the vasculature and biliary tract appear normal. No focal nodules or cystic lesions are observed.

The gallbladder lumen is moderately distended. The wall of the gall bladder is not thickened and has a smooth mucosal surface. Luminal contents are mild and primarily anechoic. The cystic and common bile ducts are normal/not visible.



PATIENT

Cody Conlan

SPECIES

Feline

BREED

DSH

SEX

Neutered Male

AGE

9 Years 4 Months

WEIGHT

13.62 Pounds

INTERPRETED BY

Kathleen Sennello DVM,
MS, Diplomate ACVIM
(Small Animal Internal
Medicine)

IMAGING PERFORMED BY

Dr. Rivera

HOSPITAL NAME

DPC Vet Hospital

REFERRING VET

Dr. Rivera

INVOICE

44563

DATE

1/26/23

Gastrointestinal

The stomach contains minimal luminal contents. It measures at a normal thickness of <0.36cm with some variability due to the presence of rugal folds. The distinction of the gastric wall layers is adequate and there is no impression of reduced peristaltic activity. No masses or focal lesions were observed.

The visualized areas of duodenum, jejunum and ileum have a relatively uniform diameter with mild to moderate fluid distension. Wall thickness is normal. Bowel loops follow a curvilinear path with distinct wall layering maintaining the typical 1:3 muscularis:mucosa layer ratio. Jejunum wall measures 0.22 cm. Visualized peristalsis appears appropriate. There were no focal lesions consistent with obstruction or a mass effect observed.

The ileocecal junction was visualized and exhibited normal intact wall layering and is subjectively of normal thickness. Sections of colon are visualized with formed fecal material and gas shadowing distally. There is no observed focal or generalized colon wall thickening or loss of layering.

Pancreas

The area of the pancreas is normal and isoechoic to surrounding mesentery. There is no evidence of nodules or cystic lesions. There is no evidence of regional mesenteric inflammation or fluid.

Free Abdomen

Evaluation of the peritoneal cavity did not reveal any evidence of effusion, or subjective lymphadenomegaly. The Medial iliac nodes appear normal and there was no evidence of a caudal aortic thrombus at the bifurcation. The omentum is of normal uniform echogenicity.

ULTRASONOGRAPHIC FINDINGS

- Mild diffuse fluid distention of the small intestine – Findings are most consistent with generalized mild ileus.

INTERPRETATION OF THE FINDINGS & FURTHER RECOMMENDATIONS

The changes on today's scan are relatively mild. No obvious mass lesions, lymphadenopathy, etc. are noted. The small bowel does appear somewhat fluid distended. Correlate this with feeding history. If the patient was adequately fasted, this could represent mild ileus secondary to primary gastrointestinal issues. Unfortunately, there are many causes for chronic diarrhea that cannot be diagnosed by ultrasound alone.

Consider such differentials as food allergy/dietary intolerance, GI parasitism, pancreatitis, dysbiosis, recurrent dietary indiscretion, IBD and less likely neoplasia, etc....

- Consider a novel protein/hydrolyzed protein diet (exclusively at least 4-6 weeks)
- Consider a GI panel to Texas A&M for evaluation of B12 levels, folate, PLI/TLI etc.. to further evaluate for pancreatic/small intestinal disease.
- If there is a response to probiotics, consider long-term probiotic therapy.

If probiotic therapy stops working or the patient is persistently not doing well, consider obtaining GI biopsies.

Recommend three view thoracic radiographs to evaluate for possible concurrent thoracic disease/involvement.



PATIENT

Cody Conlan

SPECIES

Feline

BREED

DSH

SEX

Neutered Male

AGE

9 Years 4 Months

WEIGHT

13.62 Pounds

INTERPRETED BY

Kathleen Sennello DVM,
MS, Diplomate ACVIM
(Small Animal Internal
Medicine)

**IMAGING
PERFORMED BY**

Dr. Rivera

HOSPITAL NAME

DPC Vet Hospital

REFERRING VET

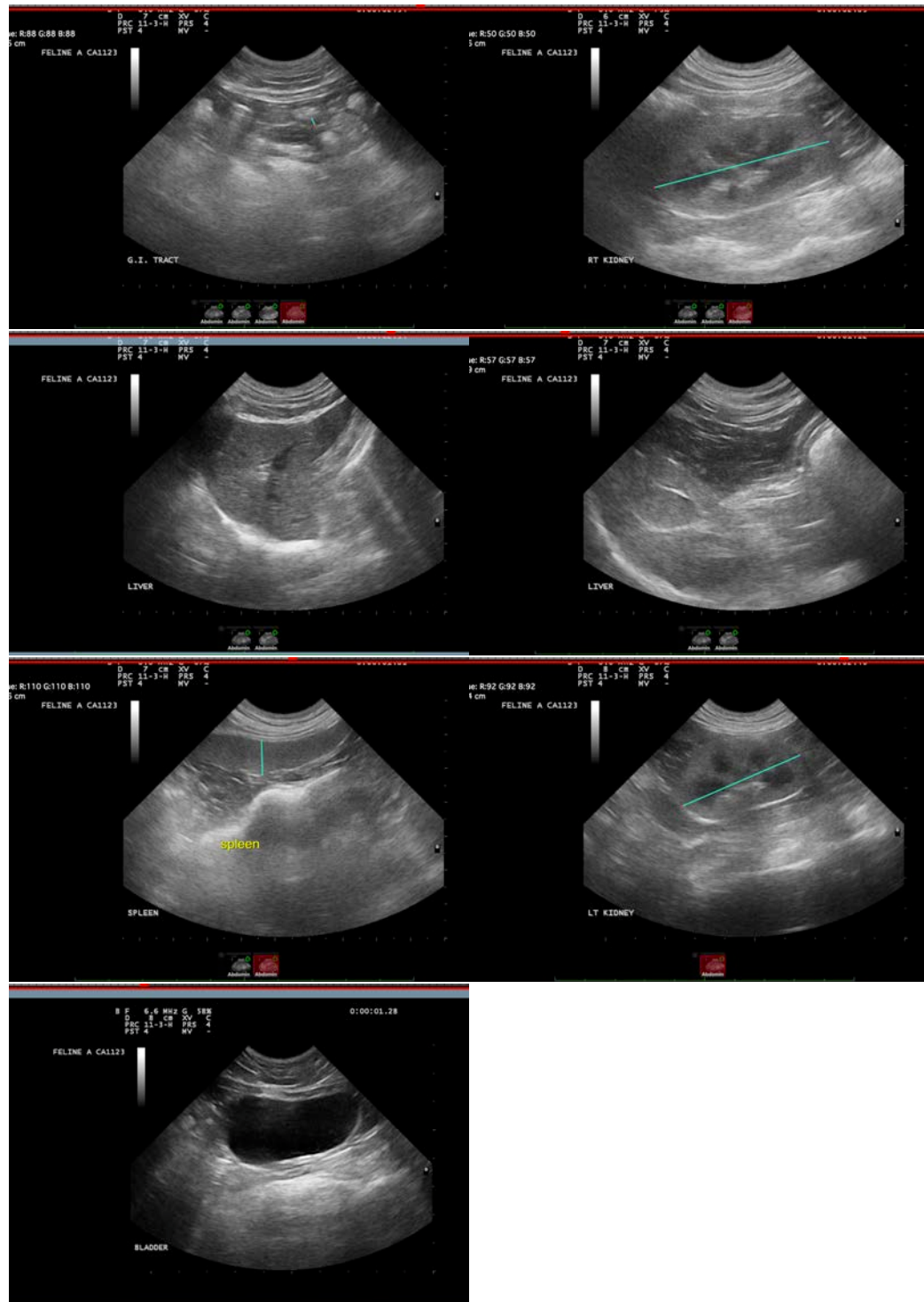
Dr. Rivera

INVOICE

44563

DATE

1/26/23





PATIENT

Cody Conlan

The information and recommendations provided are based on the images presented by the referring veterinarian/sonographer. No evaluation can be communicated regarding pathology that was not visible in the image/video clips provided.

SPECIES

Feline

Thank you for this referral. If the clinical or image interpretation does not parallel your findings or if I can be of any further assistance please contact me.

BREED

DSH

Kathleen Sennello DVM,MS, Diplomate ACVIM (Small animal Internal Medicine)

SEX

Neutered Male

kathleen.sennello@sonopath.com

AGE

9 Years 4 Months

WEIGHT

13.62 Pounds

INTERPRETED BY

Kathleen Sennello DVM,
MS, Diplomate ACVIM
(Small Animal Internal
Medicine)

**IMAGING
PERFORMED BY**

Dr. Rivera

HOSPITAL NAME

DPC Vet Hospital

REFERRING VET

Dr. Rivera

INVOICE

44563

DATE

1/26/23