



PATIENT

Zoey Boyd

SPECIES

Canine

BREED

Havanese X

SEX

Spayed Female

AGE

9 Years

WEIGHT

12 kg

INTERPRETED BY

Kathleen Sennello DVM,
MS, Diplomate ACVIM
(Small Animal Internal
Medicine)

**IMAGING
PERFORMED BY**

Dr. Sandy Jameson

HOSPITAL NAME

Sylvan Lake VC

REFERRING VET

Dr. Sandy Jameson

INVOICE

35108

DATE

1/26/22

PRESENTING CLINICAL SIGNS

Pre-surgical bloodwork prior to COHAT showed mild elevation ALT and ALKP. Pre/Post bile acids were performed in house and post prandial levels were elevated. Proceeded with abd ultrasound to evaluate liver.

ULTRASONOGRAPHIC EXAMINATION OF THE ABDOMEN

Urinary System

The urinary bladder is moderately distended with anechoic urine. The Bladder wall largely appears of normal thickness, but in the apical portion there is a focal irregularity measuring 1.7 cm x 0.68 cm. The area of the trigone, ureteral papillae and visible urethra (to a depth of 2cm) appear normal with no evidence of mass lesion or calculi. Findings are most consistent with a focal bladder mass, but focal cystitis is possible.

The left kidney has a normal shape and size (5.2 cm). Overall echogenicity is normal with adequate corticomedullary distinction and a typical 1:3 cortex:medulla ratio. There is no evidence of perinephric inflammation or effusion. There is no evidence of pyelectasia, nephroliths, infarcts or hydroureter. Renal vasculature is normal.

The right kidney has a normal shape and size (4.0 cm). Overall echogenicity is normal with adequate corticomedullary distinction and a typical 1:3 cortex:medulla ratio. There is no evidence of perinephric inflammation or effusion. There is no evidence of pyelectasia, nephroliths, infarcts or hydroureter. Renal vasculature is normal.

Adrenal Glands

The region of left adrenal (Cranial to left renal artery) is unremarkable but the adrenal is not distinctly visualized. No evidence of a mass effect.

The region of the right adrenal (between right cranial kidney and vena cava) is unremarkable, but the adrenal is not distinctly visualized. No evidence of a mass effect.

Spleen

The spleen is subjectively normal in size, echotexture is homogenous, and the splenic capsule is smooth with no irregularities. The blood flow through the hilus and splenic parenchyma appears normal. No focal parenchymal abnormalities are visualized.

Liver

The liver is subjectively normal in size, and echogenicity with smooth peripheral margins. The parenchyma is heterogenous in echotexture with subtle, indistinct focal mottling. The visible portions of the vasculature and biliary tract appear normal. No focal nodules or cystic lesions are observed.

The gall bladder lumen is moderately distended. The wall of the gall bladder is not thickened and has a smooth mucosal surface. There is largely a moderate amount of non-organized echogenic debris, but early organization near the gallbladder neck is visualized with some mucosal stranding. The cystic and common bile ducts are normal/not visible.

Gastrointestinal

The stomach contains minimal luminal contents. It measures at a normal thickness of <0.7cm with some variability due to the presence of rugal folds. The distinction of the gastric wall layers is adequate and there is no impression of reduced peristaltic activity. No masses or focal lesions were observed.



PATIENT

Zoey Boyd

The visualized areas of duodenum, jejunum and ileum have a relatively uniform diameter with minimal fluid distension. Wall thickness is normal. Bowel loops follow a curvilinear path with distinct wall layering maintaining the typical 1:3 muscularis:mucosa layer ratio. The duodenum measured as normal (between 0.3-0.5cm in wall thickness) and the jejunum measured as normal (between 0.2-0.47cm.) Visualized peristalsis appears appropriate. There were no focal lesions consistent with obstruction or a mass effect observed.

SPECIES

Canine

The ileocecal junction was visualized and exhibited normal intact wall layering and is subjectively of normal thickness. Sections of colon are visualized with formed fecal material and gas shadowing distally. There is no observed focal or generalized colon wall thickening or loss of layering.

BREED

Havanese X

Pancreas

The pancreas is normal and isoechoic to surrounding mesentery. There is no evidence of nodules or cystic lesions. There is no evidence of regional mesenteric inflammation or fluid.

SEX

Spayed Female

Free Abdomen

Evaluation of the peritoneal cavity did not reveal any evidence of effusion, or subjective lymphadenomegaly. The Medial iliac nodes appear normal and there was no evidence of a caudal aortic thrombus at the bifurcation. The omentum is of normal uniform echogenicity.

AGE

9 Years

ULTRASONOGRAPHIC FINDINGS

WEIGHT

12 kg

- Focal irregularity in the bladder wall – Concerning for a possible early mass effect. Focal cystitis is also possible.
- Mildly heterogeneous liver – The diffuse hepatic changes are non-specific and could be consistent with vacuolar hepatopathy, nodular hyperplasia, inflammatory/immune-mediated disease, fibrosis, extramedullary hematopoiesis, toxic hepatopathy (e.g., copper), infiltrative neoplasia (less likely) or other hepatopathy.
- Moderate gallbladder sludge with early organization – The gallbladder wall appears relatively healthy and not inflamed, but there is early mucocele development.

INTERPRETED BY

Kathleen Sennello DVM,
MS, Diplomate ACVIM
(Small Animal Internal
Medicine)

INTERPRETATION OF THE FINDINGS & FURTHER RECOMMENDATIONS

The focal mass in the bladder has the characteristics most consistent with a neoplastic lesion, but polyps and inflammatory lesions can sometimes have a similar appearance. A definitive diagnosis cannot be determined by ultrasound alone.

IMAGING PERFORMED BY

Dr. Sandy Jameson

-Recommend urine evaluation for BRAF mutation seen in patients with transitional cell carcinomas. A positive test is diagnostic, a negative test is inconclusive and will need further diagnostics.

HOSPITAL NAME

Sylvan Lake VC

-If negative or non-diagnostic BRAF consider traumatic catheterization to obtain representative cells for cytology, or biopsy sampling via either cystoscopy (if a female) or surgery.

REFERRING VET

Dr. Sandy Jameson

-Patients with bladder pathology should always have urinalysis and culture performed. Ideally cystocentesis should be avoided in patients with suspected bladder masses to try and prevent tracking of tumor cells along the needle path.

INVOICE

35108

-If TCC is confirmed consider referral to/consultation with a board certified. Veterinary oncologist for recommendations regarding treatment options and prognosis.

DATE

1/26/22



PATIENT

Zoey Boyd

The changes observed in the liver are mild and non-specific. Unfortunately, the severity of the sonographic changes does not always correlate with the severity of the clinical disease present. There is some early gallbladder disease present, but I would be surprised if it was severe enough to be causing a significant bile acids elevation (specific lab work values not provided).

SPECIES

Canine

- Consider close evaluation of history for possible toxic changes examine medications, diet, dietary indiscretion etc...
- Consider PCR on urine/serum for leptospirosis (if not on antibiotics)/serology if recent antibiotic history

BREED

Havanese X

- If not already done, consider pre and post prandial bile acids to evaluate liver function
- If the ALP is significantly elevated relative to the ALT and symptoms consistent with cushings are present, consider adrenal function testing (ACTH stim)
- Consider Fine needle aspirate if round cell neoplasia is on your differentia list (25 g needle, normal coags)

SEX

Spayed Female

- If no response to supportive care (Denamarin +/- antibiotics, +/- ursodiol etc...) Consider liver biopsy with samples obtained for histopathology, culture, and copper levels.
- Recommend continued monitoring of the gallbladder with ultrasound, as this could become a surgical lesion in the future.

AGE

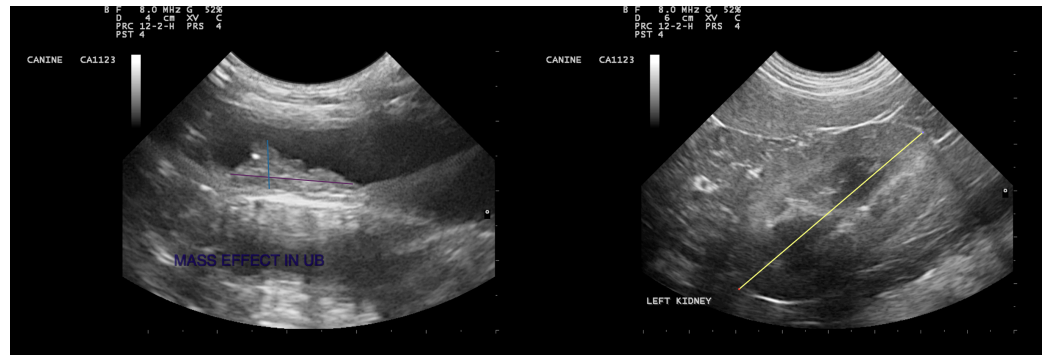
9 Years

WEIGHT

12 kg

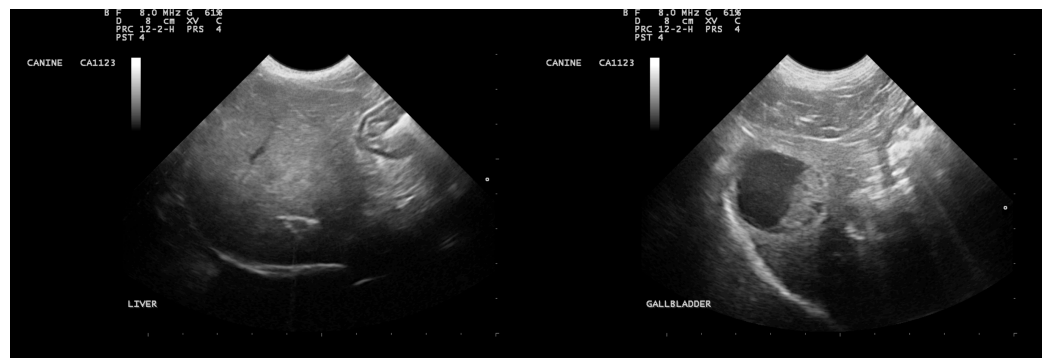
INTERPRETED BY

Kathleen Sennello DVM,
MS, Diplomate ACVIM
(Small Animal Internal
Medicine)



IMAGING PERFORMED BY

Dr. Sandy Jameson



HOSPITAL NAME

Sylvan Lake VC

REFERRING VET

Dr. Sandy Jameson

INVOICE

35108

DATE

1/26/22



PATIENT

Zoey Boyd

SPECIES

Canine

BREED

Havanese X

SEX

Spayed Female

AGE

9 Years

WEIGHT

12 kg

INTERPRETED BY

Kathleen Sennello DVM,
MS, Diplomate ACVIM
(Small Animal Internal
Medicine)

**IMAGING
PERFORMED BY**

Dr. Sandy Jameson

HOSPITAL NAME

Sylvan Lake VC

REFERRING VET

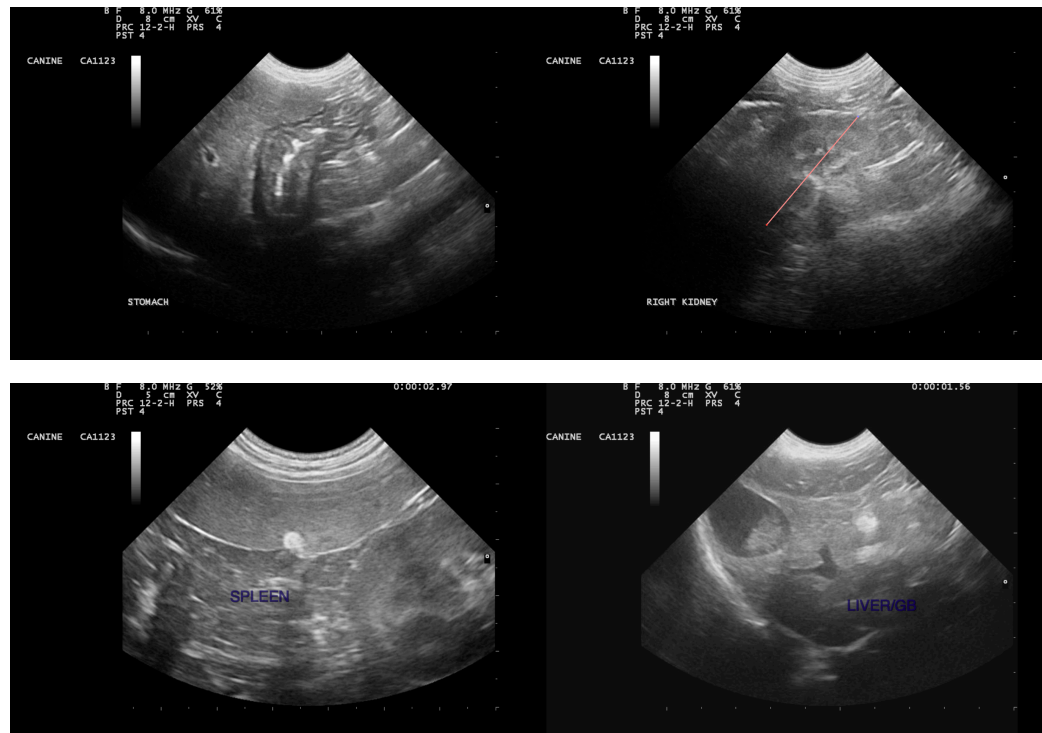
Dr. Sandy Jameson

INVOICE

35108

DATE

1/26/22



The information and recommendations provided are based on the images presented by the referring veterinarian/sonographer. No evaluation can be communicated regarding pathology that was not visible in the image/video clips provided.

Thank you for this referral. If the clinical or image interpretation does not parallel your findings or if I can be of any further assistance please contact me.

Kathleen Sennello DVM,MS, Diplomate ACVIM (Small animal Internal Medicine)

kathleen.sennello@sonopath.com