



PATIENT

Bella Barcan

SPECIES

Canine

BREED

Poodle

SEX

Spayed Female

AGE

12

WEIGHT

33

INTERPRETED BY

Kathleen Sennello DVM,
MS, Diplomate ACVIM
(Small Animal Internal
Medicine)

IMAGING PERFORMED BY

Chelsea Pastor

HOSPITAL NAME

Fredon Animal
Hospital

REFERRING VET

Dr. Linda Grau

INVOICE

44493

DATE

1/25/23

PRESENTING CLINICAL SIGNS

Seen for weight loss October, nsf progressing without other symptoms

Abnormal PE/Chem/CBC/UA Results: Profound wasting, cbc/chem/ua all normal chest rad wnl

ULTRASONOGRAPHIC EXAMINATION OF THE ABDOMEN

Urinary System

The urinary bladder is moderately distended with anechoic urine. The Bladder wall is diffusely mildly thickened (0.46 cm), and the mucosa is mildly irregular. The trigone, ureteral papillae, and visible urethra (to a depth of 2cm) appear normal with no evidence of severe mucosal irregularities, masses or cystic calculi. Findings are most consistent with bacterial cystitis or lack of urine distension. Recommend urinalysis and culture.

The left kidney has a normal shape and size (4.87 cm). Overall echogenicity is slightly hyperechoic with poor corticomedullary distinction and a typical 1:3 cortex:medulla ratio. There is no evidence of focal perinephric inflammation or effusion. There is no evidence of pyelectasia, nephroliths, infarcts or hydroureter. Renal vasculature is normal.

The right kidney has a normal shape and size (4.9 cm). Overall echogenicity is slightly hyperechoic with poor corticomedullary distinction and a typical 1:3 cortex:medulla ratio. There is no evidence of focal perinephric inflammation or effusion. There is no evidence of pyelectasia, nephroliths, infarcts or hydroureter. Renal vasculature is normal.

Adrenal Glands

The left adrenal gland is normal in size measuring 0.50 cm at the caudal pole. It is observed in its normal position cranial to the left renal artery. It is normal in appearance (uniformly hypoechoic) and shape with no evidence of a mass effect.

The region of the right adrenal (between right cranial kidney and vena cava) is unremarkable, but the adrenal is not distinctly visualized. No evidence of a mass effect is visualized.

Spleen

The spleen is subjectively normal in size, echotexture is homogenous, and the splenic capsule is smooth with no irregularities. The blood flow through the hilus and splenic parenchyma appears normal. No focal parenchymal abnormalities are visualized.

Liver

The liver is subjectively large and normal in echogenicity with smooth peripheral margins. The parenchyma is mildly heterogenous in echotexture with subtle, indistinct focal mottling. The visible portions of the vasculature and biliary tract appear normal. No focal nodules or cystic lesions are observed.

The gallbladder lumen is moderately distended. The wall of the gall bladder is not thickened and has a smooth mucosal surface. Luminal contents are mild and primarily anechoic. The cystic and common bile ducts are normal/not visible.



PATIENT

Gastrointestinal

Bella Barcan

The stomach contains minimal luminal contents. It measures at a normal thickness of <0.7cm with some variability due to the presence of rugal folds. The distinction of the gastric wall layers is adequate and there is no impression of reduced peristaltic activity. No masses or focal lesions were observed.

SPECIES

Canine

The visualized areas of duodenum, jejunum and ileum have a relatively uniform diameter with minimal fluid distension. Wall thickness is normal. Bowel loops follow a curvilinear path with distinct wall layering maintaining the typical 1:3 muscularis:mucosa layer ratio. Duodenum wall measures 0.45 cm. Jejunum wall measures 0.42 cm. Visualized peristalsis appears appropriate. There were no focal lesions consistent with obstruction or a mass effect observed.

BREED

Poodle

SEX

Spayed Female

The ileocecal junction was visualized and exhibited normal intact wall layering and is subjectively of normal thickness. Sections of colon are visualized with formed fecal material and gas shadowing distally. There is no observed focal or generalized colon wall thickening or loss of layering.

AGE

Pancreas

12

The area of the pancreas is normal and isoechoic to surrounding mesentery. There is no evidence of nodules or cystic lesions. There is no evidence of regional mesenteric inflammation or fluid.

WEIGHT

Free Abdomen

33

Evaluation of the peritoneal cavity did not reveal any evidence of effusion, or subjective lymphadenomegaly. The Medial iliac nodes appear normal and there was no evidence of a caudal aortic thrombus at the bifurcation. The omentum is of normal uniform echogenicity.

INTERPRETED BY

Kathleen Sennello DVM,
MS, Diplomate ACVIM
(Small Animal Internal
Medicine)

PRIMARY FINDINGS

- Mildly thickened, irregular urinary bladder wall – The bladder mucosal changes could be consistent with cystitis or artifactual due to lack of adequate luminal distension. Bladder neoplasia cannot be ruled out but is considered unlikely in this patient.
- Subjectively large, mildly heterogeneous liver – The diffuse hepatic changes are non-specific and could be consistent with vacuolar hepatopathy, nodular hyperplasia, inflammatory/immune-mediated disease, fibrosis, extramedullary hematopoiesis, toxic hepatopathy (e.g., copper), infiltrative neoplasia (less likely) or other hepatopathy. The significance is uncertain if liver values are normal.

IMAGING PERFORMED BY

Chelsea Pastor

HOSPITAL NAME

Fredon Animal
Hospital

SECONDARY FINDINGS

- Mildly reduced corticomedullary distinction in both kidneys – The bilateral renal findings are consistent with age-related change.

REFERRING VET

Dr. Linda Grau

INVOICE

INTERPRETATION OF THE FINDINGS & FURTHER RECOMMENDATIONS

44493

Today's scan is relatively normal. The abnormalities noted are subjective, and I am unable to definitively attribute them to weight loss described.

DATE

1/25/23

The urinary bladder wall appears slightly thickened and irregular. Recommend a urinalysis and culture.

No large mass lesions are observed. No lymphadenopathy.

Both kidneys have mildly reduced corticomedullary distinction, which is most consistent age related changes. Recommend a blood pressure, urinalysis and culture, and a urine protein to creatinine ratio for further evaluation.



PATIENT

Bella Barcan

SPECIES

Canine

BREED

Poodle

SEX

Spayed Female

AGE

12

WEIGHT

33

INTERPRETED BY

Kathleen Sennello DVM,
MS, Diplomate ACVIM
(Small Animal Internal
Medicine)

**IMAGING
PERFORMED BY**

Chelsea Pastor

HOSPITAL NAME

Fredon Animal
Hospital

REFERRING VET

Dr. Linda Grau

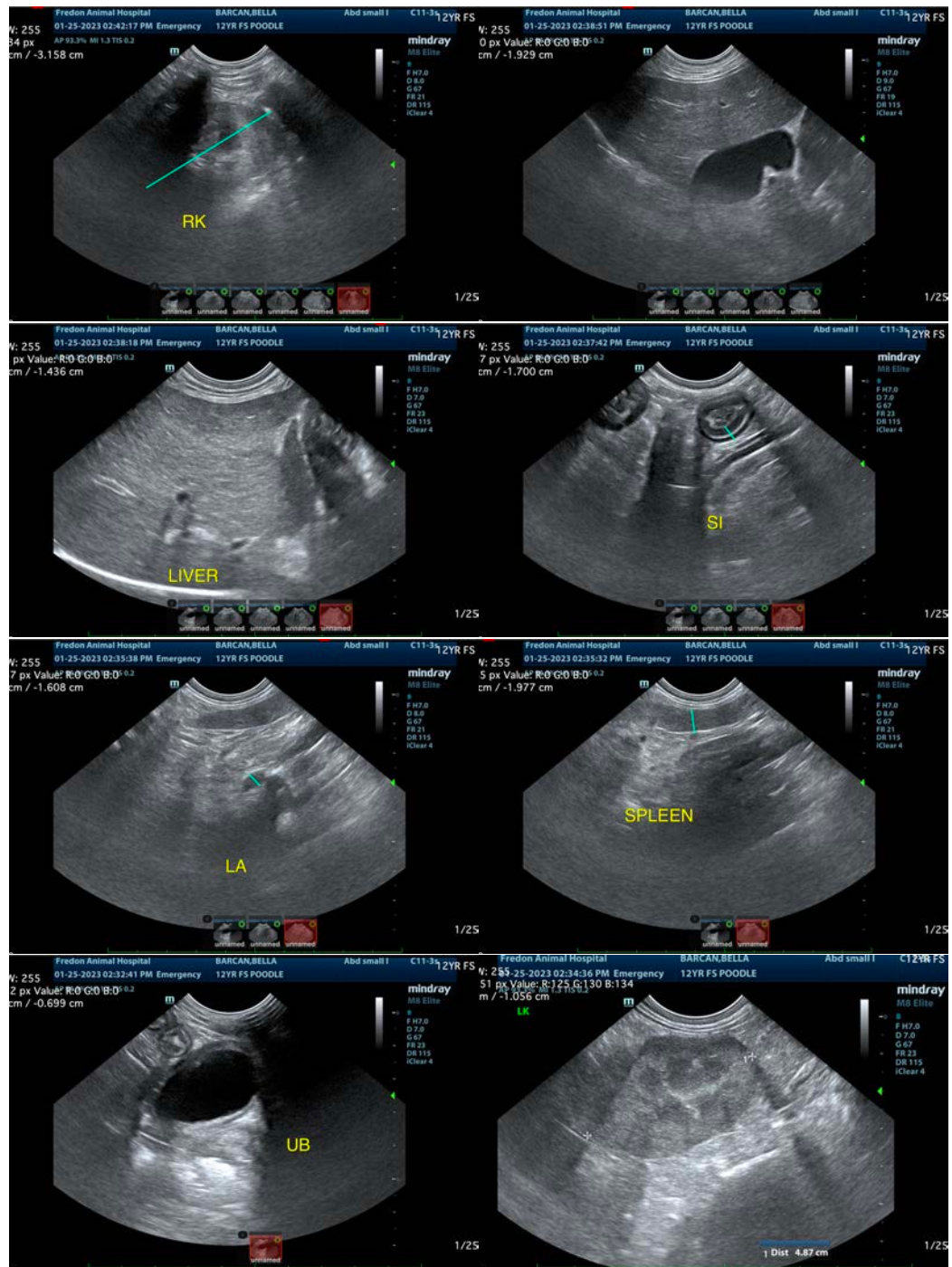
INVOICE

44493

DATE

1/25/23

Recommend quantitating the caloric intake of this patient to confirm adequate nutrition is being taken in. confirm that that stools are firm. You can have significant malabsorption despite no significant ultrasonographic lesions. Consider a GI panel for a quantitative PLI, TLI, cobalamin and folate to Texas A&M GI lab to look for any evidence of underlying GI disease.





PATIENT

Bella Barcan

The information and recommendations provided are based on the images presented by the referring veterinarian/sonographer. No evaluation can be communicated regarding pathology that was not visible in the image/video clips provided.

SPECIES

Canine

Thank you for this referral. If the clinical or image interpretation does not parallel your findings or if I can be of any further assistance please contact me.

BREED

Poodle

Kathleen Sennello DVM,MS, Diplomate ACVIM (Small animal Internal Medicine)

kathleen.sennello@sonopath.com

SEX

Spayed Female

AGE

12

WEIGHT

33

INTERPRETED BY

Kathleen Sennello DVM,
MS, Diplomate ACVIM
(Small Animal Internal
Medicine)

**IMAGING
PERFORMED BY**

Chelsea Pastor

HOSPITAL NAME

Fredon Animal
Hospital

REFERRING VET

Dr. Linda Grau

INVOICE

44493

DATE

1/25/23