



PATIENT

Bear Orr

SPECIES

Canine

BREED

Yorkshire Terrier X

SEX

Neutered Male

AGE

14 Years

WEIGHT

30 Pounds

INTERPRETED BY

Kathleen Sennello DVM,
MS, Diplomate ACVIM
(Small Animal Internal
Medicine)

IMAGING PERFORMED BY

Shari Reffi, CVT

HOSPITAL NAME

Newton Vet Hospital

REFERRING VET

Dr. Barron

INVOICE

44457

DATE

1/25/23

PRESENTING CLINICAL SIGNS

Lethargy, anorexia x 24hours. Potential splenic nodule on abd. rads. Current meds: IVF; Buprenex; Metronidazole iv; Cerenia prn

Abnormal PE/Chem/CBC/UA Results: abn cpl; bun 58.5 (29 H); Glob 4.8 (3.6 H); Lymph 074 (0.83 H)

ULTRASONOGRAPHIC EXAMINATION OF THE ABDOMEN

Urinary System

The urinary bladder is moderately distended with anechoic urine. The Bladder wall, trigone, ureteral papillae and visible urethra (to a depth of 2cm) appear normal with no evidence of wall thickening, mucosal irregularities, masses or cystic calculi.

The prostate is normal in size (1.1 cm) and shape for this neutered male dog. The parenchyma is homogenous and the external margins are smooth. The prostatic urethra appears normal with no evidence of irregularity, invasion, mass effect or calculi.

The left kidney has a normal shape and size (5.61 cm) with numerous small cortical cysts. Overall echogenicity is slightly hyperechoic with poor corticomedullary distinction and a typical 1:3 cortex:medulla ratio. There is no evidence of focal perinephric inflammation or effusion. There is no evidence of pyelectasia, nephroliths, infarcts or hydroureter. Renal vasculature is normal.

The right kidney has a normal shape and size (5.7 cm). Overall echogenicity is normal with adequate corticomedullary distinction and a typical 1:3 cortex:medulla ratio. There is no evidence of focal perinephric inflammation or effusion. There is no evidence of pyelectasia, nephroliths, infarcts or hydroureter. Renal vasculature is normal.

Adrenal Glands

The left adrenal gland is normal in size measuring 0.65 cm at the caudal pole. It is observed in its normal position cranial to the left renal artery. It is normal in appearance (uniformly hypoechoic) and shape with no evidence of a mass effect.

The right adrenal gland is normal in size measuring 0.67 cm at the caudal pole. It is observed in its normal position between the cranial aspect of the right kidney and the caudal vena cava. It is normal in appearance (uniformly hypoechoic) and shape with no evidence of a mass effect.

Spleen

The spleen is large and irregular. The blood flow through the hilus and splenic parenchyma appears normal. There is a focal mixed echogenic mass on the spleen measuring approximately 3.13 cm x 3.0 cm. This mass lesion is surrounded by hyperechoic mesentery and a small amount of free abdominal fluid. Additionally, there is a small hypoechoic nodule visualized measuring 0.70 cm.

Liver

The liver is subjectively normal in size, and echogenicity with smooth peripheral margins. The parenchyma is homogenous echotexture. The visible portions of the vasculature and biliary tract appear normal. No focal nodules or cystic lesions are observed.

The gallbladder lumen is moderately distended. The wall of the gall bladder is not thickened and has a smooth mucosal surface. Luminal contents are mild and primarily anechoic. The cystic and common bile ducts are normal/not visible.



PATIENT

Bear Orr

SPECIES

Canine

BREED

Yorkshire Terrier X

SEX

Neutered Male

AGE

14 Years

WEIGHT

30 Pounds

INTERPRETED BY

Kathleen Sennello DVM,
MS, Diplomate ACVIM
(Small Animal Internal
Medicine)

**IMAGING
PERFORMED BY**

Shari Reffi, CVT

HOSPITAL NAME

Newton Vet Hospital

REFERRING VET

Dr. Barron

INVOICE

44457

DATE

1/25/23

Gastrointestinal

The stomach contains minimal luminal contents. It measures at a normal thickness of <0.7cm with some variability due to the presence of rugal folds. The distinction of the gastric wall layers is adequate and there is no impression of reduced peristaltic activity. No masses or focal lesions were observed.

The visualized areas of duodenum, jejunum and ileum have a relatively uniform diameter with minimal fluid distension. Wall thickness is normal. Bowel loops follow a curvilinear path with distinct wall layering maintaining the typical 1:3 muscularis:mucosa layer ratio. Duodenum wall measures 0.40 cm. Jejunum wall measures 0.31 cm. Visualized peristalsis appears appropriate. There were no focal lesions consistent with obstruction or a mass effect observed.

The ileocecal junction was visualized and exhibited normal intact wall layering and is subjectively of normal thickness. Sections of colon are visualized with formed fecal material and gas shadowing distally. There is no observed focal or generalized colon wall thickening or loss of layering.

Pancreas

The pancreas is normal and isoechoic to surrounding mesentery. There is no evidence of nodules or cystic lesions. There is no evidence of regional mesenteric inflammation or fluid.

Free Abdomen

There is a small amount of free abdominal fluid. No lymphadenopathy. The omentum is hyperechoic around the splenic mass.

Other

A brief view of the heart was submitted. No significant pericardial effusion was seen.

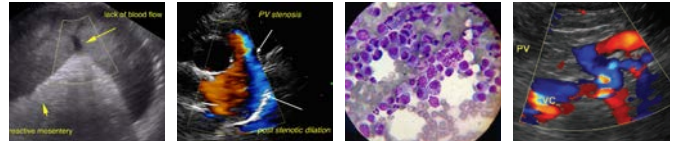
ULTRASONOGRAPHIC FINDINGS

- Mixed echogenic splenic mass with surrounding hyperechoic mesentery and a scant amount of free abdominal fluid – There is a non-cavitated, hypoechoic splenic nodule visualized. Differentials include lymphoid hyperplasia, extramedullary hematopoiesis, infiltrative neoplasia, inflammation, other. Cytology or histopathology would be necessary to get a definitive diagnosis.
- Decreased corticomedullary distinction in both kidneys – The bilateral renal findings are consistent with age-related change.
- Small volume free abdominal fluid

INTERPRETATION OF THE FINDINGS & FURTHER RECOMMENDATIONS

There is a mixed echogenic mass effect visualized on the spleen. This is surrounded by hyperechoic mesentery and a small amount of free abdominal fluid, suspicious for a possible small rupture. Recommend 3-view thoracic radiographs and a splenectomy for both diagnostic and therapeutic purposes.

Changes observed in the kidneys are consistent with chronic age related renal disease. Recommend a blood pressure, urinalysis and culture as a baseline.



PATIENT

Bear Orr

SPECIES

Canine

BREED

Yorkshire Terrier X

SEX

Neutered Male

AGE

14 Years

WEIGHT

30 Pounds

INTERPRETED BY

Kathleen Sennello DVM,
MS, Diplomate ACVIM
(Small Animal Internal
Medicine)

**IMAGING
PERFORMED BY**

Shari Reffi, CVT

HOSPITAL NAME

Newton Vet Hospital

REFERRING VET

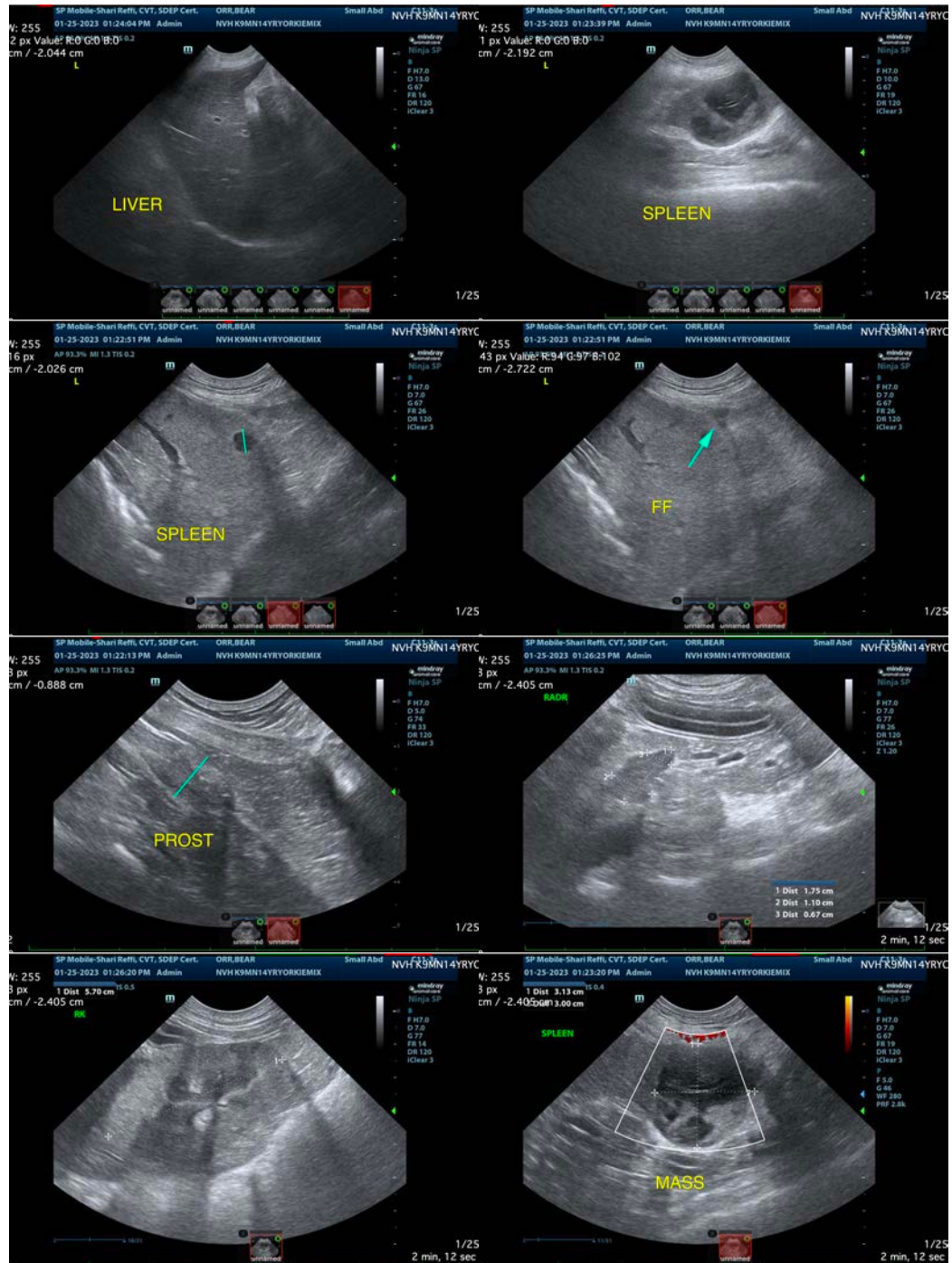
Dr. Barron

INVOICE

44457

DATE

1/25/23





PATIENT

Bear Orr

SPECIES

Canine

BREED

Yorkshire Terrier X

SEX

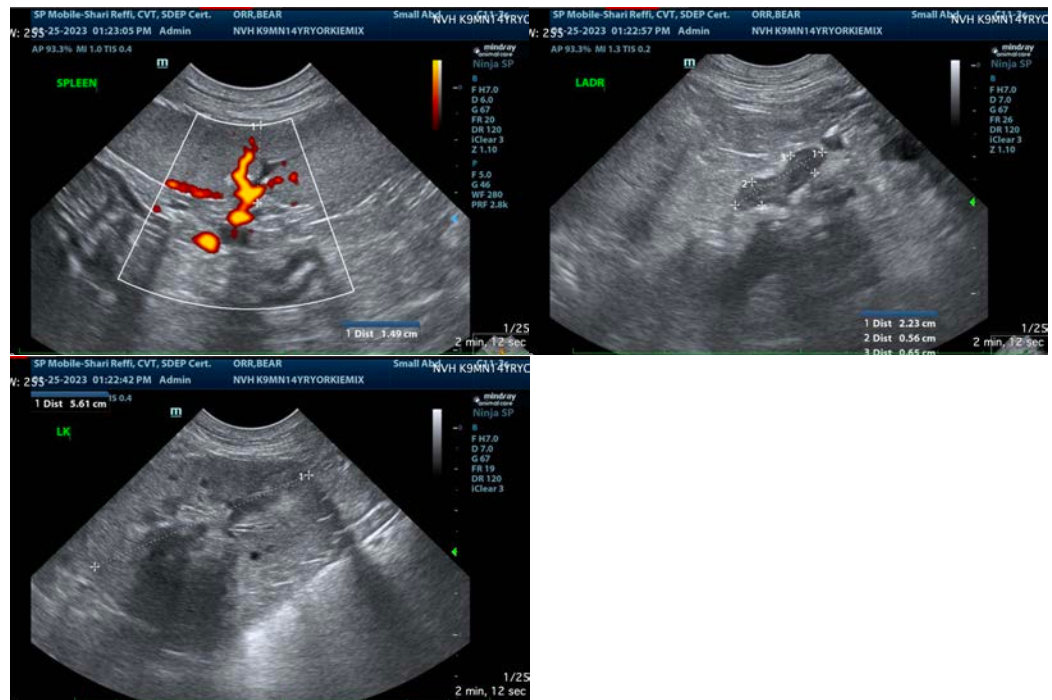
Neutered Male

AGE

14 Years

WEIGHT

30 Pounds



INTERPRETED BY

Kathleen Sennello DVM,
MS, Diplomate ACVIM
(Small Animal Internal
Medicine)

The information and recommendations provided are based on the images presented by the referring veterinarian/sonographer. No evaluation can be communicated regarding pathology that was not visible in the image/video clips provided.

Thank you for this referral. If the clinical or image interpretation does not parallel your findings or if I can be of any further assistance please contact me.

IMAGING PERFORMED BY

Shari Reffi, CVT

Kathleen Sennello DVM,MS, Diplomate ACVIM (Small animal Internal Medicine)

kathleen.sennello@sonopath.com

HOSPITAL NAME

Newton Vet Hospital

REFERRING VET

Dr. Barron

INVOICE

44457

DATE

1/25/23