

**DATE PRESENTING CLINICAL SIGNS**

1/25/22

History: Mast cell tumor screening, diagnosed with mast cell on 01/10, hx previous mast cell excision in 2019.

PATIENT

Date of Previous IntraPet Ultrasound: No previous IntraPet scans.

Spike Rocker

Sedation: Dexdomitor/Torbugesic IM.

Stat Report: Not requested.

SPECIES

Canine

BREED

Pit Bull Terrier X

SEX

Neutered Male

AGE

10/10/13

WEIGHT

90 Pounds

INTERPRETED BYKathleen Sennello DVM,
MS, Diplomate ACVIM
(Small Animal Internal
Medicine)**IMAGING PERFORMED BY**Stephanie Pearce
RDMS, RVT**HOSPITAL NAME**

Perry Hall AH

REFERRING VET

Dr. Baer

INVOICE

35043

ULTRASONOGRAPHIC EXAMINATION OF THE ABDOMEN**Urinary System**

The urinary bladder is moderately distended with anechoic urine. The Bladder wall, trigone, ureteral papillae and visible urethra (to a depth of 2cm) appear normal with no evidence of wall thickening, mucosal irregularities, masses or cystic calculi.

The visualized areas of prostate and surrounding tissue appear normal. Unfortunately, the prostate is not fully visualized likely due to its intrapelvic location. Correlate with rectal exam findings.

The left kidney has a normal shape and size (7.7 cm). Overall echogenicity is normal with adequate corticomedullary distinction and a typical 1:3 cortex:medulla ratio. There is no evidence of perinephric inflammation or effusion. There is no evidence of pyelectasia, nephroliths, infarcts or hydroureter. Renal vasculature is normal.

The right kidney has a normal shape and size (8.24 cm). Overall echogenicity is normal with adequate corticomedullary distinction and a typical 1:3 cortex:medulla ratio. There is no evidence of perinephric inflammation or effusion. There is no evidence of pyelectasia, nephroliths, infarcts or hydroureter. Renal vasculature is normal.

Adrenal Glands

The left adrenal gland is normal in size measuring 0.63 cm at the caudal pole. It is observed in its normal position cranial to the left renal artery. It is normal in appearance (uniformly hypoechoic) and shape with no evidence of a mass effect.

The right adrenal gland is normal in size measuring 0.68 cm at the caudal pole. It is observed in its normal position between the cranial aspect of the right kidney and the caudal vena cava. It is normal in appearance (uniformly hypoechoic) and shape with no evidence of a mass effect.

Spleen

The spleen is subjectively normal in size, echotexture is homogenous, and the splenic capsule is smooth with no irregularities. The blood flow through the hilus and splenic parenchyma appears normal. No focal parenchymal abnormalities are visualized.

Liver

The liver is subjectively normal in size, and echogenicity with smooth peripheral margins. The parenchyma is homogenous echotexture. The visible portions of the vasculature and biliary tract appear normal. No focal nodules or cystic lesions are observed.

The gall bladder lumen is moderately distended. The wall of the gall bladder is not thickened and has a smooth mucosal surface. There is a mild amount of non-organized echogenic debris. The cystic and common bile ducts are normal/not visible.

Gastrointestinal

The stomach contains minimal luminal contents. It measures at a normal thickness of <0.7cm with some variability due to the presence of rugal folds. The distinction of the gastric wall layers is adequate and there is no impression of reduced peristaltic activity. No masses or focal lesions were observed.

The visualized areas of duodenum, jejunum and ileum have a relatively uniform diameter with minimal fluid distension. Wall thickness is normal. Bowel loops follow a curvilinear path with distinct wall layering maintaining the typical 1:3 muscularis:mucosa layer ratio. Jejunum wall measured 0.36 cm. Visualized peristalsis appears appropriate. There were no focal lesions consistent with obstruction or a mass effect observed.

The ileocecal junction was visualized and exhibited normal intact wall layering and is subjectively of normal thickness. Sections of colon are visualized with formed fecal material and gas shadowing distally. There is no observed focal or generalized colon wall thickening or loss of layering.

Pancreas

The pancreas is normal and isoechoic to surrounding mesentery. There is no evidence of nodules or cystic lesions. There is no evidence of regional mesenteric inflammation or fluid.

Free Abdomen

Evaluation of the peritoneal cavity did not reveal any evidence of effusion. There are visible/prominent lymph nodes at the iliac trifurcation, measuring 0.65 cm and 0.45 cm in diameter. the omentum is of normal echogenicity.

PRIMARY FINDINGS

- Prominent/visible iliac lymph nodes – These are not overtly enlarged and could very well be normal in this individual. Recommend continued monitoring.

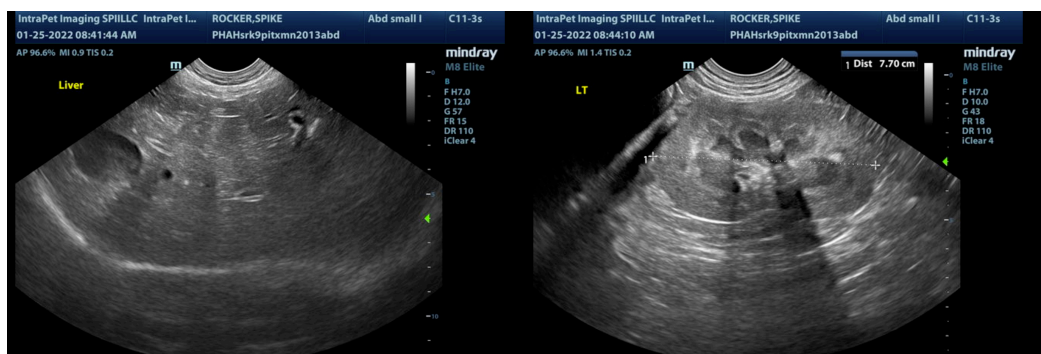
SECONDARY FINDINGS

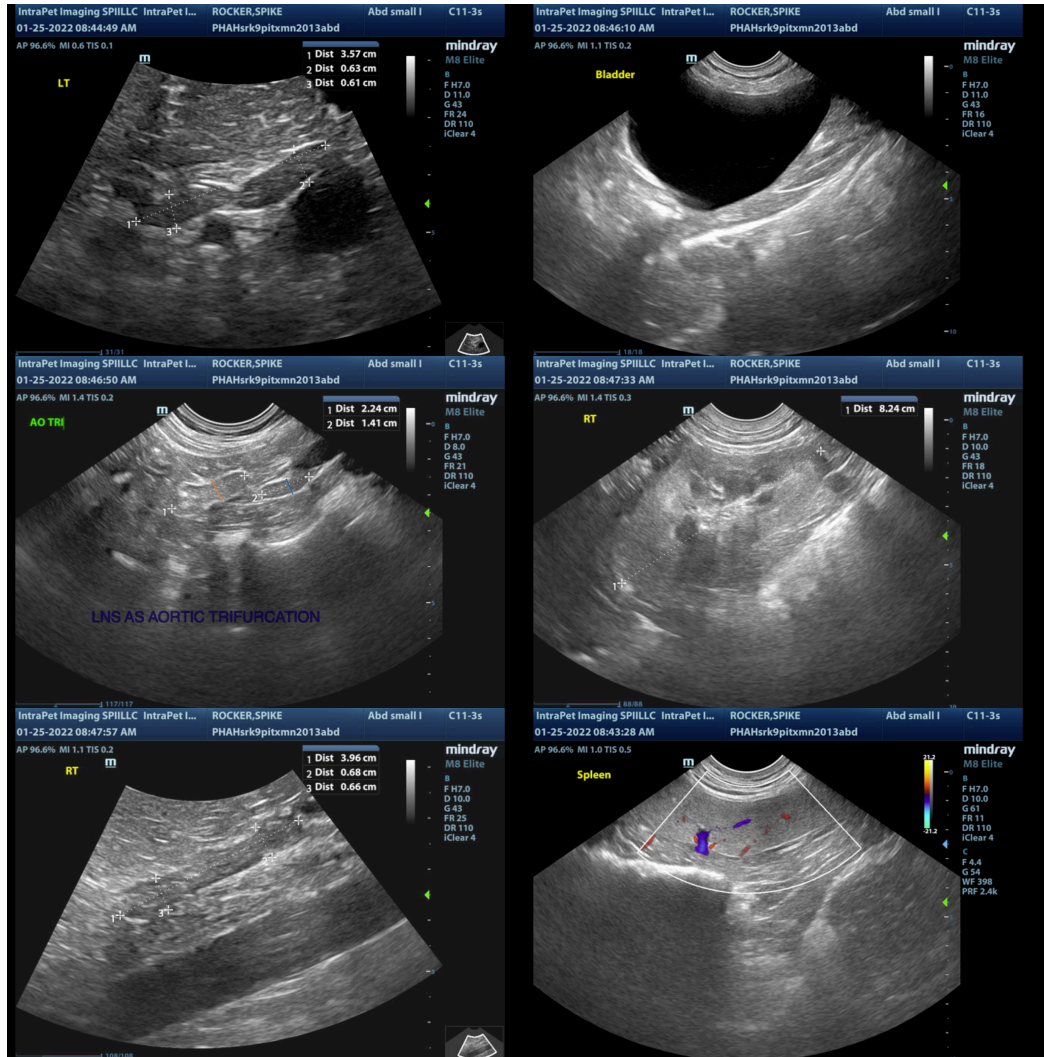
- Mild gallbladder sludge – The significance of the aggregated gallbladder sludge is unclear. This could represent an early mucocele, cholestasis, or may be secondary to fasting.

INTERPRETATION OF THE FINDINGS & FURTHER RECOMMENDATIONS

Today's scan is largely within normal limits. The iliac lymph nodes are visible and slightly prominent, but not overtly enlarged. The location of the mast cell tumor was not listed. This would be of more concern if the lesion is located on a pelvic limb, tail, rectum, etc. Recommend continued monitoring.

There is no evidence of overt metastasis on today's scan.





The information and recommendations provided are based on the images presented by the referring veterinarian/sonographer. No evaluation can be communicated regarding pathology that was not visible in the image/video clips provided.

Thank you for this referral. If the clinical or image interpretation does not parallel your findings or if I can be of any further assistance please contact me.

Kathleen Sennello DVM,MS, Diplomate ACVIM (Small animal Internal Medicine)
 kathleen.sennello@sonopath.com