



PATIENT

Roxie Wynne

PRESENTING CLINICAL SIGNS

Recently diagnosed as diabetic and has some lab abnormalities that may be other issues, but may be attributed to the diabetes. Improved on PU/PD already.

SPECIES

Canine

Abnormal PE/Chem/CBC/UA Results: PE: over weight, Grade II dental disease, few soft subcu masses. Labs: 1/13/23 CBC: Normal Chem: Glucose 433 mg/dL, Creat 1.8 mg/dL, Na 140 mmol/L, Cl 103 mmol/L, Anion Gap 27 mmol/L, TP 8 g/dL, Alb 4.2 g/dL, ALP 1099 U/L, TG 683 mg/dL, Lipase 403 U/L, Creatine Kinase 230 U/L, cPL 505 ug/L HELA- Neg. UA: 1.036, pH 6.5, Protein 30, Glucose 300, clear sediment

BREED

Labrador Retriever
Mix

ULTRASONOGRAPHIC EXAMINATION OF THE ABDOMEN

SEX

FS

Urinary System

The urinary bladder is moderately distended with anechoic urine. The Bladder wall, trigone, ureteral papillae and visible urethra (to a depth of 2cm) appear normal with no evidence of wall thickening, mucosal irregularities, masses or cystic calculi.

AGE

8yr

The left kidney has a normal shape and size (7.2 cm). Overall echogenicity is normal with adequate corticomedullary distinction and a typical 1:3 cortex:medulla ratio. There is no evidence of perinephric inflammation or effusion. There is no evidence of pyelectasia, nephroliths, infarcts or hydroureter. Renal vasculature is normal.

WEIGHT

70lb

The right kidney has a normal shape and size (6.74 cm). Overall echogenicity is normal with adequate corticomedullary distinction and a typical 1:3 cortex:medulla ratio. There is no evidence of perinephric inflammation or effusion. There is no evidence of pyelectasia, nephroliths, infarcts or hydroureter. Renal vasculature is normal.

INTERPRETED BY

Kathleen Sennello DVM,
MS, Diplomate ACVIM
(Small Animal Internal
Medicine)

Adrenal Glands

The left adrenal gland is normal in size measuring 0.93 cm at the caudal pole. It is observed in its normal position cranial to the left renal artery. It is normal in appearance (uniformly hypoechoic) and shape with no evidence of a mass effect.

The right adrenal gland is normal in size measuring 0.81 cm at the caudal pole. It is observed in its normal position between the cranial aspect of the right kidney and the caudal vena cava. It is normal in appearance (uniformly hypoechoic) and shape with no evidence of a mass effect.

IMAGING PERFORMED BY

Carissa Rhoades

Spleen

The spleen is subjectively normal in size, echotexture is homogenous, and the splenic capsule is smooth with no irregularities. The blood flow through the hilus and splenic parenchyma appears normal. No focal parenchymal abnormalities are visualized.

HOSPITAL NAME

Elizabeth Animal
Hospital

Liver

The liver is subjectively large in size with smooth peripheral margins. The parenchyma is hyperechoic and homogenous in echotexture. The visible portions of the vasculature and biliary tract appear normal. No focal nodules or cystic lesions are observed.

REFERRING VET

Dr. Anderson

The gall bladder lumen is moderately distended. The wall of the gall bladder is not thickened and has a smooth mucosal surface. There is a moderate amount of non-organized echogenic debris. The cystic and common bile ducts are normal/not visible.

INVOICE

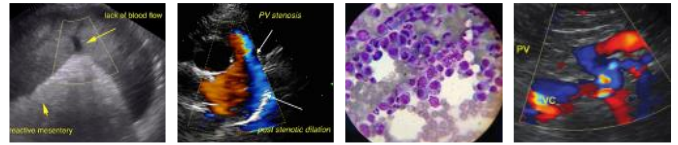
12779ag

Gastrointestinal

The stomach contains minimal luminal contents. It measures at a normal thickness of <0.7cm with some variability due to the presence of rugal folds. The distinction of the gastric wall layers is adequate and there is no impression of reduced peristaltic activity. No masses or focal lesions were observed.

DATE

01/24/2023



PATIENT

Roxie Wynne

SPECIES

Canine

BREED

Labrador Retriever
Mix

SEX

FS

AGE

8yr

WEIGHT

70lb

INTERPRETED BY

Kathleen Sennello DVM,
MS, Diplomate ACVIM
(Small Animal Internal
Medicine)

**IMAGING
PERFORMED BY**

Carissa Rhoades

HOSPITAL NAME

Elizabeth Animal
Hospital

REFERRING VET

Dr. Anderson

INVOICE

12779ag

DATE

01/24/2023

The visualized areas of duodenum, jejunum and ileum have a relatively uniform diameter with minimal fluid distension. Wall thickness is normal. Bowel loops follow a curvilinear path with distinct wall layering maintaining the typical 1:3 muscularis:mucosa layer ratio. The duodenum measured as normal (between 0.3-0.5cm in wall thickness) and the jejunum measured as normal (between 0.2-0.47cm.) Visualized peristalsis appears appropriate. There were no focal lesions consistent with obstruction or a mass effect observed.

The ileocecal junction was visualized and exhibited normal intact wall layering and is subjectively of normal thickness. Sections of colon are visualized with formed fecal material and gas shadowing distally. There is no observed focal or generalized colon wall thickening or loss of layering.

Pancreas

The pancreas is normal and isoechoic to surrounding mesentery. There is no evidence of nodules or cystic lesions. There is no evidence of regional mesenteric inflammation or fluid.

Free Abdomen

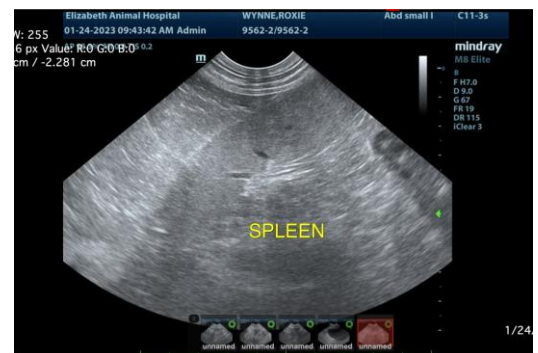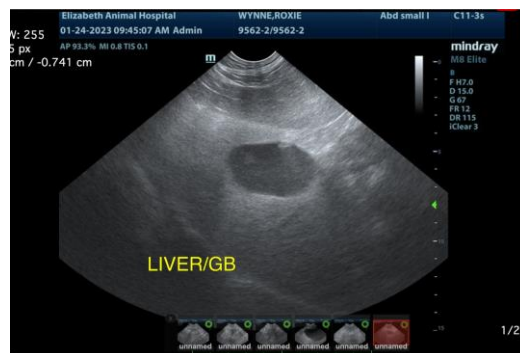Evaluation of the peritoneal cavity did not reveal any evidence of effusion, or subjective lymphadenomegaly. The Medial iliac nodes appear normal and there was no evidence of a caudal aortic thrombus at the bifurcation. The omentum is of normal uniform echogenicity.

ULTRASONOGRAPHIC FINDINGS

- Large hyperechoic liver-the diffuse hepatic changes are non-specific and can be seen with vacuolar hepatopathy, reactive change, nodular hyperplasia or, less likely, inflammatory/immune-mediated disease, infiltrative neoplasia, or other hepatopathy.
- Moderate gallbladder debris-the significance of the aggregated gallbladder debris is unclear. This could represent an early mucocele, cholestasis, or may be secondary to fasting but seems unlikely to be causing a current issue. Recommend continued monitoring.

INTERPRETATION OF THE FINDINGS & FURTHER RECOMMENDATIONS

The changes observed in today's scan are most likely associated with the diagnosed diabetes and possibly diabetic hepatopathy. If symptoms persist despite better regulation or this patient appears insulin resistant, consider further evaluation for underlying Cushing's disease.





PATIENT

Roxie Wynne

SPECIES

Canine

BREED

Labrador Retriever

Mix

SEX

FS

AGE

8yr

WEIGHT

70lb

INTERPRETED BY

Kathleen Sennello DVM,
MS, Diplomate ACVIM
(Small Animal Internal
Medicine)

**IMAGING
PERFORMED BY**

Carissa Rhoades

HOSPITAL NAME

Elizabeth Animal
Hospital

REFERRING VET

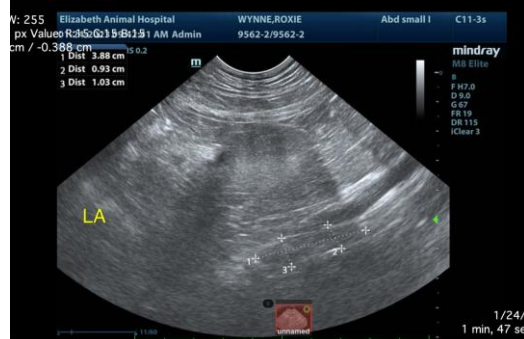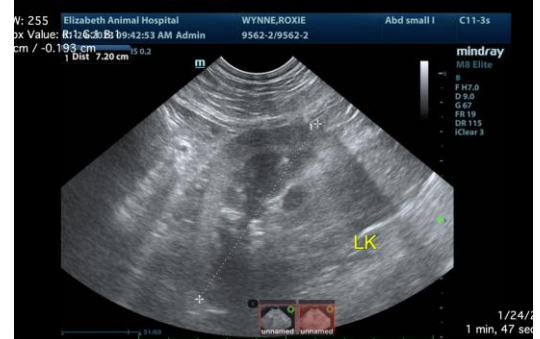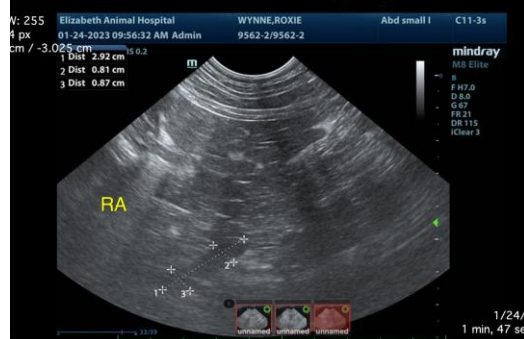
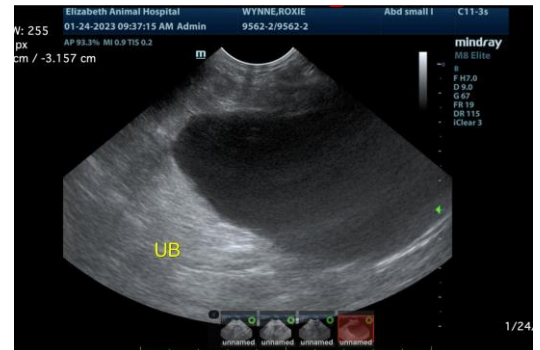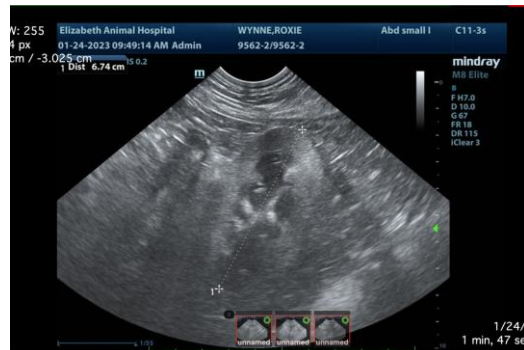Dr. Anderson

INVOICE

12779ag

DATE

01/24/2023



The information and recommendations provided are based on the images presented by the referring veterinarian/sonographer. No evaluation can be communicated regarding pathology that was not visible in the image/video clips provided.

Thank you for this referral. If the clinical or image interpretation does not parallel your findings or if I can be of any further assistance please contact me.

Kathleen Sennello DVM,MS, Diplomate ACVIM (Small animal Internal Medicine)
kathleen.sennello@sonopath.com