



PATIENT

Nellie Bly Kupperman

SPECIES

Feline

BREED

DSH

SEX

Spayed Female

AGE

9 Years

WEIGHT

12.75 Pounds

INTERPRETED BY

Kathleen Sennello DVM,
MS, Diplomate ACVIM
(Small Animal Internal
Medicine)

IMAGING PERFORMED BY

Dr. Lucas Budden

HOSPITAL NAME

Frontier Vet Hospital

REFERRING VET

Dr. Lucas Budden

INVOICE

44466

DATE

1/24/23

PRESENTING CLINICAL SIGNS

History of chronic vomiting. On a weight loss food and has lost weight. Doing well otherwise. Ultrasound to look for cause of chronic vomiting.

Abnormal PE/Chem/CBC/UA Results: PE: overweight (BCS 8/9), no abdominal pain, mild dental tartar, normal exam otherwise 7/1/2022 CBC/chem Slight increased RBC 10.2 rule out mild dehydration Rest of CBC CHEM WNL 1/12/2023 UA USG 1.018 rule out secondary to all canned food diet versus primary renal Rest of urine sediment nsf

ULTRASONOGRAPHIC EXAMINATION OF THE ABDOMEN

Urinary System

The urinary bladder is moderately distended with mild primarily suspended echogenic debris present. The Bladder wall, trigone, ureteral papillae and visible urethra (to a depth of 2cm) appear normal with no evidence of wall thickening, mucosal irregularities, masses or calculi. Echogenic debris of this type can be associated with small crystals, cellular debris and proteinaceous debris.

The left kidney has a normal shape and size (3.88 cm). Overall echogenicity is normal with adequate corticomedullary distinction and a typical 1:3 cortex:medulla ratio. There is no evidence of focal perinephric inflammation or effusion. There is no evidence of pyelectasia, nephroliths, infarcts or hydroureter. Renal vasculature is normal.

The right kidney has a normal shape and size (4.38 cm). Overall echogenicity is normal with adequate corticomedullary distinction and a typical 1:3 cortex:medulla ratio. There is no evidence of focal perinephric inflammation or effusion. There is no evidence of pyelectasia, nephroliths, infarcts or hydroureter. Renal vasculature is normal.

Adrenal Glands

The left adrenal gland is normal in size measuring 0.31 cm at the caudal pole. It is observed in its normal position cranial to the left renal artery. It is normal in appearance (uniformly hypoechoic) and shape with no evidence of a mass effect.

The right adrenal gland is normal in size measuring 0.37 cm at the caudal pole. It is observed in its normal position between the cranial aspect of the right kidney and the caudal vena cava. It is normal in appearance (uniformly hypoechoic) and shape with no evidence of a mass effect.

Spleen

The spleen is subjectively normal in size (0.82 cm), echotexture is homogenous, and the splenic capsule is smooth with no irregularities. The blood flow through the hilus and splenic parenchyma appears normal. No focal parenchymal abnormalities are visualized.

Liver

The liver is subjectively normal in size, and echogenicity with smooth peripheral margins. The parenchyma is homogenous echotexture. The visible portions of the vasculature and biliary tract appear normal. No focal nodules or cystic lesions are observed.

The gallbladder lumen is moderately distended. The wall of the gall bladder is not thickened and has a smooth mucosal surface. Luminal contents are mild and primarily anechoic. The cystic and common bile ducts are normal/not visible.



PATIENT

Gastrointestinal

Nellie Bly Kupperman

The stomach contains minimal luminal contents. It measures at a normal thickness of <0.36cm with some variability due to the presence of rugal folds. The distinction of the gastric wall layers is adequate and there is no impression of reduced peristaltic activity. No masses or focal lesions were observed.

SPECIES

Feline

The visualized areas of duodenum, jejunum and ileum have a uniform diameter with minimal fluid distension. Wall thickness is normal to slightly increased. Bowel loops follow a typical curvilinear path with distinct wall layering, but some areas display a prominent muscularis layer which does not display the typical 1:3 muscularis:mucosa layer ratio. Jejunum wall measures 0.27 cm. Visualized peristalsis appears appropriate. There were no focal lesions consistent with obstruction or a mass effect observed.

BREED

DSH

SEX

Spayed Female

The ileocecal junction was visualized and exhibited normal intact wall layering and is subjectively of normal thickness. Sections of colon are visualized with formed fecal material and gas shadowing distally. There is no observed focal or generalized colon wall thickening or loss of layering.

AGE

9 Years

Pancreas

The pancreas is prominent and hypoechoic as compared to the surrounding isoechoic mesentery. There is no evidence of nodules or cystic lesions. There is no evidence of regional mesenteric inflammation or fluid.

WEIGHT

12.75 Pounds

Free Abdomen

Evaluation of the peritoneal cavity did not reveal any evidence of effusion, or subjective lymphadenomegaly. The Medial iliac nodes appear normal and there was no evidence of a caudal aortic thrombus at the bifurcation. The omentum is of normal uniform echogenicity.

INTERPRETED BY

Kathleen Sennello DVM,
MS, Diplomate ACVIM
(Small Animal Internal
Medicine)

ULTRASONOGRAPHIC FINDINGS

- Echogenic debris in the urinary bladder – The echogenic debris in the bladder lumen could be consistent with cells, crystals, and/or mucus.
- Prominent, hypoechoic pancreas – The pancreatic changes are most consistent with age-related parenchymal remodeling, potentially secondary to a prior inflammatory episode, early fibrosis or chronic pancreatitis.
- Prominent muscularis layer to the small intestine – The small intestinal wall changes could be consistent with an underlying inflammatory process. These types of changes can sometimes be seen in normal older cats. Correlate with clinical signs.

IMAGING PERFORMED BY

Dr. Lucas Budden

HOSPITAL NAME

Frontier Vet Hospital

REFERRING VET

Dr. Lucas Budden

INTERPRETATION OF THE FINDINGS & FURTHER RECOMMENDATIONS

INVOICE

44466

The lesions observed on today's scan are mild and subjective. No focal lesions are observed associated with the gastrointestinal tract to explain the vomiting reported. There is some mild prominent of the muscularis layer, which can be an indicator of underlying small intestinal disease, although this can be a normal finding in some older cats.

DATE

1/24/23

Consider such differentials as food allergy/dietary intolerance, GI parasitism, chronic pancreatitis, IBD and less likely neoplasia, etc..

- Consider a novel protein/hydrolyzed protein diet (exclusively at least 4-6 weeks)



PATIENT

Nellie Bly Kupperman

- Consider a GI panel to Texas A&M for evaluation of B12 levels, folate, PLI/TLI etc.. to further evaluate for pancreatic/small intestinal disease.

SPECIES

Feline

- Recommend chronic probiotic therapy.
- If symptoms persist, recommend obtaining GI biopsies.

BREED

DSH

SEX

Spayed Female

AGE

9 Years

WEIGHT

12.75 Pounds

INTERPRETED BY

Kathleen Sennello DVM,
MS, Diplomate ACVIM
(Small Animal Internal
Medicine)

IMAGING

PERFORMED BY

Dr. Lucas Budden

HOSPITAL NAME

Frontier Vet Hospital

REFERRING VET

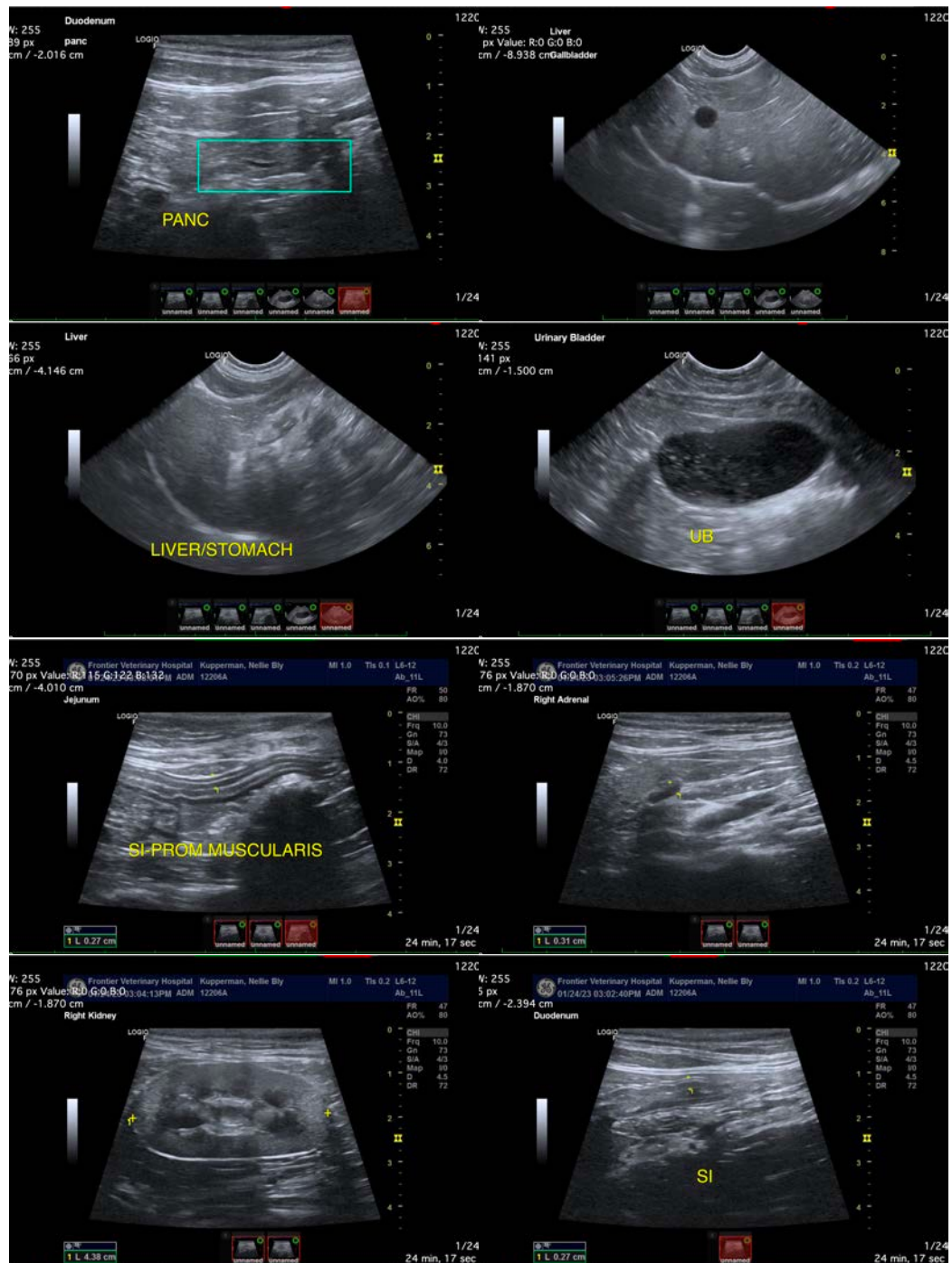
Dr. Lucas Budden

INVOICE

44466

DATE

1/24/23





PATIENT

Nellie Bly Kupperman

SPECIES

Feline

BREED

DSH

SEX

Spayed Female

AGE

9 Years

WEIGHT

12.75 Pounds

INTERPRETED BY

Kathleen Sennello DVM,
MS, Diplomate ACVIM
(Small Animal Internal
Medicine)

IMAGING PERFORMED BY

Dr. Lucas Budden

HOSPITAL NAME

Frontier Vet Hospital

REFERRING VET

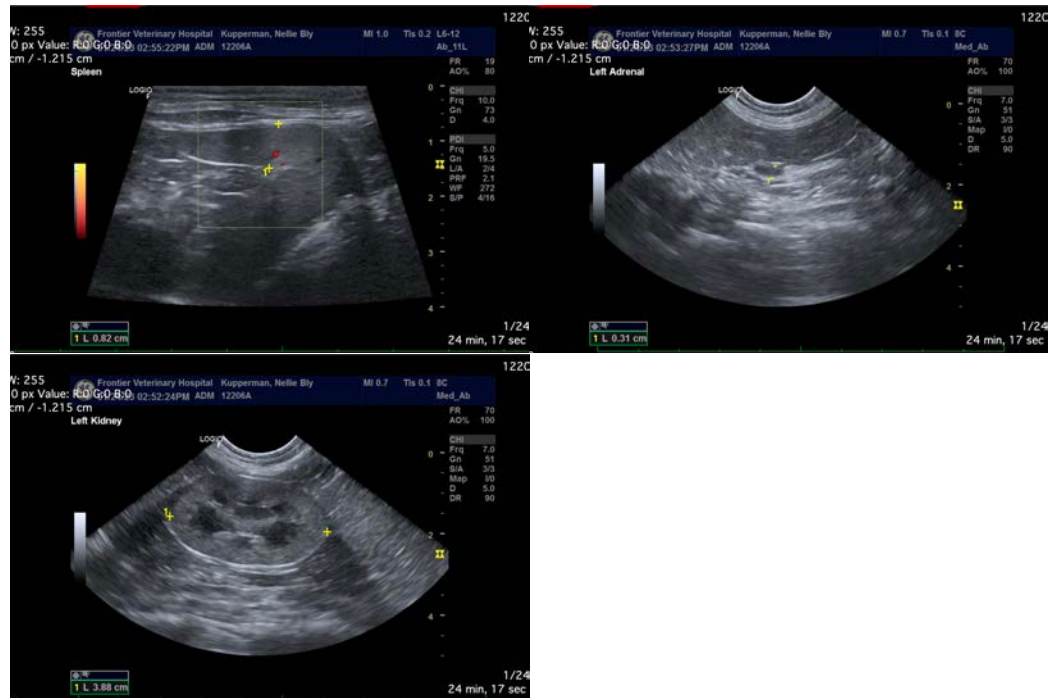
Dr. Lucas Budden

INVOICE

44466

DATE

1/24/23



The information and recommendations provided are based on the images presented by the referring veterinarian/sonographer. No evaluation can be communicated regarding pathology that was not visible in the image/video clips provided.

Thank you for this referral. If the clinical or image interpretation does not parallel your findings or if I can be of any further assistance please contact me.

Kathleen Sennello DVM,MS, Diplomate ACVIM (Small animal Internal Medicine)

kathleen.sennello@sonopath.com