



DATE PRESENTING CLINICAL SIGNS

1/23/26 **Patient History:** Neuter on 12/18/2025. Right testicle cryptorchid and diagnosed seminoma. AUS requested for staging. Also diagnosed hypothyroid

PATIENT

Otis Wohlfort

SPECIES

Canine

BREED

Golden Retriever

SEX

Neutered Male

AGE

11/2/20

WEIGHT

75 lbs

INTERPRETED BY

Kathleen Sennello DVM,
MS, Diplomate ACVIM
(Small Animal Internal
Medicine)

HOSPITAL NAME

Hickory Veterinary
Hospital

REFERRING VET

Dr. Silcox

INVOICE

72414

Current Medications: L-Thyroxine 0.7mg BID.

Labwork Results: Diagnostics attached, reported as: Right testicle: Seminoma. Mitotic count (per 2.37 sq mm): Greater than 15. Histologic tumor-free margins: Clear; Neoplastic cells are not present in the proximal spermatic cord margin. Vascular invasion: Not present

Date of Previous IntraPet Ultrasound: No previous.

Sedation: Not required to complete full diagnostic ultrasound.

Stat Report: Not requested.

Imaging Performed by: Rachel Brillhart, RDMS.

ULTRASONOGRAPHIC EXAMINATION OF THE ABDOMEN

Urinary System

The urinary bladder is moderately distended with anechoic urine. The Bladder wall, trigone, ureteral papillae and visible urethra (to a depth of 2cm) appear normal with no evidence of wall thickening, mucosal irregularities, masses or cystic calculi.

The prostate is prominent/borderline large and mottled, measuring 2.42 cm x 4.61 cm. There are occasional pinpoint mineralizations, the largest of which measures 0.33 cm.

The left kidney has a normal shape and size (7.25 cm) with occasional pinpoint cortical mineralizations. Overall echogenicity is slightly hyperechoic with mildly reduced corticomedullary distinction and a typical 1:3 cortex:medulla ratio. There is no evidence of focal perinephric inflammation or effusion. There is no evidence of pyelectasia, infarcts or hydroureter. Renal vasculature is normal.

The right kidney has a normal shape and size (6.5 cm) with occasional pinpoint cortical mineralizations. Overall echogenicity is slightly hyperechoic with mildly reduced corticomedullary distinction and a typical 1:3 cortex:medulla ratio. There is no evidence of focal perinephric inflammation or effusion. There is no evidence of pyelectasia, infarcts or hydroureter. Renal vasculature is normal.

Adrenal Glands

The left adrenal gland is normal in size measuring 0.58 cm at the cranial pole and 0.70 cm at the caudal pole. It is observed in its normal position cranial to the left renal artery. It is normal in appearance (uniformly hypoechoic) and shape with no evidence of a mass effect.

The right adrenal gland is normal in size measuring 0.57 cm at the cranial pole and 0.52 cm at the caudal pole. It is observed in its normal position between the cranial aspect of the right kidney and the caudal vena cava. It is normal in appearance (uniformly hypoechoic) and shape with no evidence of a mass effect.

Spleen

The spleen is subjectively normal in size (1.81 cm), echotexture is homogenous, and the splenic capsule is smooth with no irregularities. The blood flow through the hilus and splenic parenchyma appears normal. No focal parenchymal abnormalities are visualized.

Liver

The liver is subjectively normal in size, and echogenicity with smooth peripheral margins. The parenchyma is homogenous echotexture. The visible portions of the vasculature and biliary tract appear normal. No focal nodules or cystic lesions are observed.

The gall bladder lumen is moderately distended. The wall of the gall bladder is not thickened and has a smooth mucosal surface. There is a moderate amount of non-organized echogenic debris. The cystic and common bile ducts are normal/not visible.

Gastrointestinal

The stomach contains minimal luminal contents. It measures at a normal thickness of <0.7cm with some variability due to the presence of rugal folds. The distinction of the gastric wall layers is adequate and there is no impression of reduced peristaltic activity. No masses or focal lesions were observed.

The visualized areas of duodenum, jejunum and ileum have a relatively uniform diameter with minimal fluid distension. Wall thickness is normal. Bowel loops follow a curvilinear path with distinct wall layering maintaining the typical 1:3 muscularis:mucosa layer ratio. Jejunum wall measures 0.31 cm. Visualized peristalsis appears appropriate. There were no focal lesions consistent with obstruction or a mass effect observed.

Sections of colon are visualized with formed fecal material and gas shadowing distally. There is no observed focal or generalized colon wall thickening or loss of layering.

Pancreas

The pancreas is normal and isoechoic to surrounding mesentery. There is no evidence of nodules or cystic lesions. There is no evidence of regional mesenteric inflammation or fluid.

Free Abdomen

Evaluation of the peritoneal cavity did not reveal any evidence of effusion. There is no significant lymphadenopathy. An isoechoic iliac lymph node is somewhat prominent measuring 0.46 cm x 1.54 cm. The omentum is mildly increased in echogenicity (consistent with a post-operative patient).

ULTRASONOGRAPHIC FINDINGS

- Prominent, mottled prostate with pinpoint mineralizations – Findings are likely consistent with an involuting prostate with previous hyperplasia. The significance of the mineralization is uncertain.
- Mildly reduced corticomedullary distinction and pinpoint mineralizations visualized associated with both kidneys – Findings could be normal for this individual or consistent with mild age related change.
- Moderate gallbladder debris – The significance of the aggregated gallbladder debris is unclear. This could represent an early mucocele, cholestasis, or may be secondary to fasting but seems unlikely to be causing a current issue. Recommend continued monitoring.
- Prominent isoechoic iliac lymph node – Findings are most consistent with a reactive lymph node.

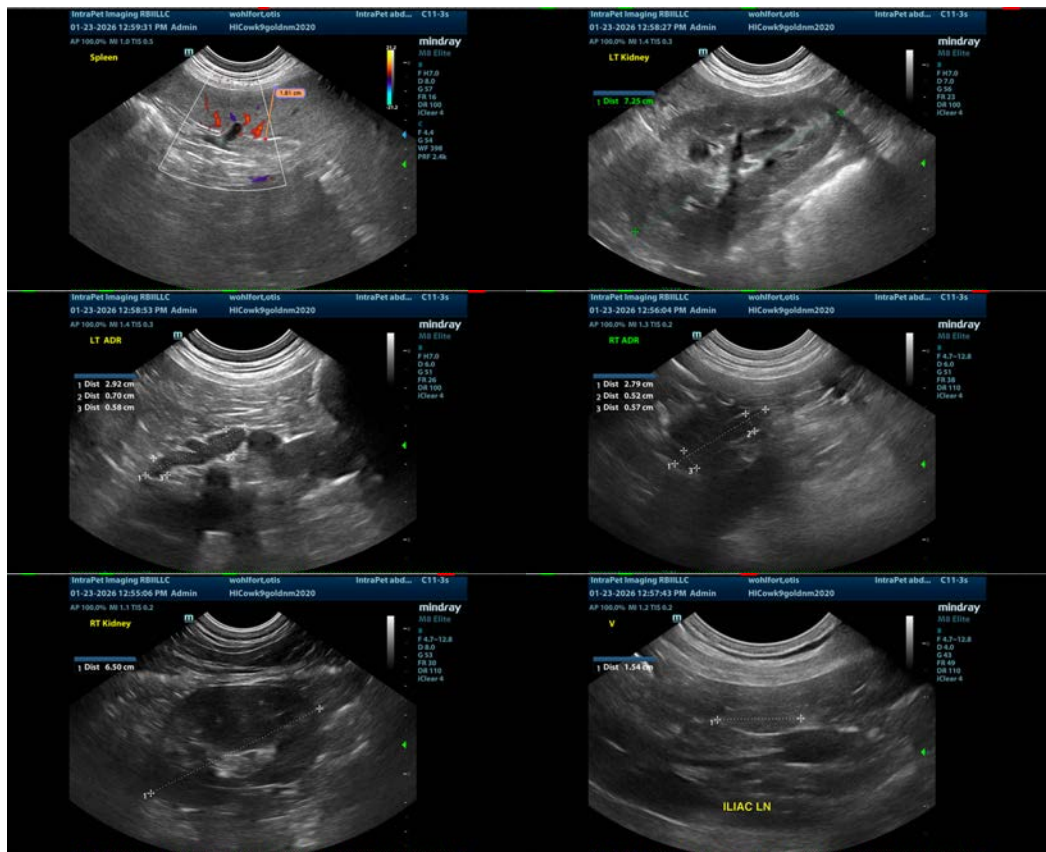
INTERPRETATION OF THE FINDINGS & FURTHER RECOMMENDATIONS

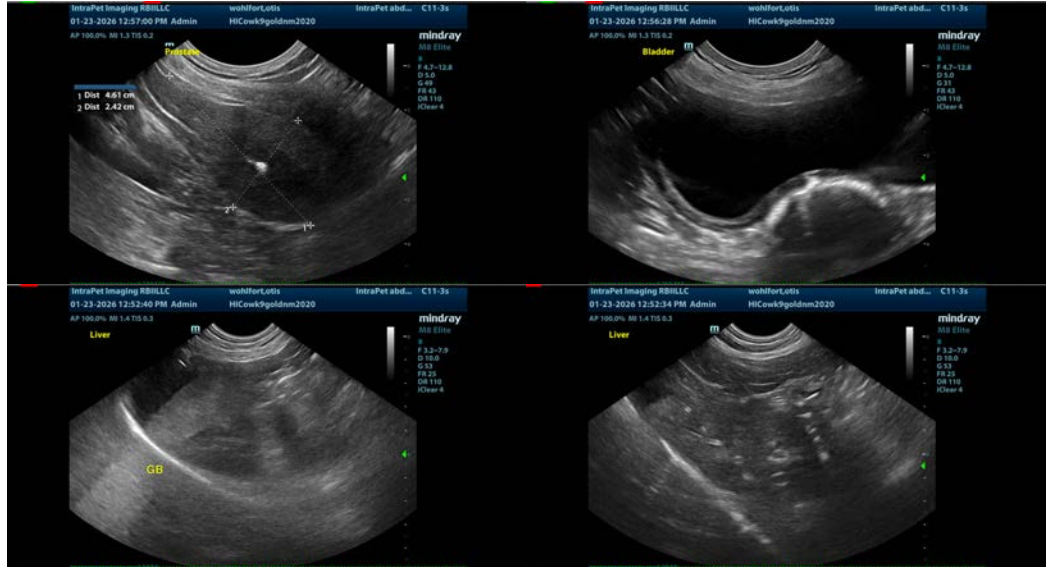
The prostate is borderline large and mottled with pinpoint mineralizations. Findings are likely consistent with an involuting prostate with previous inflammatory disease causing the mineralizations, less likely underlying concurrent prostatic neoplasia. Recommend continued monitoring of the prostate. If it appears to be enlarging or changing in a way that is concerning, a fine needle aspirate should be considered.

The renal changes are mild and non-specific. Correlate with urine concentrating ability and renal values (currently normal).

There is moderate debris in the gallbladder with no evidence of wall thickening or surrounding inflammation. Options would include continued monitoring +/- chronic Ursodiol therapy.

No evidence of metastatic disease is visualized on today's exam.





The information and recommendations provided are based on the images presented by the referring veterinarian/sonographer. No evaluation can be communicated regarding pathology that was not visible in the image/video clips provided.

Thank you for this referral. If the clinical or image interpretation does not parallel your findings or if I can be of any further assistance please contact me.

Kathleen Sennello DVM,MS, Diplomate ACVIM (Small animal Internal Medicine)
info@sonopath.com