



## PATIENT

Simba Kelsey

## SPECIES

Feline

## BREED

Domestic Shorthair

## SEX

Male

## AGE

11 Years

## WEIGHT

9.9 lbs

## INTERPRETED BY

Kathleen Sennello DVM,  
MS, Diplomate ACVIM  
(Small Animal Internal  
Medicine)

## IMAGING PERFORMED BY

Danielle Shemanski,  
DVM, MA

## HOSPITAL NAME

Western New York  
Veterinary Services

## REFERRING VET

Morgan Busby, DVM

## INVOICE

72346

## DATE

1/21/26

## PRESENTING CLINICAL SIGNS

RDVM REASON FOR REFERRAL: Checking for neoplasia, ongoing weight loss, hypercalcemia.

PTH and PTHrP are normal. Radiographs showed no evidence of masses. No change in appetite or attitude. All lab work besides calcium and phosphorus was within normal limits. Previous diagnosis of chronic kidney disease stage 2.

MEDICATIONS: None

Abnormal PE/Chem/CBC/UA Results: SDMA: 15 ug/dL - Phosphorus: 2.5 mg/dL (low) - Calcium: 12.3 mg/dL (high) - Urine specific gravity: 1.018 - Urine red cells: >50/hpf (as of last month)

## ULTRASONOGRAPHIC EXAMINATION OF THE ABDOMEN

### Urinary System

The urinary bladder is moderately distended with anechoic urine. The Bladder wall, trigone, ureteral papillae and visible urethra (to a depth of 2cm) appear normal with no evidence of wall thickening, mucosal irregularities, masses or cystic calculi.

The left kidney is small and irregular in shape with decreased corticomedullary distinction. The left kidney measures 3.42 cm. Minimal normal architecture present. The cortex is increased in echogenicity.

The right kidney has a normal shape and size (4.41 cm) with significant pyelectasia at 0.54 cm. The cortex is increased in echogenicity, with poor corticomedullary distinction and a typical 1:3 cortex:medulla ratio. There is no evidence of focal perinephric inflammation or effusion. There is no evidence of nephroliths, infarcts or hydroureter. Renal vasculature is normal.

### Adrenal Glands

The left adrenal gland is normal in size measuring 0.41 cm at the caudal pole. It is observed in its normal position cranial to the left renal artery. It is normal in appearance (uniformly hypoechoic) and shape with no evidence of a mass effect.

The right adrenal gland is normal in size measuring 0.37 cm at the caudal pole. It is observed in its normal position between the cranial aspect of the right kidney and the caudal vena cava. It is normal in appearance (uniformly hypoechoic) and shape with no evidence of a mass effect.

### Spleen

The spleen is subjectively normal in size (1.0 cm), echotexture is homogenous, and the splenic capsule is smooth with no irregularities. The blood flow through the hilus and splenic parenchyma appears normal. No focal parenchymal abnormalities are visualized.

### Liver

The liver is subjectively normal in size, and echogenicity with smooth peripheral margins. The parenchyma is homogenous echotexture. The visible portions of the vasculature and biliary tract appear normal. No focal nodules or cystic lesions are observed.



## PATIENT

Simba Kelsey

## SPECIES

Feline

## BREED

Domestic Shorthair

## SEX

Male

## AGE

11 Years

## WEIGHT

9.9 lbs

## INTERPRETED BY

Kathleen Sennello DVM,  
MS, Diplomate ACVIM  
(Small Animal Internal  
Medicine)

## IMAGING PERFORMED BY

Danielle Shemanski,  
DVM, MA

## HOSPITAL NAME

Western New York  
Veterinary Services

## REFERRING VET

Morgan Busby, DVM

## INVOICE

72346

## DATE

1/21/26

The gallbladder has a bilobed presentation. The gall bladder lumens are moderately distended. The wall of the gall bladder is not thickened and has a smooth mucosal surface. Luminal contents are mild and likely incidental at this time. The cystic and common bile ducts are normal/not visible.

### ***Gastrointestinal***

The stomach contains minimal luminal contents. It measures at a normal thickness of <0.36cm with some variability due to the presence of rugal folds. The distinction of the gastric wall layers is adequate and there is no impression of reduced peristaltic activity. There are some areas of prominent hyperechoic rugal folding possibly consistent with mild mucosal ulceration/erosions.

The visualized areas of duodenum, jejunum and ileum have a relatively uniform diameter with minimal fluid distension. Wall thickness is normal. Bowel loops follow a curvilinear path with distinct wall layering maintaining the typical 1:3 muscularis:mucosa layer ratio. Duodenum wall measures 0.27 cm. Jejunum wall measures 0.22 cm. Visualized peristalsis appears appropriate. There were no focal lesions consistent with obstruction or a mass effect observed.

Sections of colon are visualized with formed fecal material and gas shadowing distally. There is no observed focal or generalized colon wall thickening or loss of layering.

### ***Pancreas***

The area of the pancreas is normal and isoechoic to surrounding mesentery. There is no evidence of nodules or cystic lesions. There is no evidence of regional mesenteric inflammation or fluid.

### ***Free Abdomen***

Evaluation of the peritoneal cavity did not reveal any evidence of effusion, or subjective lymphadenomegaly. The Medial iliac nodes appear normal and there was no evidence of a caudal aortic thrombus at the bifurcation. The omentum is of normal uniform echogenicity.

### ***Other***

There is a small focal defect in the abdominal wall measuring approximately 0.50 cm with hyperechoic tissue passing through, most consistent with a body wall hernia containing fat.

### **ULTRASONOGRAPHIC FINDINGS**

- Bilateral renal changes consistent with chronic renal disease and significant left-sided pyelectasia – Pyelectasia of the kidney(s) could be consistent with pyelonephritis, chronic renal disease, secondary to PU/PD or fluid therapy (if applicable), other.
- Questionable gastric mucosal erosions.
- Small body wall hernia containing fat.
- Bilobed gallbladder – This is likely an incidental finding.

### **INTERPRETATION OF THE FINDINGS & FURTHER RECOMMENDATIONS**

The appearance of both kidneys is consistent with chronic renal disease. If not already done, recommend a blood pressure, urinalysis, culture +/- a urine protein to creatinine ratio.



## PATIENT

Simba Kelsey

No focal mass lesions, significant lymphadenopathy, etc. are observed. Depending on your clinical assessment, therapy for idiopathic hypercalcemia could be considered (PTH level should typically be low or possibly low-normal).

## SPECIES

Feline

Recommendations would vary wildly depending on the specifics of the case and patient. If ionized calcium levels are mildly elevated, dietary therapy would be the initial plan with a canned diet. Depending on the patient, options could include a high fiber diet or a renal diet with fiber supplementation added, or even a calcium oxalate stone prevention diet, although this individual may benefit from a low protein diet.

## BREED

Domestic Shorthair

If clinical suspicion for gastric ulcerations is present, then your plan for ulcer therapy is good.

## SEX

Male

For an additional charge an internal medicine consult can be utilized through [Sonopath.com](http://sonopath.com). You can select the internal medicine drop down at <http://spa.sonopath.com/>.

## AGE

11 Years

One of the world's top internists & SonoPath associate Dr. Remo Lobetti BVSc, MMedVet, PhD, DECVIM can evaluate your case through SonoPath. <https://sonopath.com/resources/sonopath-services/internal-medicine-teleconsultation-services>

## WEIGHT

9.9 lbs

## INTERPRETED BY

Kathleen Sennello DVM,  
MS, Diplomate ACVIM  
(Small Animal Internal  
Medicine)

## IMAGING PERFORMED BY

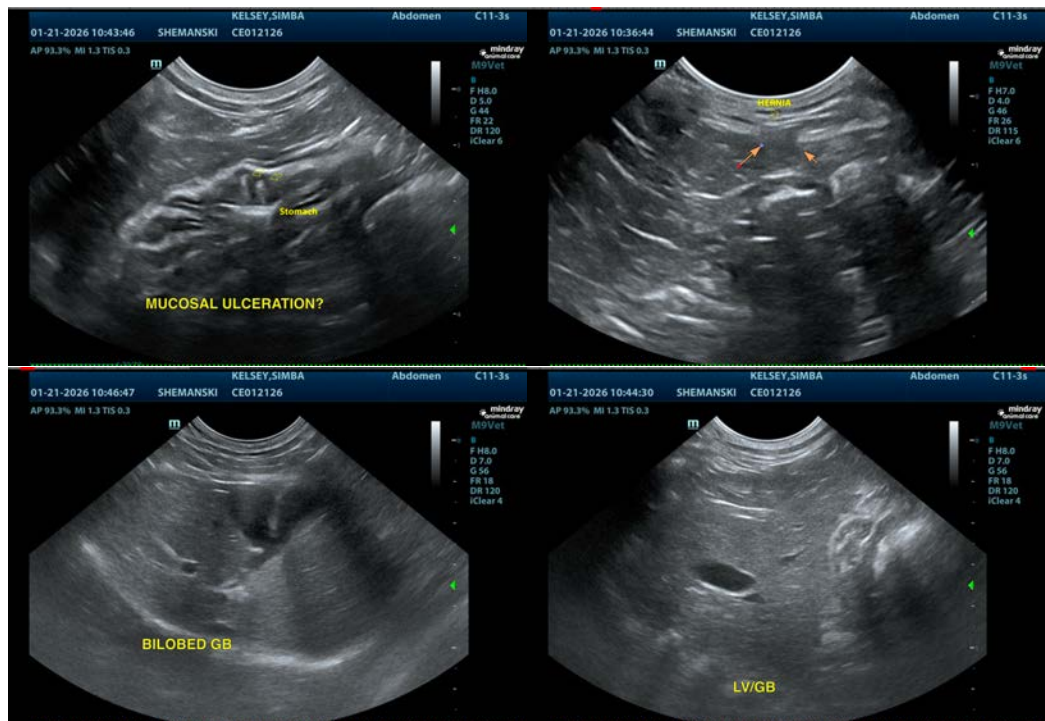
Danielle Shemanski,  
DVM, MA

## HOSPITAL NAME

Western New York  
Veterinary Services

## REFERRING VET

Morgan Busby, DVM



## INVOICE

72346

## DATE

1/21/26



**PATIENT**

Simba Kelsey

**SPECIES**

Feline

**BREED**

Domestic Shorthair

**SEX**

Male

**AGE**

11 Years

**WEIGHT**

9.9 lbs

**INTERPRETED BY**

Kathleen Sennello DVM,  
MS, Diplomate ACVIM  
(Small Animal Internal  
Medicine)

**IMAGING  
PERFORMED BY**

Danielle Shemanski,  
DVM, MA

**HOSPITAL NAME**

Western New York  
Veterinary Services

**REFERRING VET**

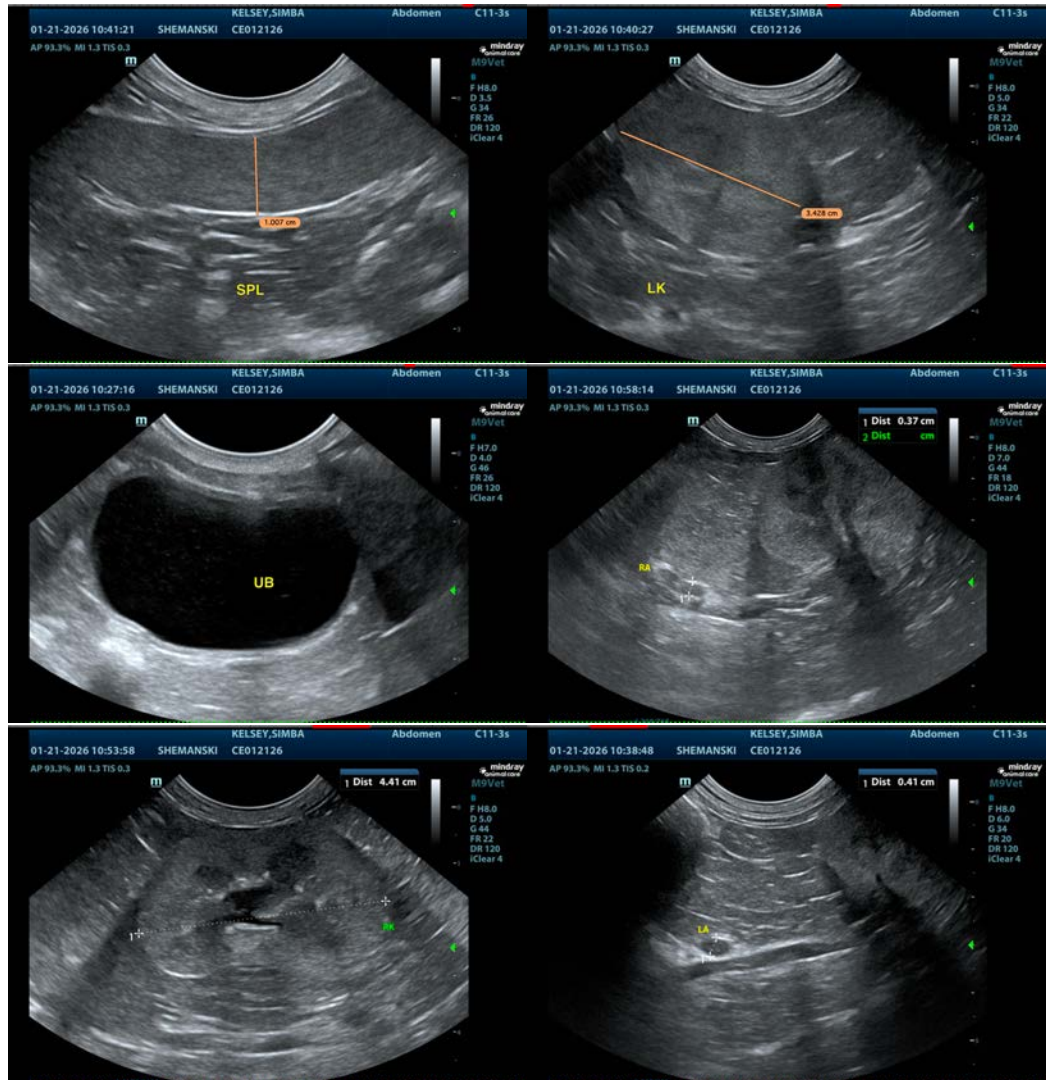
Morgan Busby, DVM

**INVOICE**

72346

**DATE**

1/21/26



The information and recommendations provided are based on the images presented by the referring veterinarian/sonographer. No evaluation can be communicated regarding pathology that was not visible in the image/video clips provided.

Thank you for this referral. If the clinical or image interpretation does not parallel your findings or if I can be of any further assistance please contact me.

Kathleen Sennello DVM,MS, Diplomate ACVIM (Small animal Internal Medicine)

info@sonopath.com