



PATIENT

Max Banner

SPECIES

Canine

BREED

Great Pyrenees

SEX

Neutered Male

AGE

10 Years

WEIGHT

106.3 lbs

INTERPRETED BY

Kathleen Sennello DVM,
MS, Diplomate ACVIM
(Small Animal Internal
Medicine)

IMAGING PERFORMED BY

Meghan Morse, LVT,
CVT

HOSPITAL NAME

All Animal Veterinary
Services

REFERRING VET

Dr. Acworth

INVOICE

72336

DATE

1/21/26

PRESENTING CLINICAL SIGNS

Past 2 days not eating, some days eating than not. Discussed possible stomach ulcers vs tumor in liver.

Current meds: Famotidine 20mg 1tab SID

Abnormal PE/Chem/CBC/UA Results: TP low, ALT high

ULTRASONOGRAPHIC EXAMINATION OF THE ABDOMEN

Urinary System

The urinary bladder is moderately distended with anechoic urine. The Bladder wall, trigone, ureteral papillae and visible urethra (to a depth of 2cm) appear normal with no evidence of wall thickening, mucosal irregularities, masses or cystic calculi.

The visualized areas of prostate and surrounding tissue appear normal. Unfortunately, the prostate is not fully visualized likely due to its intrapelvic location. Correlate with rectal exam findings.

The left kidney has a normal shape and size (6.86 cm). Overall echogenicity is normal with adequate corticomedullary distinction and a typical 1:3 cortex:medulla ratio. There is no evidence of focal perinephric inflammation or effusion. There is no evidence of pyelectasia, nephroliths, infarcts or hydroureter. Renal vasculature is normal.

The right kidney has a normal shape and size (7.91 cm). Overall echogenicity is normal with adequate corticomedullary distinction and a typical 1:3 cortex:medulla ratio. There is no evidence of focal perinephric inflammation or effusion. There is no evidence of pyelectasia, nephroliths, infarcts or hydroureter. Renal vasculature is normal.

Adrenal Glands

The left adrenal gland is "plump" measuring 1.13 cm at the cranial pole and 0.98 cm at the caudal pole. It is observed in its normal position cranial to the left renal artery. It is normal in appearance (uniformly hypoechoic) and shape with no evidence of a mass effect.

The right adrenal gland is "plump" measuring 0.79 cm at the cranial pole and 1.04 cm at the caudal pole. It is observed in its normal position between the cranial aspect of the right kidney and the caudal vena cava. It is normal in appearance (uniformly hypoechoic) and shape with no evidence of a mass effect.

Spleen

The spleen is subjectively normal in size (2.93 cm), echotexture is homogenous, and the splenic capsule is smooth with no irregularities. The blood flow through the hilus and splenic parenchyma appears normal. No focal parenchymal abnormalities are visualized.

Liver

The liver is subjectively normal in size, and echogenicity with smooth peripheral margins. The parenchyma is mildly heterogenous in echotexture with subtle, indistinct focal mottling. The visible portions of the vasculature and biliary tract appear normal. No focal nodules or cystic lesions are observed.



PATIENT

Max Banner

The gall bladder lumen is moderately distended. The wall of the gall bladder is not thickened and has a smooth mucosal surface. Luminal contents are mild and likely incidental at this time. The cystic and common bile ducts are normal/not visible.

SPECIES

Canine

Gastrointestinal

The stomach is difficult to fully visualize in this deep chested dog. No pathology is noted in the region of the stomach.

BREED

Great Pyrenees

The visualized areas of duodenum, jejunum and ileum have a relatively uniform diameter with minimal fluid distension. Wall thickness is normal. Bowel loops follow a curvilinear path with distinct wall layering maintaining the typical 1:3 muscularis:mucosa layer ratio. Duodenum wall measures 0.40 cm. Jejunum wall measures 0.33 cm. Visualized peristalsis appears appropriate. There were no focal lesions consistent with obstruction or a mass effect observed.

SEX

Neutered Male

Sections of colon are visualized with formed fecal material and gas shadowing distally. There is no observed focal or generalized colon wall thickening or loss of layering.

AGE

10 Years

Pancreas

The area of the pancreas is normal and isoechoic to surrounding mesentery. There is no evidence of nodules or cystic lesions. There is no evidence of regional mesenteric inflammation or fluid.

WEIGHT

106.3 lbs

Free Abdomen

Evaluation of the peritoneal cavity did not reveal any evidence of effusion, or subjective lymphadenomegaly. The Medial iliac nodes appear normal and there was no evidence of a caudal aortic thrombus at the bifurcation. The omentum is of normal uniform echogenicity.

INTERPRETED BY

Kathleen Sennello DVM,
 MS, Diplomate ACVIM
 (Small Animal Internal
 Medicine)

ULTRASONOGRAPHIC FINDINGS

- Borderline “plump” adrenal glands – This could be consistent with anatomic variation (big dog) or mild hyperplasia.
- Mildly heterogeneous liver – The diffuse hepatic changes are non-specific and could be consistent with vacuolar hepatopathy, nodular hyperplasia, inflammatory/immune-mediated disease, fibrosis, extramedullary hematopoiesis, toxic hepatopathy (e.g., copper), infiltrative neoplasia (less likely) or other hepatopathy.

IMAGING PERFORMED BY

Meghan Morse, LVT,
 CVT

INTERPRETATION OF THE FINDINGS & FURTHER RECOMMENDATIONS

The changes observed on today’s scan are mild and non-specific. No focal lesions are visualized associated with the liver or the GI tract to explain the symptoms described.

HOSPITAL NAME

All Animal Veterinary
 Services

Depending on the degree of ALT elevation, further evaluation could include the following:

REFERRING VET

Dr. Acworth

- Pre- and post-prandial bile acids to assess liver function.
- Screening for Leptospirosis.
- Fine needle aspirate of the liver (provided coagulation parameters are normal).

INVOICE

72336

DATE

1/21/26

If the ALT elevation is chronic and progressive and/or liver function is abnormal, a biopsy of the liver with samples for histopathology, culture and copper levels may be warranted.



PATIENT

Max Banner

SPECIES

Canine

BREED

Great Pyrenees

SEX

Neutered Male

AGE

10 Years

WEIGHT

106.3 lbs

INTERPRETED BY

Kathleen Sennello DVM,
MS, Diplomate ACVIM
(Small Animal Internal
Medicine)

IMAGING PERFORMED BY

Meghan Morse, LVT,
CVT

HOSPITAL NAME

All Animal Veterinary
Services

REFERRING VET

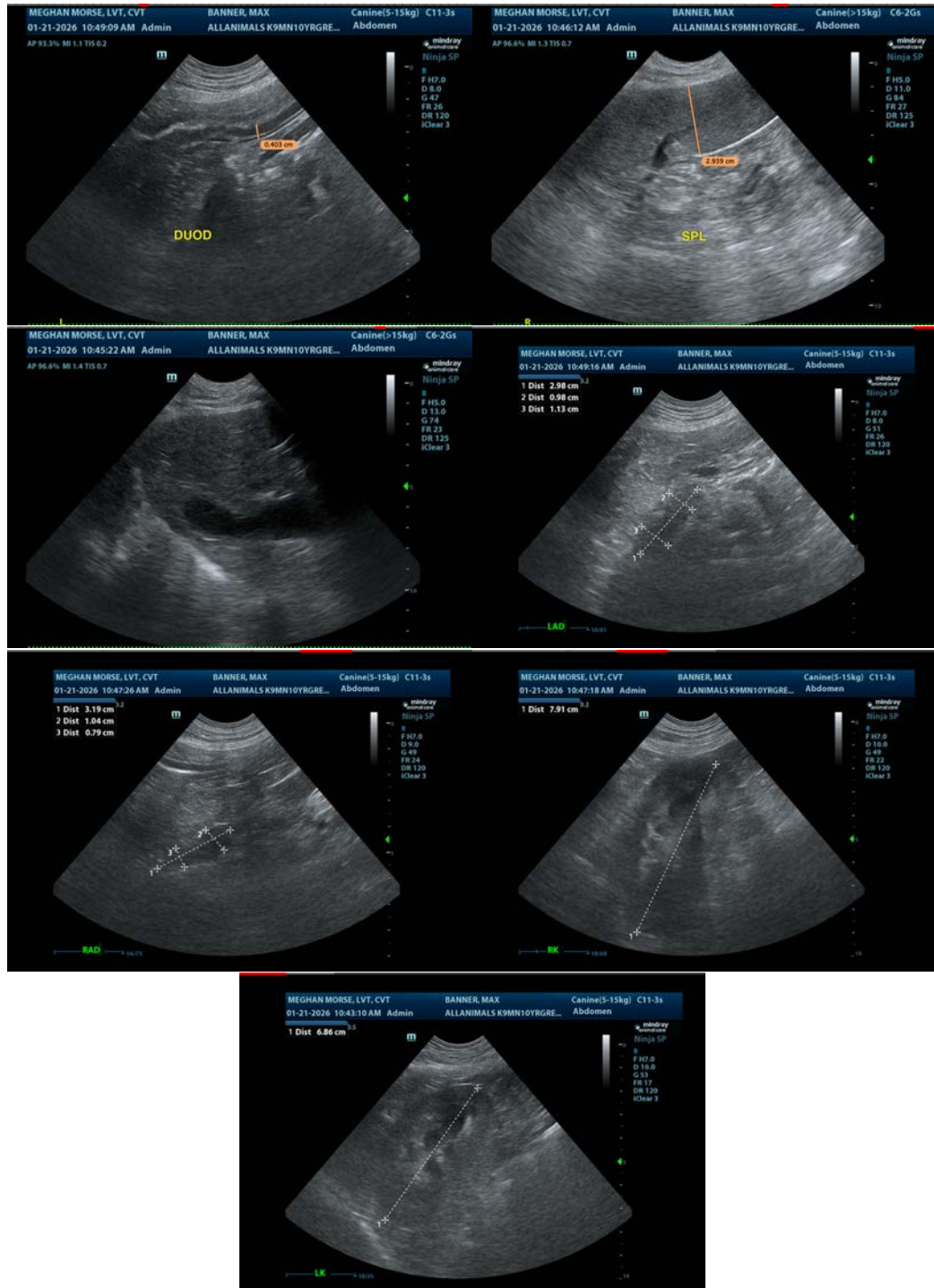
Dr. Acworth

INVOICE

72336

DATE

1/21/26





PATIENT

Max Banner

SPECIES

Canine

BREED

Great Pyrenees

SEX

Neutered Male

AGE

10 Years

WEIGHT

106.3 lbs

INTERPRETED BY

Kathleen Sennello DVM,
MS, Diplomate ACVIM
(Small Animal Internal
Medicine)

**IMAGING
PERFORMED BY**

Meghan Morse, LVT,
CVT

HOSPITAL NAME

All Animal Veterinary
Services

REFERRING VET

Dr. Acworth

INVOICE

72336

DATE

1/21/26

The information and recommendations provided are based on the images presented by the referring veterinarian/sonographer. No evaluation can be communicated regarding pathology that was not visible in the image/video clips provided.

Thank you for this referral. If the clinical or image interpretation does not parallel your findings or if I can be of any further assistance please contact me.

Kathleen Sennello DVM,MS, Diplomate ACVIM (Small animal Internal Medicine)

info@sonopath.com