



PATIENT

Addy Council

SPECIES

Canine

BREED

Bernese Mountain Dog

SEX

Spayed Female

AGE

7 Years

WEIGHT

80 lbs

INTERPRETED BY

Kathleen Sennello DVM,
MS, Diplomate ACVIM
(Small Animal Internal
Medicine)

IMAGING PERFORMED BY

Dr. Brittany Wolfe

HOSPITAL NAME

HomeVets

REFERRING VET

Dr. Brittany Wolfe

INVOICE

72363

DATE

1/21/26

PRESENTING CLINICAL SIGNS

P presents for screen US prior to MCT removal

Abnormal PE/Chem/CBC/UA Results: 2cm MCT on right cranial stifle, developed quickly CBC/chem normal Chest x-rays clear

ULTRASONOGRAPHIC EXAMINATION OF THE ABDOMEN

Urinary System

The urinary bladder is moderately distended with anechoic urine. The Bladder wall, trigone, ureteral papillae and visible urethra (to a depth of 2cm) appear normal with no evidence of wall thickening, mucosal irregularities, masses or cystic calculi.

The left kidney has a normal shape and size (6.7 cm). Overall echogenicity is normal with adequate corticomedullary distinction and a typical 1:3 cortex:medulla ratio. There is no evidence of focal perinephric inflammation or effusion. There is no evidence of pyelectasia, nephroliths, infarcts or hydroureter. Renal vasculature is normal.

The right kidney has a normal shape and size (6.5 cm). Overall echogenicity is normal with adequate corticomedullary distinction and a typical 1:3 cortex:medulla ratio. There is no evidence of focal perinephric inflammation or effusion. There is no evidence of pyelectasia, nephroliths, infarcts or hydroureter. Renal vasculature is normal.

Adrenal Glands

The left adrenal gland is borderline "flat", measuring 0.39 cm at the cranial pole and 0.42 cm at the caudal pole. It is observed in its normal position cranial to the left renal artery. It is normal in appearance (uniformly hypoechoic) and shape with no evidence of a mass effect.

The right adrenal gland is normal in size measuring 0.48 cm at the cranial pole and 0.49 cm at the caudal pole. It is observed in its normal position between the cranial aspect of the right kidney and the caudal vena cava. It is normal in appearance (uniformly hypoechoic) and shape with no evidence of a mass effect.

Spleen

The spleen is subjectively normal in size (1.5 cm in width at the level of the hilus), echotexture is homogenous, and the splenic capsule is smooth with no irregularities. The blood flow through the hilus and splenic parenchyma appears normal. There is a hypoechoic nodule visualized within the parenchyma measuring 1.0 cm in diameter.

Liver

The liver is subjectively normal in size, and echogenicity with smooth peripheral margins. The parenchyma is homogenous echotexture. The visible portions of the vasculature and biliary tract appear normal. No focal nodules or cystic lesions are observed.

The gall bladder lumen is moderately distended. The wall of the gall bladder is not thickened and has a smooth mucosal surface. There is a moderate amount of non-organized echogenic debris. The cystic and common bile ducts are normal/not visible.



PATIENT

Addy Council

SPECIES

Canine

BREED

Bernese Mountain Dog

SEX

Spayed Female

AGE

7 Years

WEIGHT

80 lbs

INTERPRETED BY

Kathleen Sennello DVM,
MS, Diplomate ACVIM
(Small Animal Internal
Medicine)

IMAGING PERFORMED BY

Dr. Brittany Wolfe

HOSPITAL NAME

HomeVets

REFERRING VET

Dr. Brittany Wolfe

INVOICE

72363

DATE

1/21/26

Gastrointestinal

The stomach contains minimal luminal contents. It measures at a normal thickness of <0.7cm with some variability due to the presence of rugal folds. The distinction of the gastric wall layers is adequate and there is no impression of reduced peristaltic activity. No masses or focal lesions were observed.

The visualized areas of duodenum, jejunum and ileum have a relatively uniform diameter with minimal fluid distension. Wall thickness is normal. Bowel loops follow a curvilinear path with distinct wall layering maintaining the typical 1:3 muscularis:mucosa layer ratio. Jejunum wall measures 0.35 cm. Visualized peristalsis appears appropriate. There were no focal lesions consistent with obstruction or a mass effect observed.

Sections of colon are visualized with formed fecal material and gas shadowing distally. There is no observed focal or generalized colon wall thickening or loss of layering.

Pancreas

The area of the pancreas is normal and isoechoic to surrounding mesentery. There is no evidence of nodules or cystic lesions. There is no evidence of regional mesenteric inflammation or fluid.

Free Abdomen

Evaluation of the peritoneal cavity did not reveal any evidence of effusion. There is no evidence of a significant lymphadenopathy. A prominent isoechoic iliac lymph node is visualized measuring 0.57 cm x 2.2 cm. The omentum is normal in echogenicity.

ULTRASONOGRAPHIC FINDINGS

- Hypoechoic nodule visualized in the spleen –Differentials include lymphoid hyperplasia, extramedullary hematopoiesis, infiltrative neoplasia, inflammation, other. Cytology or histopathology would be necessary to get a definitive diagnosis.
- Moderate gallbladder debris – The significance of the aggregated gallbladder debris is unclear. This could represent an early mucocele, cholestasis, or may be secondary to fasting but seems unlikely to be causing a current issue. Recommend continued monitoring.
- Isoechoic, prominent iliac lymph node – Findings could be consistent with a mildly reactive lymph node.

INTERPRETATION OF THE FINDINGS & FURTHER RECOMMENDATIONS

There is a small hypoechoic nodule in the spleen. This could represent a benign or neoplastic lesion. Given the history of mast cell disease, strongly consider a fine needle aspirate. If this is not an option, splenectomy could be considered.



PATIENT

Addy Councill

SPECIES

Canine

BREED

Bernese Mountain Dog

SEX

Spayed Female

AGE

7 Years

WEIGHT

80 lbs

INTERPRETED BY

Kathleen Sennello DVM,
MS, Diplomate ACVIM
(Small Animal Internal
Medicine)

**IMAGING
PERFORMED BY**

Dr. Brittany Wolfe

HOSPITAL NAME

HomeVets

REFERRING VET

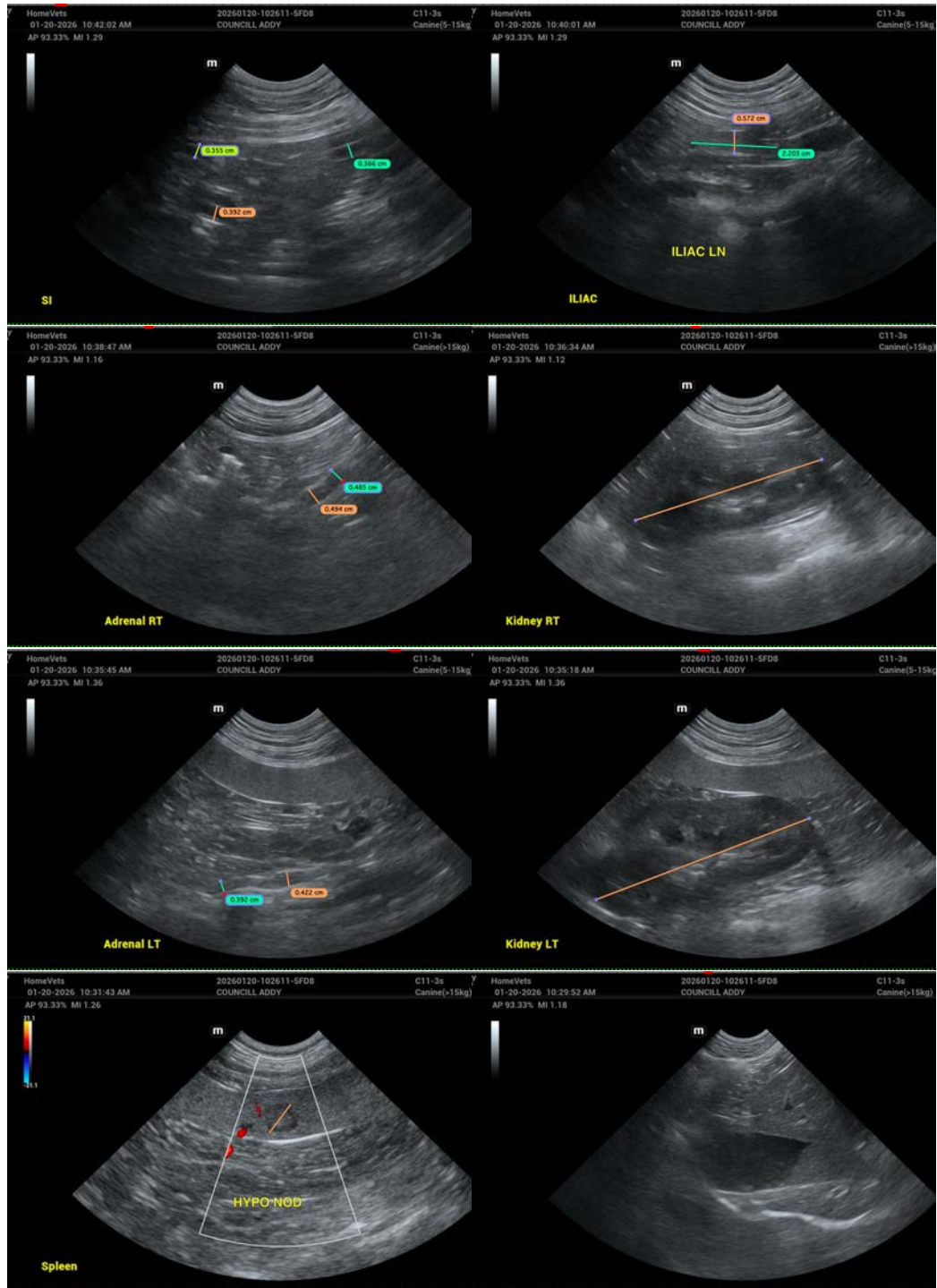
Dr. Brittany Wolfe

INVOICE

72363

DATE

1/21/26





PATIENT

Addy Councill

SPECIES

Canine

BREED

Bernese Mountain Dog

SEX

Spayed Female

AGE

7 Years

WEIGHT

80 lbs

INTERPRETED BY

Kathleen Sennello DVM,
MS, Diplomate ACVIM
(Small Animal Internal
Medicine)

IMAGING PERFORMED BY

Dr. Brittany Wolfe

HOSPITAL NAME

HomeVets

REFERRING VET

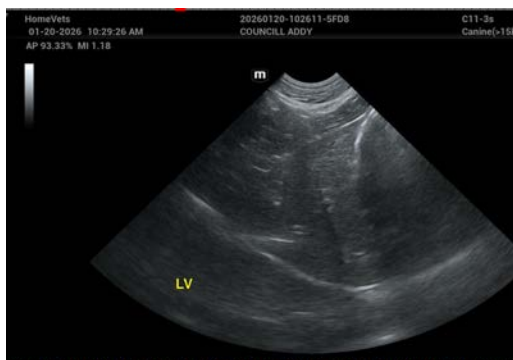
Dr. Brittany Wolfe

INVOICE

72363

DATE

1/21/26



The information and recommendations provided are based on the images presented by the referring veterinarian/sonographer. No evaluation can be communicated regarding pathology that was not visible in the image/video clips provided.

Thank you for this referral. If the clinical or image interpretation does not parallel your findings or if I can be of any further assistance please contact me.

Kathleen Sennello DVM,MS, Diplomate ACVIM (Small animal Internal Medicine)

info@sonopath.com