



PATIENT

Bella Ferraro

SPECIES

Canine

BREED

Yorkshire Terrier

SEX

Spayed Female

AGE

12 Years

WEIGHT

9.8 Pounds

INTERPRETED BY

Kathleen Sennello DVM,
MS, Diplomate ACVIM
(Small Animal Internal
Medicine)

**IMAGING
PERFORMED BY**

Shari Reffi, CVT

HOSPITAL NAME

Newton Vet Hospital

REFERRING VET

Dr. Wyman-Greenwald

INVOICE

34993

DATE

1/21/22

PRESENTING CLINICAL SIGNS

Elevated liver enzymes on bloodwork, asymptomatic. Current meds: Telmisartan 20mg 1/4 tab sid for proteinuria-no significant difference noted. Torbutrol iv for u/s.

Abnormal PE/Chem/CBC/UA Results: ALT 132, ALKP 713, Chol 332, Trig 336, PSL 309. USG 1.021, PH 7.0, Prot 3+, UPC 5.3

ULTRASONOGRAPHIC EXAMINATION OF THE ABDOMEN

Urinary System

The urinary bladder is moderately distended with anechoic urine. The Bladder wall, trigone, ureteral papillae and visible urethra (to a depth of 2cm) appear normal with no evidence of wall thickening, mucosal irregularities, masses or cystic calculi.

The left kidney has a normal shape and size (3.56 cm) with numerous small cortical cysts. Overall echogenicity is slightly hyperechoic with poor corticomedullary distinction and a typical 1:3 cortex:medulla ratio. There is no evidence of perinephric inflammation or effusion. There is no evidence of pyelectasia, nephroliths, infarcts or hydroureter. Renal vasculature is normal.

The right kidney has a normal shape and size (3.74 cm) with numerous small cortical cysts. Overall echogenicity is slightly hyperechoic with poor corticomedullary distinction and a typical 1:3 cortex:medulla ratio. There is no evidence of perinephric inflammation or effusion. There is no evidence of pyelectasia, nephroliths, infarcts or hydroureter. Renal vasculature is normal.

Adrenal Glands

The left adrenal gland is large in size measuring 1.76 cm at the cranial pole, 0.49 cm at the caudal pole, and 3.1 cm in length. It is observed in its normal position cranial to the left renal artery. It is somewhat abnormal in appearance, in that the cranial pole is much larger than the caudal pole, creating a mass effect. There is no obvious evidence of vascular invasion.

The right adrenal gland is normal in size measuring 0.84 cm at the caudal pole. It is observed in its normal position between the cranial aspect of the right kidney and the caudal vena cava. It is normal in appearance (uniformly hypoechoic) and shape with no evidence of a mass effect.

Spleen

The spleen is subjectively normal in size and the echotexture is homogenous. The splenic capsule is smooth with no visible irregularities. Rare discrete focal hyperechoic, perivascular parenchymal abnormalities are present. The appearance of these lesions is most consistent with benign splenic myelolipomas. The blood flow through the hilus and splenic parenchyma appears normal.

Liver

The liver is subjectively normal in size, and echogenicity with smooth peripheral margins. The parenchyma is heterogenous in echotexture with subtle, indistinct focal mottling. There is a very ill-defined, hyperechoic mass effect on the diaphragmatic surface of the liver, measuring >1.5 cm x 1.92 cm.

The gall bladder lumen is significantly distended. Some areas of the wall appear mildly thickened with adherent debris. There is a large amount of primarily non-organized echogenic debris. Additionally, there is some early organization visualized, consistent with an early mucocele. The proximal bile duct is mildly dilated at 0.45 cm.



PATIENT

Gastrointestinal

Bella Ferraro

The stomach is moderately dilated with fluid and irregular shadowing material most consistent with normal ingesta and gas. It measures at a normal thickness of <0.7cm with some variability due to the presence of rugal folds. The distinction of the gastric wall layering is adequate and there is no impression of reduced peristaltic activity. No masses or focal lesions were observed.

SPECIES

Canine

The visualized areas of duodenum, jejunum and ileum have a relatively uniform diameter with minimal fluid distension. Wall thickness is normal. Bowel loops follow a curvilinear path with distinct wall layering maintaining the typical 1:3 muscularis:mucosa layer ratio. Duodenum wall measured 0.50 cm. Jejunum wall measured 0.32 cm. Visualized peristalsis appears appropriate. There were no focal lesions consistent with obstruction or a mass effect observed.

BREED

Yorkshire Terrier

SEX

Spayed Female

The ileocecal junction was visualized and exhibited normal intact wall layering and is subjectively of normal thickness. Sections of colon are visualized with formed fecal material and gas shadowing distally. There is no observed focal or generalized colon wall thickening or loss of layering.

Pancreas

AGE

12 Years

The pancreas is normal and isoechoic to surrounding mesentery. There is no evidence of nodules or cystic lesions. There is no evidence of regional mesenteric inflammation or fluid.

Free Abdomen

WEIGHT

9.8 Pounds

Evaluation of the peritoneal cavity did not reveal any evidence of effusion, or subjective lymphadenomegaly. The Medial iliac nodes appear normal and there was no evidence of a caudal aortic thrombus at the bifurcation. The omentum is of normal uniform echogenicity.

Other

INTERPRETED BY

Kathleen Sennello DVM,
MS, Diplomate ACVIM
(Small Animal Internal
Medicine)

A brief view of the heart was submitted. No significant pericardial effusion was seen.

ULTRASONOGRAPHIC FINDINGS

IMAGING PERFORMED BY

Shari Reffi, CVT

- Left-sided adrenal mass – Left adrenomegaly could be consistent with neoplasia (e.g., adenoma, carcinoma, pheochromocytoma), hyperplasia, inflammation, other.
- Decreased corticomedullary distinction in both kidneys with small cortical cysts – Mild loss of corticomedullary distinction in both kidneys could be consistent with chronic degenerative disease or interstitial nephrosis.
- Heterogeneous liver with ill-defined hyperechoic mass effect – The diffuse hepatic changes are non-specific and could be consistent with vacuolar hepatopathy, nodular hyperplasia, inflammatory/immune-mediated disease, fibrosis, extramedullary hematopoiesis, toxic hepatopathy (e.g., copper), infiltrative neoplasia (less likely) or other hepatopathy. The changes observed could be consistent with remodeling, regenerative nodule, etc., but underlying neoplasia cannot be excluded as a possibility.
- Early gallbladder mucocele with dilated proximal bile duct – There is no evidence of surrounding fluid or inflammation. Recommend medical management and close monitoring.

HOSPITAL NAME

Newton Vet Hospital

REFERRING VET

Dr. Wyman-Greenwald

INVOICE

34993

INTERPRETATION OF THE FINDINGS & FURTHER RECOMMENDATIONS

Unfortunately, there are numerous reasons for the liver enzyme elevations noted. They could be secondary to elevated hormone levels (cortisol) with a Cushing's like syndrome, they could be elevated secondary to the irregular hyperechoic lesion, and they could also be partially elevated due to the

DATE

1/21/22



PATIENT

gallbladder disease present.

Bella Ferraro

There is a mass effect present involving the left adrenal gland. This mass is relatively large for a small dog, but I do not see evidence of clear vascular invasion, although it is still possible. These masses can be benign or malignant and can secrete hormones or be non-active. Options moving forward include:

SPECIES

Canine

- If signs of cushings are present, consider adrenal function testing. I prefer an ACTH stimulation test combined with an adrenal panel to the University of Tennessee's endocrine lab to look for atypical adrenal hormones as well as cortisol. (other testing can suffice)

BREED

Yorkshire Terrier

- If adrenal dependent cushings is suspected and supported by adrenal function testing consider medical therapy with lysodren or trilostane and/or consider surgical removal (recommend referral to a board certified veterinary surgeon and possible pre op CT)-This can be a challenging surgery with significant risk for complication

SEX

Spayed Female

- Recommend blood pressure evaluation-if hypertensive consider testing catecholamine levels for a possible pheochromocytoma

AGE

12 Years

- Due to the invasive nature of these masses a CT scan is recommended to evaluate for metastasis and vascular invasion.

WEIGHT

9.8 Pounds

- If no symptoms of cushings are present, consider either referral for surgery or if surgery is not an option consultation with a veterinary oncologist regarding chemotherapeutic options and continued monitoring with ultrasound (in 4-6 weeks) can be considered.

- Some aggressive adrenal tumors can grow quickly and there is risk for acute hemorrhage from vascular invasion.

INTERPRETED BY

Kathleen Sennello DVM,
MS, Diplomate ACVIM
(Small Animal Internal
Medicine)

The significance of the changes in the liver are unclear. You could consider a liver function test and a fine needle aspirate of the liver. If surgical resection would be considered, then you could also consider a CT scan to both evaluate the liver and the left adrenal gland. A conservative approach would include monitoring with ultrasound, although this lesion is difficult to measure due to its irregular shape.

IMAGING PERFORMED BY

Shari Reffi, CVT

There appears to be an early gallbladder mucocele present and mild dilation of the common bile duct. Recommend medical management with Ursodiol and a course of antibiotics while watching bloodwork and monitoring the gallbladder with ultrasound. If acute abdominal pain or GI signs occur, this lesion should be reevaluated for possible surgical removal.

HOSPITAL NAME

Newton Vet Hospital

The changes observed in the kidneys are consistent with the previously diagnosed renal disease. Recommend blood pressure evaluation if this has not already been done. Recommend 3-view thoracic radiographs.

REFERRING VET

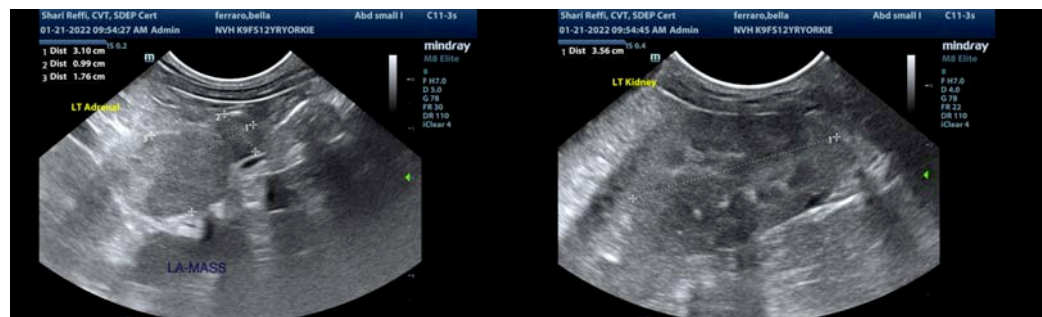
Dr. Wyman-Greenwald

INVOICE

34993

DATE

1/21/22





PATIENT

Bella Ferraro

SPECIES

Canine

BREED

Yorkshire Terrier

SEX

Spayed Female

AGE

12 Years

WEIGHT

9.8 Pounds

INTERPRETED BY

Kathleen Sennello DVM,
MS, Diplomate ACVIM
(Small Animal Internal
Medicine)

**IMAGING
PERFORMED BY**

Shari Reffi, CVT

HOSPITAL NAME

Newton Vet Hospital

REFERRING VET

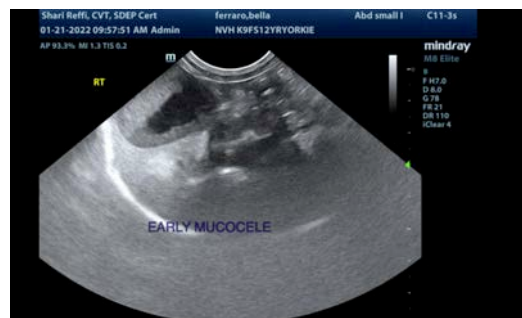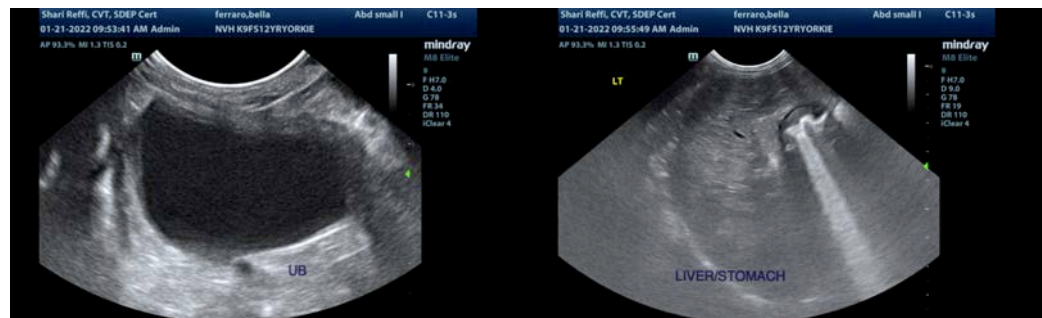
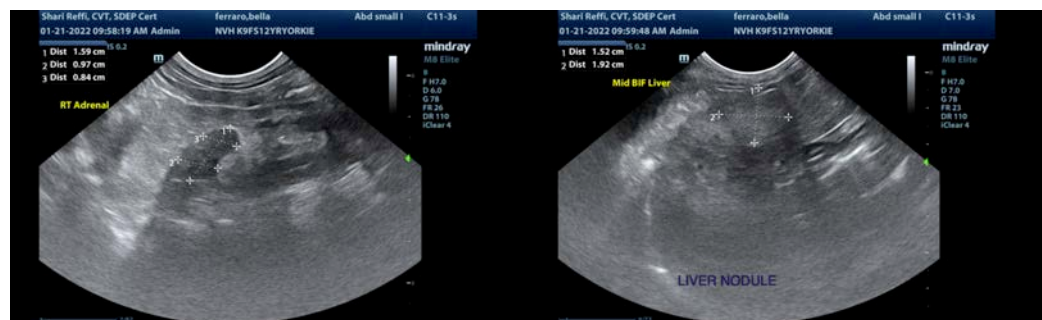
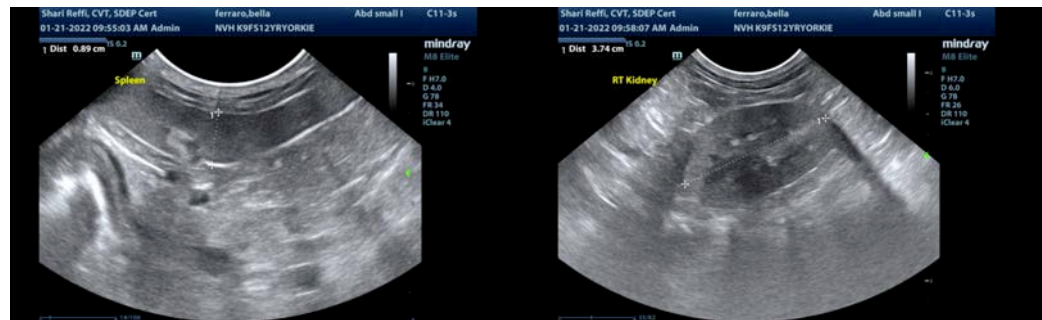
Dr. Wyman-Greenwald

INVOICE

34993

DATE

1/21/22



The information and recommendations provided are based on the images presented by the referring veterinarian/sonographer. No evaluation can be communicated regarding pathology that was not visible in the image/video clips provided.

Thank you for this referral. If the clinical or image interpretation does not parallel your findings or if I can be of any further assistance please contact me.

Kathleen Sennello DVM,MS, Diplomate ACVIM (Small animal Internal Medicine)
kathleen.sennello@sonopath.com