

**DATE PRESENTING CLINICAL SIGNS**

1/21/22

History: p presented on 1/18/22 for a hx of chronic intermittent diarrhea. p originally presented on 12/16/21 for acute diarrhea, vomiting, nausea, lethargy and panting. p was diagnosed with thyroid (hypothyroidism) 3 months prior, and states that clinical signs started after starting l-thyroxine. It was determined that p has being over regulated from lab work performed 11/2021 and meds were reduced by 50% but clinical signs did not improve.

**PATIENT**

Alice Scott

**SPECIES**

Canine

Current Medications: 12/16/2021 Metronidazole 500mg - 1 tab PO BID, ProvableDC Cap: 1cap PO SID, Cerenia Inj - 4.41 cc.

Lab Results: 12/16/21 T4 <0.4, WBC 19.9, NEU 17592. Fecal-neg 9/13/2021.

Date of Previous IntraPet Ultrasound: No previous IntraPet scans.

Sedation: Telazol IV.

**BREED**

Mixed

Stat Report: Not requested.

**ULTRASONOGRAPHIC EXAMINATION OF THE ABDOMEN****SEX**

Spayed Female

**Urinary System**

The urinary bladder is moderately distended with anechoic urine. The Bladder wall, trigone, ureteral papillae and visible urethra (to a depth of 2cm) appear normal with no evidence of wall thickening, mucosal irregularities, masses or cystic calculi.

**AGE**

7/4/13

The left kidney has a normal shape and size (7.13 cm). Overall echogenicity is slightly hyperechoic with poor corticomedullary distinction and a typical 1:3 cortex:medulla ratio. There is no evidence of perinephric inflammation or effusion. There is no evidence of pyelectasia, nephroliths, infarcts or hydroureter. Renal vasculature is normal.

**WEIGHT**

100.7 Pounds

The right kidney has a normal shape and size (6.04 cm). Overall echogenicity is slightly hyperechoic with mildly decreased corticomedullary distinction and a typical 1:3 cortex:medulla ratio. There is no evidence of perinephric inflammation or effusion. There is no evidence of pyelectasia, nephroliths, infarcts or hydroureter. Renal vasculature is normal.

**INTERPRETED BY**

Kathleen Sennello DVM,  
MS, Diplomate ACVIM  
(Small Animal Internal  
Medicine)

**Adrenal Glands**

The left adrenal gland is normal in size measuring 0.79 cm at the caudal pole. It is observed in its normal position cranial to the left renal artery. It is normal in appearance (uniformly hypoechoic) and shape with no evidence of a mass effect.

**IMAGING PERFORMED BY**

Stephanie Pearce  
RDMS, RVT

The right adrenal gland is normal in size measuring 0.79 cm at the caudal pole. It is observed in its normal position between the cranial aspect of the right kidney and the caudal vena cava. It is normal in appearance (uniformly hypoechoic) and shape with no evidence of a mass effect.

**HOSPITAL NAME**

Northwind AH

**Spleen**

The spleen is subjectively normal in size. The spleen echotexture is heterogenous and mottled, the splenic capsule is smooth with no irregularities. The blood flow through the hilus and splenic parenchyma appears normal. No focal parenchymal abnormalities are visualized.

**REFERRING VET**

Dr. Wilson

**Liver**

The liver is subjectively normal in size, and echogenicity with smooth peripheral margins. The parenchyma is mildly heterogenous in echotexture with subtle, indistinct focal mottling. The visible portions of the vasculature and biliary tract appear normal. No focal nodules or cystic lesions are observed.

**INVOICE**

35001

The gall bladder lumen is moderately distended. The wall of the gall bladder is not thickened and has a smooth mucosal surface. There is a moderate amount of non-organized echogenic debris. The cystic and common bile ducts are normal/not visible.

### ***Gastrointestinal***

The stomach is moderately dilated with fluid and irregular shadowing material most consistent with normal ingesta and gas. It measures at a normal thickness of <0.7cm with some variability due to the presence of rugal folds. The distinction of the gastric wall layering is adequate and there is no impression of reduced peristaltic activity. No masses or focal lesions were observed.

The visualized areas of duodenum, jejunum and ileum have a uniform diameter with minimal fluid distension. Wall appears subjectively, mildly increased. Bowel loops follow a typical curvilinear path with distinct wall layering. Jejunum wall measured 0.29 cm. Visualized peristalsis appears appropriate. There is the overall impression of somewhat thickened bowel. The ileum at the ileocecal junction measures at 0.6 cm.

The ileocecal junction was visualized. In this area, the ileum appears somewhat thickened and the colon appears abnormal and thickened with wall thickness of 0.71 cm with a loss of normal layering. There is generalized inflammation and lymphadenomegaly surrounding the ileocecal junction.

### ***Pancreas***

The pancreas is normal and isoechoic to surrounding mesentery. There is no evidence of nodules or cystic lesions. There is no evidence of regional mesenteric inflammation or fluid.

### ***Free Abdomen***

There is scant free fluid present. There is a severe lymphadenopathy present with very large, hypoechoic lymph nodes at the root of the mesentery and around the ileocecal junction. These lymph nodes measure 5.57 cm, 3.43 cm, 3.8 cm, 3.8 cm, and 3.7 cm. Additionally, there is a sublumbar lymph node measuring 1.42 cm. The omentum is of increased echogenicity around the prominent lymph nodes.

### ***Other***

A brief view of the heart was submitted. No significant pericardial effusion was seen.

## **PRIMARY FINDINGS**

- Severe mesenteric lymphadenopathy – The severe mesenteric lymphadenopathy is most concerning for a neoplastic process, although you can see significant lymphadenopathy in some cases of autoimmune/inflammatory disease, infectious disease (tick born disease – such as bartonella, fungal infections, etc. A fine needle aspirate with cytology is recommended for further evaluation.
- Moderate to severe small and large intestinal wall thickening (primarily large) – The bowel wall thickening could be consistent with inflammation, edema, or infiltrative neoplasia. A reduction in the detail of wall layering favors either severe intestinal disease or neoplastic infiltration. Biopsy is recommended.
- Mottled spleen – The diffuse splenic changes are non-specific and could be consistent with lymphoid hyperplasia, extramedullary hematopoiesis, infiltrative neoplasia, inflammation, other. Cytology or histopathology would be necessary to get a definitive diagnosis.

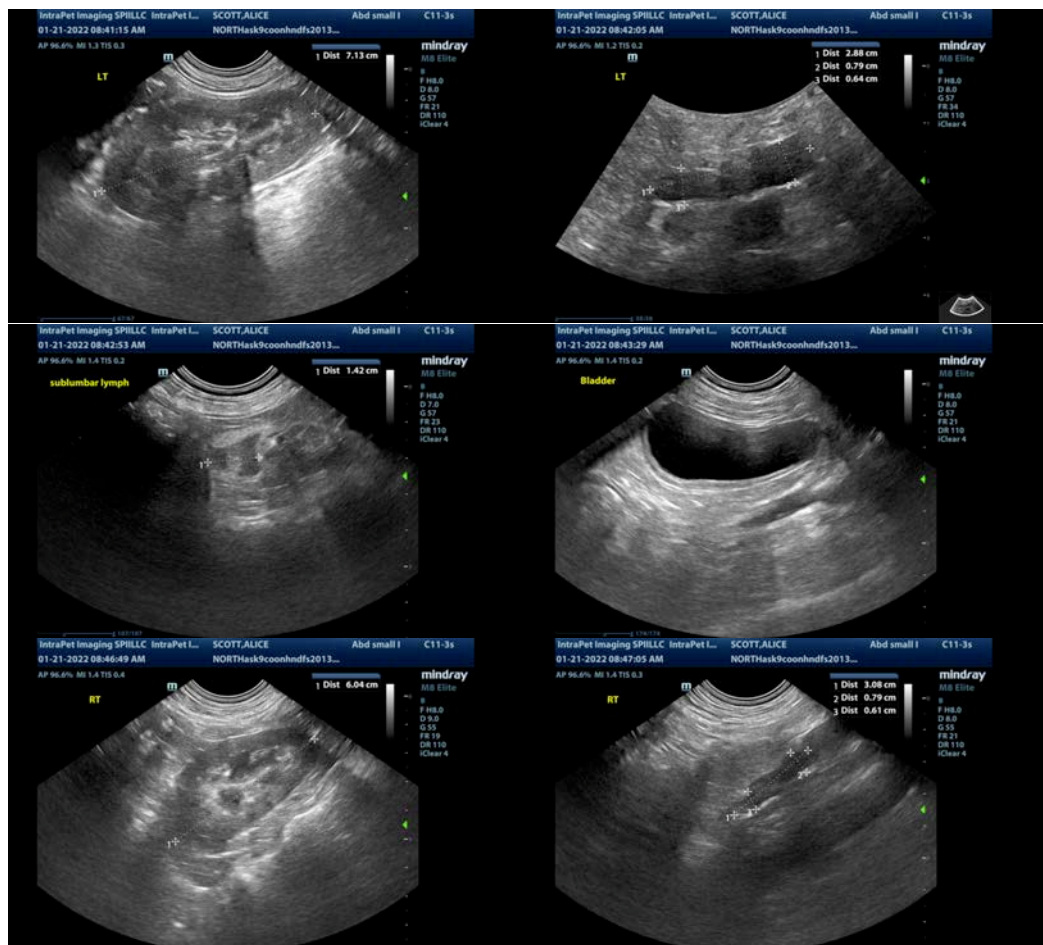
## **SECONDARY FINDINGS**

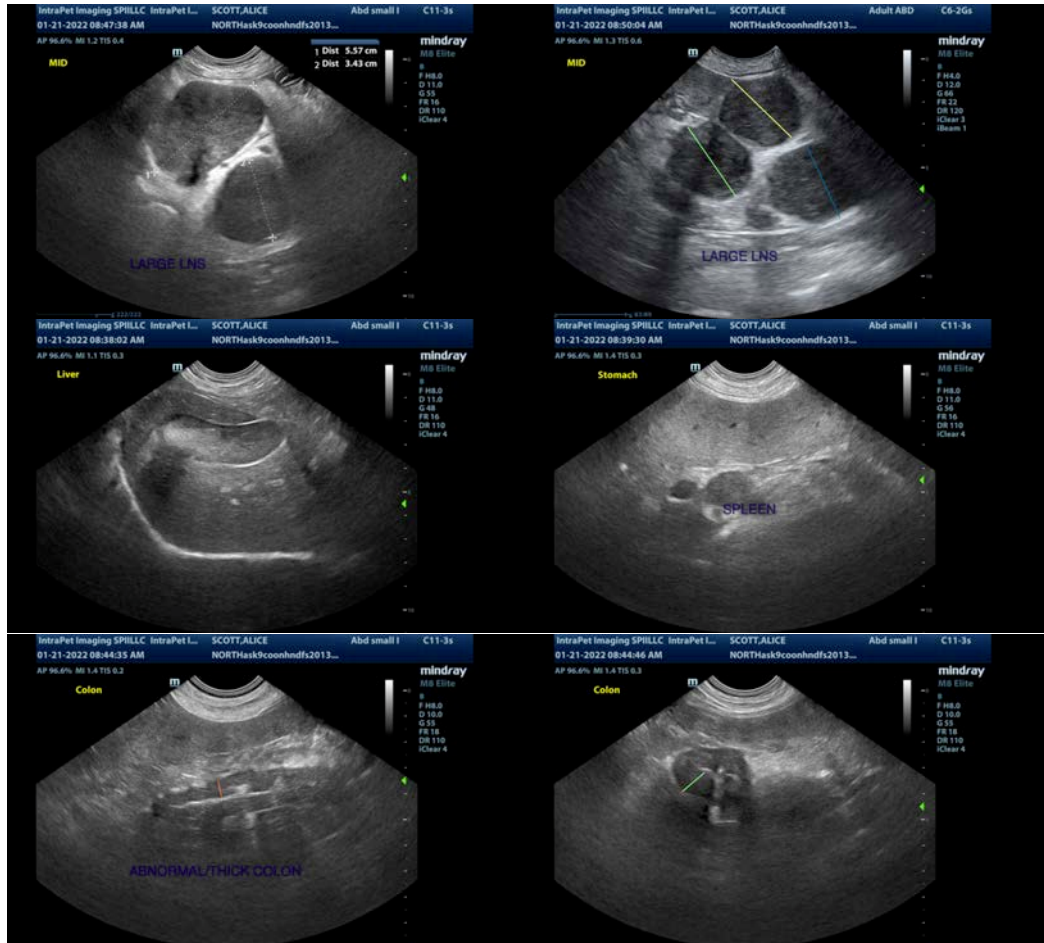
- Decreased corticomedullary distinction in both kidneys – The bilateral renal findings are consistent with age-related change.

- Mildly heterogeneous liver – The diffuse hepatic changes are non-specific and could be consistent with vacuolar hepatopathy, nodular hyperplasia, inflammatory/immune-mediated disease, fibrosis, extramedullary hematopoiesis, toxic hepatopathy (e.g., copper), infiltrative neoplasia (less likely) or other hepatopathy.
- Mild gallbladder sludge – The significance of the aggregated gallbladder sludge is unclear. This could represent an early mucocele, cholestasis, or may be secondary to fasting.

### INTERPRETATION OF THE FINDINGS & FURTHER RECOMMENDATIONS

A severe lymphadenomegaly is visualized along with colon wall thickening and some subjective thickening of the small intestine. Recommend a fine needle aspirate of a mesenteric lymph node, as there is a high concern for infiltrative bowel disease causing the low albumin and GI signs reported. Additionally, palpate carefully for a peripheral lymphadenopathy. If you're in an area where fungal disease is prominent, you could consider testing (serology) for histoplasmosis, less likely pythium, etc. If cytology is not diagnostic, recommend surgical biopsies of the lymph nodes, small and large intestine. Recommend 3-view thoracic radiographs.





The information and recommendations provided are based on the images presented by the referring veterinarian/sonographer. No evaluation can be communicated regarding pathology that was not visible in the image/video clips provided.

Thank you for this referral. If the clinical or image interpretation does not parallel your findings or if I can be of any further assistance please contact me.

Kathleen Sennello DVM,MS, Diplomate ACVIM (Small animal Internal Medicine)  
kathleen.sennello@sonopath.com