



PATIENT

Minnie Tang

SPECIES

Feline

BREED

Himalayan

SEX

Spayed Female

AGE

13 years

WEIGHT

4.36 kg

INTERPRETED BY

Kathleen Sennello DVM,
MS, Diplomate ACVIM
(Small Animal Internal
Medicine)

IMAGING PERFORMED BY

Dr. Gira

HOSPITAL NAME

Bridgeland Veterinary
Clinic

REFERRING VET

Dr. Flath

INVOICE

11166

DATE

1/20/2026

PRESENTING CLINICAL SIGNS

- Investigate her kidney health before proceeding with anesthesia, as there is a small risk of worsening kidney function during the procedure. If the workup reveals only age-related changes, we can safely proceed with the dental treatment.
- Slowly losing weight.

Abnormal PE/Chem/CBC/UA Results: Attached Elevated renal values iris 2, culture negative. Low USG.

ULTRASONOGRAPHIC EXAMINATION OF THE ABDOMEN

Urinary System

The urinary bladder is moderately distended with anechoic urine. The Bladder wall, trigone, ureteral papillae and visible urethra (to a depth of 2cm) appear normal with no evidence of wall thickening, mucosal irregularities, masses or cystic calculi.

The left kidney has a normal shape and size (3.49 cm). Overall echogenicity is slightly hyperechoic with poor corticomedullary distinction and a typical 1:3 cortex:medulla ratio. There is no evidence of focal perinephric inflammation or effusion. There is no evidence of pyelectasia, nephroliths, infarcts or hydroureter. Renal vasculature is normal.

The right kidney has a normal shape and size (3.74 cm). Overall echogenicity is slightly hyperechoic with poor corticomedullary distinction and a typical 1:3 cortex:medulla ratio. There is no evidence of focal perinephric inflammation or effusion. There is no evidence of pyelectasia, nephroliths, infarcts or hydroureter. Renal vasculature is normal.

Adrenal Glands

The left adrenal gland is normal in size measuring 0.37 cm at the caudal pole. It is observed in its normal position cranial to the left renal artery. It is normal in appearance (uniformly hypoechoic) and shape with no evidence of a mass effect.

The right adrenal gland is normal in size measuring 0.31 cm at the caudal pole. It is observed in its normal position between the cranial aspect of the right kidney and the caudal vena cava. It is normal in appearance (uniformly hypoechoic) and shape with no evidence of a mass effect.

Spleen

The spleen is subjectively normal in size (1.0 cm), echotexture is homogenous, and the splenic capsule is smooth with no irregularities. The blood flow through the hilus and splenic parenchyma appears normal. No focal parenchymal abnormalities are visualized.

Liver

The liver is subjectively normal in size, and echogenicity with smooth peripheral margins. The parenchyma is homogenous echotexture. The visible portions of the vasculature and biliary tract appear normal. No focal nodules or cystic lesions are observed.



PATIENT

Minnie Tang

The gall bladder lumen is moderately distended. The wall of the gall bladder is not thickened and has a smooth mucosal surface. Luminal contents are mild and likely incidental at this time. The cystic and common bile ducts are normal/not visible.

SPECIES

Feline

Gastrointestinal

The stomach contains minimal luminal contents. It measures at a normal thickness of <0.36cm with some variability due to the presence of rugal folds. The distinction of the gastric wall layers is adequate and there is no impression of reduced peristaltic activity. No masses or focal lesions were observed.

BREED

Himalayan

The visualized areas of duodenum, jejunum and ileum have a relatively uniform diameter with minimal fluid distension. Wall thickness is normal. Bowel loops follow a curvilinear path with distinct wall layering maintaining the typical 1:3 muscularis:mucosa layer ratio. The duodenum measured as normal (0.27 cm in wall thickness) and the jejunum measured as normal (between 0.15-0.36cm.) Visualized peristalsis appears appropriate. There were no focal lesions consistent with obstruction or a mass effect observed.

SEX

Spayed Female

AGE

13 years

The ileocecal junction was visualized and exhibited normal intact wall layering and is subjectively of normal thickness. Sections of colon are visualized with formed fecal material and gas shadowing distally. There is no observed focal or generalized colon wall thickening or loss of layering.

WEIGHT

4.36 kg

Pancreas

The pancreas is visible/mildly mottled in the left limb. There is no evidence of nodules or cystic lesions. There is no evidence of regional mesenteric inflammation or fluid.

INTERPRETED BY

Kathleen Sennello DVM,
MS, Diplomate ACVIM
(Small Animal Internal
Medicine)

Free Abdomen

Evaluation of the peritoneal cavity did not reveal any evidence of effusion. There is no significant lymphadenopathy. A prominent lymph node in the sub lumbar area is visualized measuring 0.35 cm 0.66 cm. The omentum is of normal uniform echogenicity.

IMAGING PERFORMED BY

Dr. Gira

ULTRASONOGRAPHIC FINDINGS

- Mildly reduced corticomedullary distinction in both kidneys. Findings are most consistent with age related change/early renal disease.
- Mild pancreatic remodeling in the left limb.

HOSPITAL NAME

Bridgeland Veterinary
Clinic

INTERPRETATION OF THE FINDINGS & FURTHER RECOMMENDATIONS

The renal changes are relatively mild. Unfortunately, the appearance of the kidneys does not always correlate with renal function. Consider running IV fluids during an anesthetic period (ideally an hour or two prior to anesthesia) to help reduce the likelihood of mild subclinical dehydration, etc. or a potential hypotensive event.

REFERRING VET

Dr. Flath

INVOICE

11166

DATE

1/20/2026



PATIENT

Minnie Tang

SPECIES

Feline

BREED

Himalayan

SEX

Spayed Female

AGE

13 years

WEIGHT

4.36 kg

INTERPRETED BY

Kathleen Sennello DVM,
MS, Diplomate ACVIM
(Small Animal Internal
Medicine)

**IMAGING
PERFORMED BY**

Dr. Gira

HOSPITAL NAME

Bridgeland Veterinary
Clinic

REFERRING VET

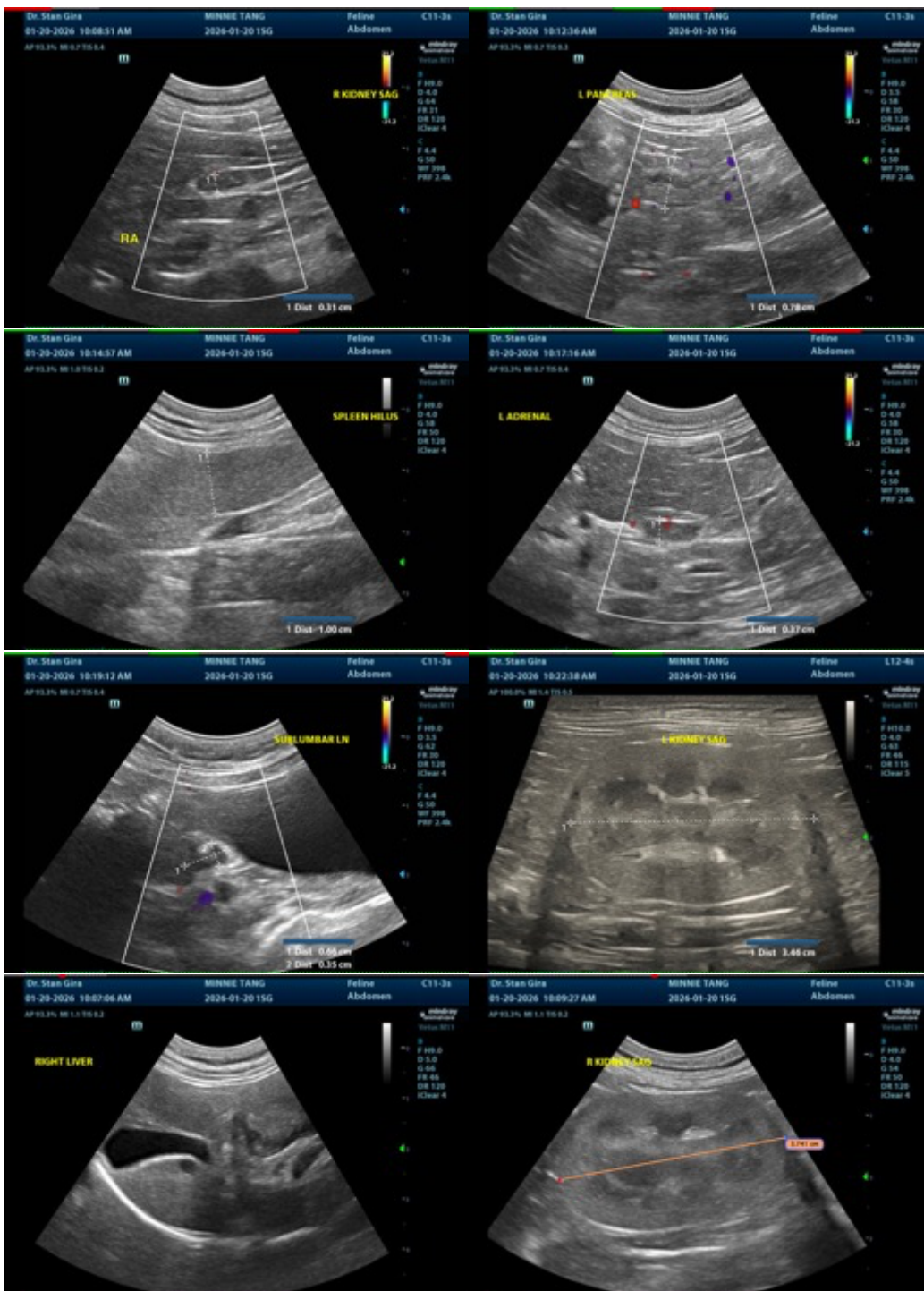
Dr. Flath

INVOICE

11166

DATE

1/20/2026





PATIENT

Minnie Tang

SPECIES

Feline

BREED

Himalayan

SEX

Spayed Female

AGE

13 years

WEIGHT

4.36 kg

INTERPRETED BY

Kathleen Sennello DVM,
MS, Diplomate ACVIM
(Small Animal Internal
Medicine)

IMAGING PERFORMED BY

Dr. Gira

HOSPITAL NAME

Bridgeland Veterinary
Clinic

REFERRING VET

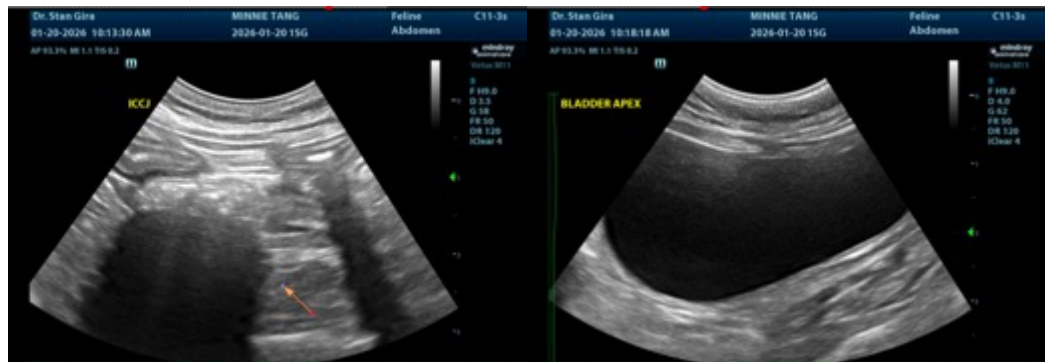
Dr. Flath

INVOICE

11166

DATE

1/20/2026



The information and recommendations provided are based on the images presented by the referring veterinarian/sonographer. No evaluation can be communicated regarding pathology that was not visible in the image/video clips provided.

Thank you for this referral. If the clinical or image interpretation does not parallel your findings or if I can be of any further assistance please contact me.

Kathleen Sennello DVM,MS, Diplomate ACVIM (Small animal Internal Medicine)

info@sonopath.com