



## PATIENT

Luna Velez

## SPECIES

Canine

## BREED

Mixed

## SEX

Spayed Femae

## AGE

10 Years

## WEIGHT

15 lbs

## INTERPRETED BY

Kathleen Sennello DVM,  
MS, Diplomate ACVIM  
(Small Animal Internal  
Medicine)

## IMAGING PERFORMED BY

Gabriel Ferrer, DVM

## HOSPITAL NAME

Pulse: Pet Ultrasound

## REFERRING VET

Dr. Jose Barrera

## INVOICE

72299

## DATE

1/20/26

## PRESENTING CLINICAL SIGNS

Abdominal ultrasound to evaluate weight loss. Used to be 20# now pt is #15.

Pt has hx of previous pancreatitis in 2023 and on RC GI diet. No current vomiting or diarrhea.

Abnormal PE/Chem/CBC/UA Results: PE: BCS 5/9 BW: previous GI panel from 2023

## ULTRASONOGRAPHIC EXAMINATION OF THE ABDOMEN

### Urinary System

The urinary bladder is mildly to moderately distended with anechoic urine. The Bladder wall appears mildly diffusely thickened, measuring at 0.36 cm, The trigone, ureteral papillae and visible urethra (to a depth of 2cm) appear normal with no evidence of wall thickening, mucosal irregularities, masses or cystic calculi.

The left kidney has a normal shape and size (4.3 cm). Overall echogenicity is slightly hyperechoic with mildly reduced corticomedullary distinction and a typical 1:3 cortex:medulla ratio. There is no evidence of focal perinephric inflammation or effusion. There is no evidence of pyelectasia, nephroliths, infarcts or hydroureter. Renal vasculature is normal.

The right kidney has a normal shape and size (4.22 cm). Overall echogenicity is slightly hyperechoic with mildly reduced corticomedullary distinction and a typical 1:3 cortex:medulla ratio. There is no evidence of focal perinephric inflammation or effusion. There is no evidence of pyelectasia, nephroliths, infarcts or hydroureter. Renal vasculature is normal.

### Adrenal Glands

The left adrenal gland is normal in size measuring 0.44 cm at the cranial pole and 0.58 cm at the caudal pole. It is observed in its normal position cranial to the left renal artery. It is normal in appearance (uniformly hypoechoic) and shape with no evidence of a mass effect.

The right adrenal gland is normal in size measuring 0.53 cm at the cranial pole and 0.46 cm at the caudal pole. It is observed in its normal position between the cranial aspect of the right kidney and the caudal vena cava. It is normal in appearance (uniformly hypoechoic) and shape with no evidence of a mass effect.

### Spleen

The spleen is subjectively normal in size (1.08 cm), echotexture is homogenous, and the splenic capsule is smooth with no irregularities. The blood flow through the hilus and splenic parenchyma appears normal. No focal parenchymal abnormalities are visualized.

### Liver

The liver is subjectively normal in size, and echogenicity with smooth peripheral margins. The parenchyma is mildly heterogenous in echotexture with subtle, indistinct focal mottling. The visible portions of the vasculature and biliary tract appear normal. No focal nodules or cystic lesions are observed.



## PATIENT

Luna Velez

The gall bladder lumen is moderately distended. The wall of the gall bladder is not thickened and has a smooth mucosal surface. There is a moderate amount of non-organized echogenic debris. The cystic and common bile ducts are normal/not visible.

## SPECIES

Canine

### **Gastrointestinal**

The stomach contains minimal luminal contents. It measures at a normal thickness of 0.33 cm with some variability due to the presence of rugal folds. The distinction of the gastric wall layers is adequate and there is no impression of reduced peristaltic activity. No masses or focal lesions were observed.

## BREED

Mixed

The visualized areas of duodenum, jejunum and ileum have a relatively uniform diameter with minimal fluid distension. Wall thickness is normal. Bowel loops follow a curvilinear path with distinct wall layering maintaining the typical 1:3 muscularis:mucosa layer ratio. Duodenum wall measures 0.46 cm. Jejunum wall measures 0.36 cm. Visualized peristalsis appears appropriate. There were no focal lesions consistent with obstruction or a mass effect observed.

## SEX

Spayed Femae

## AGE

10 Years

Sections of colon are visualized with formed fecal material and gas shadowing distally. There is no observed focal or generalized colon wall thickening or loss of layering.

### **Pancreas**

## WEIGHT

15 lbs

The pancreas is normal and isoechoic to surrounding mesentery. There is no evidence of nodules or cystic lesions. There is no evidence of regional mesenteric inflammation or fluid.

### **Free Abdomen**

## INTERPRETED BY

Kathleen Sennello DVM,  
MS, Diplomate ACVIM  
(Small Animal Internal  
Medicine)

Evaluation of the peritoneal cavity did not reveal any evidence of effusion, or subjective lymphadenomegaly. The Medial iliac nodes appear normal and there was no evidence of a caudal aortic thrombus at the bifurcation. The omentum is of normal uniform echogenicity.

## ULTRASONOGRAPHIC FINDINGS

## IMAGING PERFORMED BY

Gabriel Ferrer, DVM

- Prominent/mildly thickened bladder wall – The bladder mucosal changes could be consistent with cystitis or artifactual due to lack of adequate luminal distension. Bladder neoplasia cannot be ruled out but is considered unlikely in this patient.
- Age related changes visualized associated with both kidneys.
- Mildly heterogeneous liver – Correlate with current liver values. The significance of this is uncertain.
- Moderate gallbladder debris – The significance of the aggregated gallbladder debris is unclear. This could represent an early mucocele, cholestasis, or may be secondary to fasting but seems unlikely to be causing a current issue. Recommend continued monitoring.

## HOSPITAL NAME

Pulse: Pet Ultrasound

## REFERRING VET

Dr. Jose Barrera

## INVOICE

72299

## DATE

1/20/26

## INTERPRETATION OF THE FINDINGS & FURTHER RECOMMENDATIONS

The lesions observed on today's scan are relatively mild and non-specific. No focal lesions are visualized to explain the weight loss reported. This does not rule out the possibility of a primary enteropathy or other issues but makes it somewhat less likely. If the patient is acting normal, recommend calculating caloric intake in conjunction with expected caloric needs and confirm the patient is eating enough. Additionally, consider increasing caloric intake to see if weight gain occurs. If weight loss is persistent or



**PATIENT**

Luna Velez

**SPECIES**

Canine

**BREED**

Mixed

**SEX**

Spayed Femae

**AGE**

10 Years

**WEIGHT**

15 lbs

**INTERPRETED BY**

Kathleen Sennello DVM,  
MS, Diplomate ACVIM  
(Small Animal Internal  
Medicine)

**IMAGING  
PERFORMED BY**

Gabriel Ferrer, DVM

**HOSPITAL NAME**

Pulse: Pet Ultrasound

**REFERRING VET**

Dr. Jose Barrera

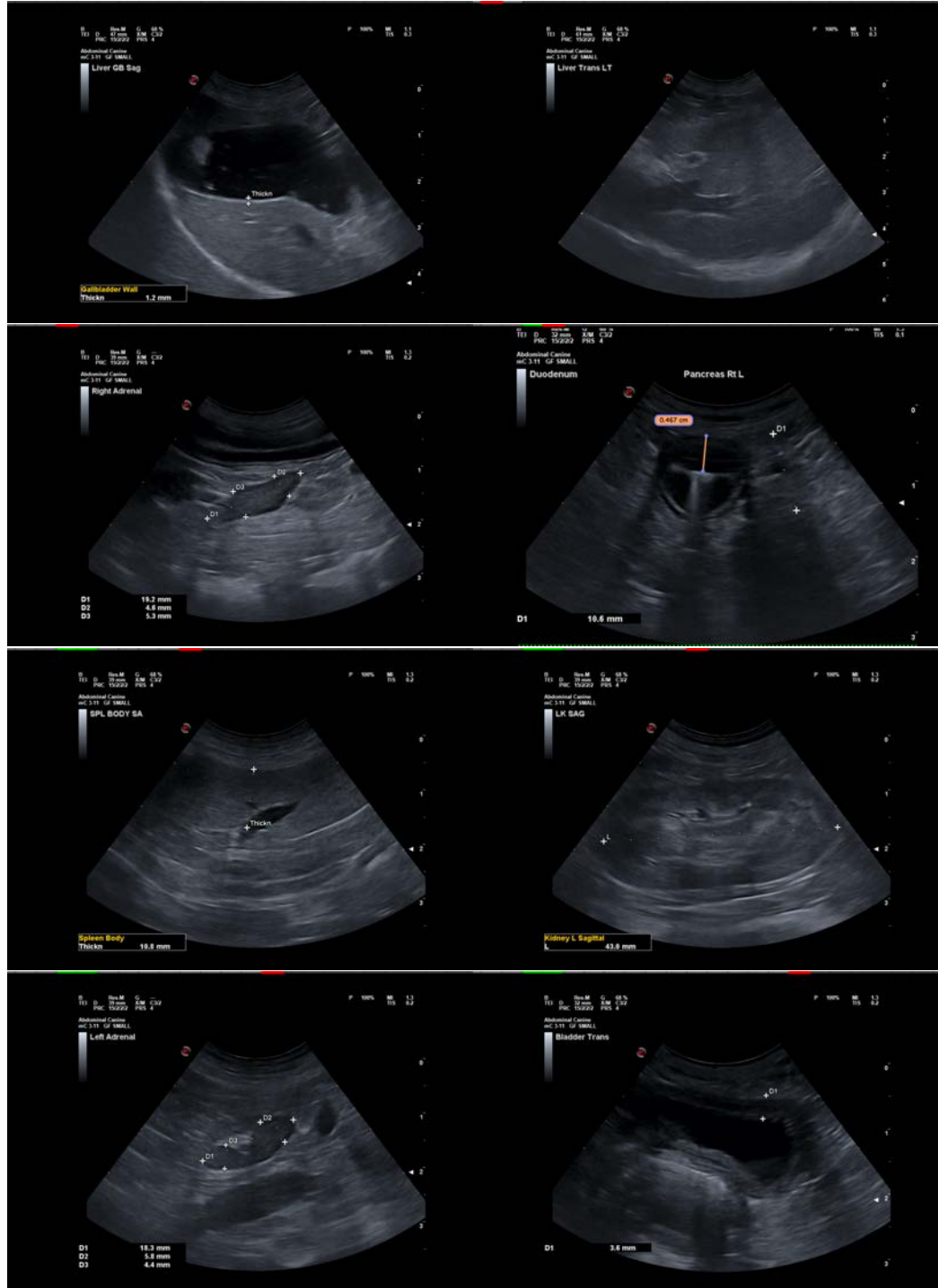
**INVOICE**

72299

**DATE**

1/20/26

progressive, further evaluation and/or reevaluation may be warranted.





## PATIENT

Luna Velez

## SPECIES

Canine

## BREED

Mixed

## SEX

Spayed Femae

## AGE

10 Years

## WEIGHT

15 lbs

## INTERPRETED BY

Kathleen Sennello DVM,  
MS, Diplomate ACVIM  
(Small Animal Internal  
Medicine)

## IMAGING PERFORMED BY

Gabriel Ferrer, DVM

## HOSPITAL NAME

Pulse: Pet Ultrasound

## REFERRING VET

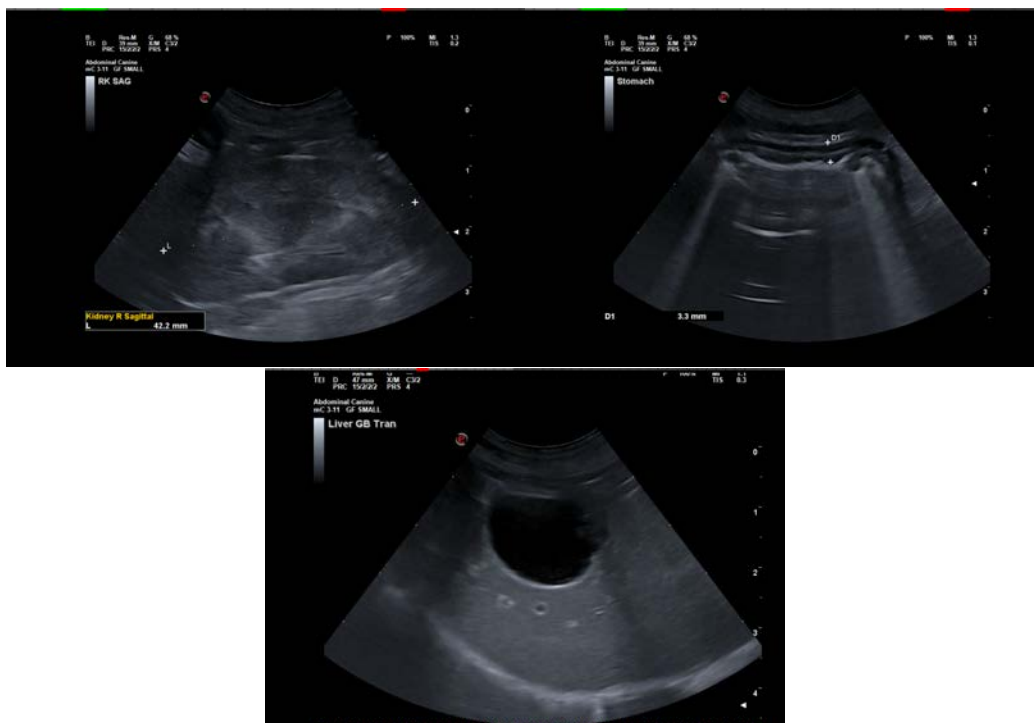
Dr. Jose Barrera

## INVOICE

72299

## DATE

1/20/26



The information and recommendations provided are based on the images presented by the referring veterinarian/sonographer. No evaluation can be communicated regarding pathology that was not visible in the image/video clips provided.

Thank you for this referral. If the clinical or image interpretation does not parallel your findings or if I can be of any further assistance please contact me.

Kathleen Sennello DVM,MS, Diplomate ACVIM (Small animal Internal Medicine)

info@sonopath.com