



PATIENT

Kit Haskins

SPECIES

Canine

BREED

Pug

SEX

Neutered Male

AGE

13 Years 8 Months

WEIGHT

20 lbs

INTERPRETED BY

Kathleen Sennello DVM,
MS, Diplomate ACVIM
(Small Animal Internal
Medicine)

IMAGING PERFORMED BY

Dr. Lucas Budden

HOSPITAL NAME

Frontier Veterinary
Hospital

REFERRING VET

Dr. Lucas Budden

INVOICE

72313

DATE

1/20/26

PRESENTING CLINICAL SIGNS

Chronic ALP elevation, new ALT elevation. ALP elevation chronic. First noted 12/23/22 (205). Recent lab work 1/4/26 further increased to 479. ALT increase first noted 12/13/25 (129). Persistently increased on 1/4/26 (155). Ultrasound to assess for underlying cause.

Current medications: Fluticasone for chronic bronchitis (recent history of coughing and increased respiratory effort) - echo in December 2025 found no evidence of heart failure and no need for cardiac medications at this time. Butorphanol to facilitate imaging

Abnormal PE/Chem/CBC/UA Results: Physical exam: No heart murmur heard today (history of tricuspid/mitral/aortic regurgitation), very quiet crackles on lung auscultation bilaterally, slightly increased respiratory effort, mild dental tartar, BCS 7/9, normal peripheral lymph nodes, liver palpates enlarged on abdominal palpation but no obvious masses visualized, abdomen comfortable on palpation Lab work: CBC/Chem 1/4/26 ALT high 155 ALP high 479 White blood cell high 17.9 Platelet count high at 499, increased estimate Neutrophils high 14,320 Monocytes high 1074

ULTRASONOGRAPHIC EXAMINATION OF THE ABDOMEN

Urinary System

The urinary bladder is moderately distended with anechoic urine. The Bladder wall, trigone, ureteral papillae and visible urethra (to a depth of 2cm) appear normal with no evidence of wall thickening, mucosal irregularities, masses or cystic calculi.

The prostate is normal in size (1.12 cm) and shape for this neutered male dog. The parenchyma is homogenous and the external margins are smooth. The prostatic urethra appears normal with no evidence of irregularity, invasion, mass effect or calculi.

The left kidney has a normal shape and size (4.32 cm). Overall echogenicity is normal with adequate corticomedullary distinction and a typical 1:3 cortex:medulla ratio. There is no evidence of focal perinephric inflammation or effusion. There is no evidence of pyelectasia, nephroliths, infarcts or hydronephrosis. Renal vasculature is normal.

The right kidney has a normal shape and size (4.43 cm). Overall echogenicity is normal with adequate corticomedullary distinction and a typical 1:3 cortex:medulla ratio. There is no evidence of focal perinephric inflammation or effusion. There is no evidence of pyelectasia, nephroliths, infarcts or hydronephrosis. Renal vasculature is normal.

Adrenal Glands

The left adrenal gland is normal in size measuring 0.51 cm at the cranial pole and 0.44 cm at the caudal pole. It is observed in its normal position cranial to the left renal artery. It is normal in appearance (uniformly hypoechoic) and shape with no evidence of a mass effect.

The right adrenal gland is normal in size measuring 0.68 cm at the cranial pole and 0.45 cm at the caudal pole. It is observed in its normal position between the cranial aspect of the right kidney and the caudal vena cava. It is normal in appearance (uniformly hypoechoic) and shape with no evidence of a mass effect.



PATIENT

Kit Haskins

SPECIES

Canine

BREED

Pug

SEX

Neutered Male

AGE

13 Years 8 Months

WEIGHT

20 lbs

INTERPRETED BY

Kathleen Sennello DVM,
MS, Diplomate ACVIM
(Small Animal Internal
Medicine)

IMAGING PERFORMED BY

Dr. Lucas Budden

HOSPITAL NAME

Frontier Veterinary
Hospital

REFERRING VET

Dr. Lucas Budden

INVOICE

72313

DATE

1/20/26

Spleen

The spleen is subjectively normal in size (0.98 cm), echotexture is homogenous, and the splenic capsule is smooth with no irregularities. The blood flow through the hilus and splenic parenchyma appears normal. No focal parenchymal abnormalities are visualized.

Liver

The liver is subjectively normal in size, and echogenicity with smooth peripheral margins. The parenchyma is heterogenous in echotexture with subtle, indistinct focal mottling. The visible portions of the vasculature and biliary tract appear normal. There is an isoechoic area of rounded liver in the mid right caudal liver adjacent to the gallbladder. I suspect this is normal anatomic variation. An isoechoic nodule cannot be ruled out. It measures 1.73 cm x 1.99 cm.

The gall bladder lumen is significantly distended. Some areas of the wall appear mildly thickened with adherent debris and some areas have early mucosal stranding and organization of the debris into an early mucocele. There is a large amount of primarily non-organized echogenic debris present as well. There is no evidence of bile duct dilation.

Gastrointestinal

The stomach contains minimal luminal contents. It measures at a normal thickness of <0.7cm with some variability due to the presence of rugal folds. The distinction of the gastric wall layers is adequate and there is no impression of reduced peristaltic activity. No masses or focal lesions were observed.

The visualized areas of duodenum, jejunum and ileum have a relatively uniform diameter with minimal fluid distension. Wall thickness is normal. Bowel loops follow a curvilinear path with distinct wall layering maintaining the typical 1:3 muscularis:mucosa layer ratio. Duodenum wall measures 0.45 cm. Jejunum wall measures 0.33 cm. Visualized peristalsis appears appropriate. There were no focal lesions consistent with obstruction or a mass effect observed.

Sections of colon are visualized with formed fecal material and gas shadowing distally. There is no observed focal or generalized colon wall thickening or loss of layering.

Pancreas

The left limb of the pancreas is visible/mildly mottled. There is no evidence of nodules or cystic lesions. There is no evidence of regional mesenteric inflammation or fluid.

Free Abdomen

Evaluation of the peritoneal cavity did not reveal any evidence of effusion, or subjective lymphadenomegaly. The Medial iliac nodes appear normal and there was no evidence of a caudal aortic thrombus at the bifurcation. The omentum is of normal uniform echogenicity.

ULTRASONOGRAPHIC FINDINGS

- Pancreatic changes consistent with mild pancreatic remodeling in the left limb.
- Mildly heterogeneous liver with an isoechoic rounded area – Findings are most consistent with a mild vacuolar hepatopathy and an isoechoic “bulge” of the right mid liver. Other hepatopathies are possible. An early mass lesion (adenoma, carcinoma, other) is possible.



PATIENT

Kit Haskins

SPECIES

Canine

BREED

Pug

SEX

Neutered Male

AGE

13 Years 8 Months

WEIGHT

20 lbs

INTERPRETED BY

Kathleen Sennello DVM,
MS, Diplomate ACVIM
(Small Animal Internal
Medicine)

IMAGING PERFORMED BY

Dr. Lucas Budden

HOSPITAL NAME

Frontier Veterinary
Hospital

REFERRING VET

Dr. Lucas Budden

INVOICE

72313

DATE

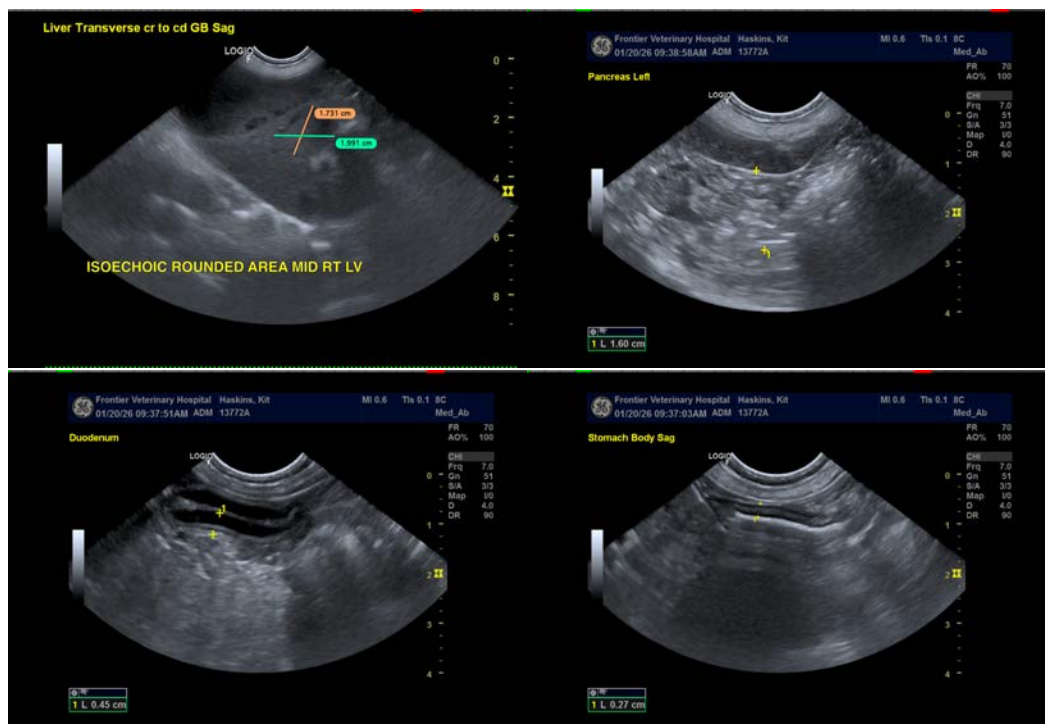
1/20/26

- Large amount of disorganized debris visualized within the gallbladder with some debris organizing into an early mucocele – The gall bladder changes are most consistent with a developing mucocele. Consider medical management and close monitoring for progression of this lesion.

INTERPRETATION OF THE FINDINGS & FURTHER RECOMMENDATIONS

There is a developing mucocele visualized associated with the gallbladder. Recommend initiating Ursodiol therapy and continued monitoring for progression, which could indicate the need for possible surgical intervention. There is no evidence of associated inflammation at this time.

The liver appears subjectively mildly heterogeneous. This could be consistent with a mild vacuolar hepatopathy. Although the systemic impacts of inhaled steroids are minimal, there could be a minor effect increasing the ALP level. The isoechoic “bulge” described is not in an area that would be easy to sample. If further evaluation of the liver is desired, you could consider a liver function test and a fine needle aspirate of the genera parenchyma. Consider continued monitoring of the rounded area of liver as well as the gallbladder (recheck in 8-12 weeks, sooner if concerned).





PATIENT

Kit Haskins

SPECIES

Canine

BREED

Pug

SEX

Neutered Male

AGE

13 Years 8 Months

WEIGHT

20 lbs

INTERPRETED BY

Kathleen Sennello DVM,
MS, Diplomate ACVIM
(Small Animal Internal
Medicine)

IMAGING PERFORMED BY

Dr. Lucas Budden

HOSPITAL NAME

Frontier Veterinary
Hospital

REFERRING VET

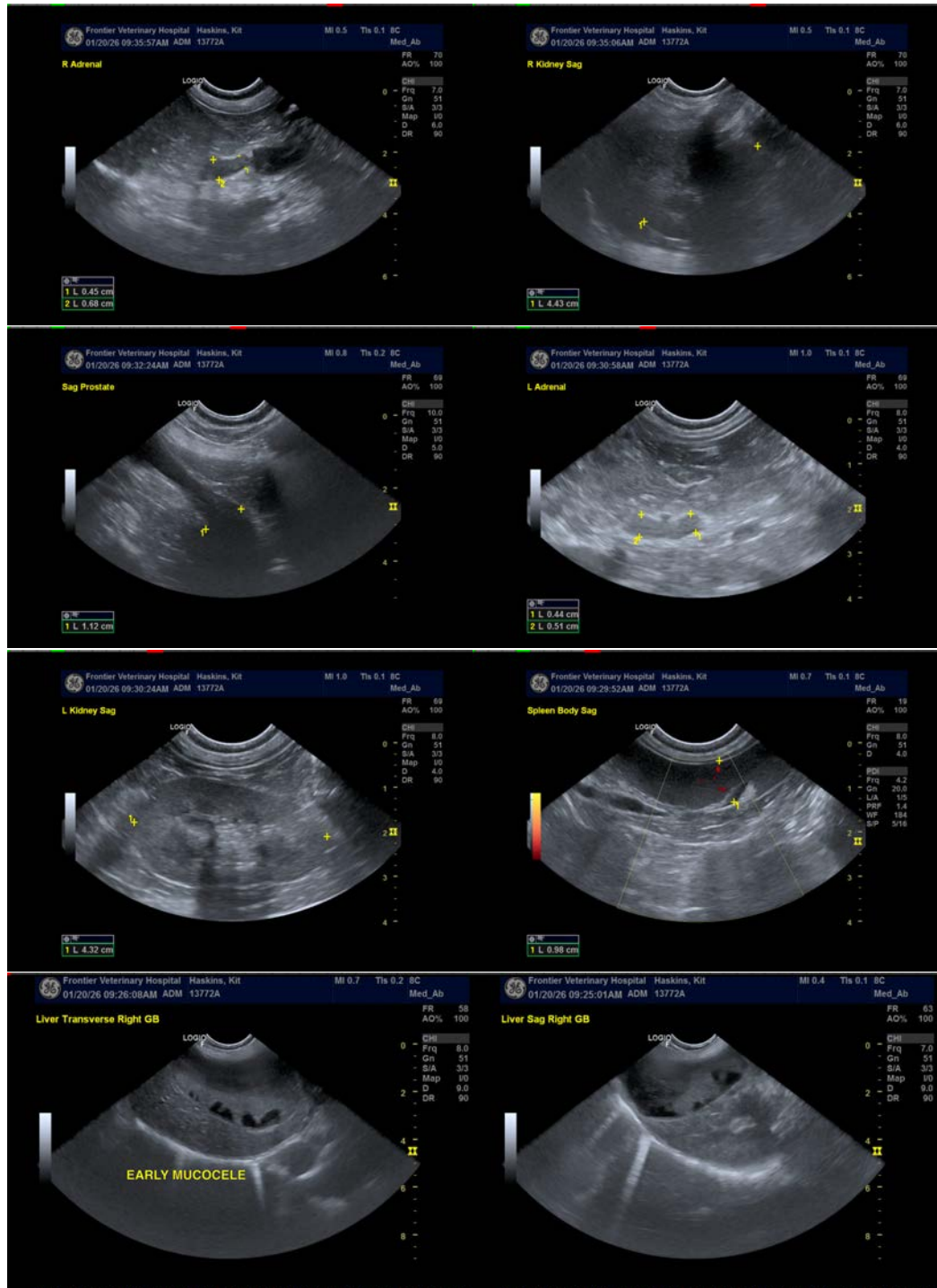
Dr. Lucas Budden

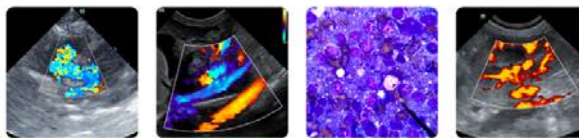
INVOICE

72313

DATE

1/20/26





PATIENT

Kit Haskins

SPECIES

Canine

BREED

Pug

SEX

Neutered Male

AGE

13 Years 8 Months

WEIGHT

20 lbs

INTERPRETED BY

Kathleen Sennello DVM,
MS, Diplomate ACVIM
(Small Animal Internal
Medicine)

IMAGING PERFORMED BY

Dr. Lucas Budden

HOSPITAL NAME

Frontier Veterinary
Hospital

REFERRING VET

Dr. Lucas Budden

INVOICE

72313

DATE

1/20/26

The information and recommendations provided are based on the images presented by the referring veterinarian/sonographer. No evaluation can be communicated regarding pathology that was not visible in the image/video clips provided.

Thank you for this referral. If the clinical or image interpretation does not parallel your findings or if I can be of any further assistance please contact me.

Kathleen Sennello DVM,MS, Diplomate ACVIM (Small animal Internal Medicine)

info@sonopath.com