



PATIENT

Goofy Alcaresz

SPECIES

Canine

BREED

Yorkie x

SEX

Neutered Male

AGE

16 Years

WEIGHT

8.3 kg

INTERPRETED BY

Kathleen Sennello DVM,
MS, Diplomate ACVIM
(Small Animal Internal
Medicine)

IMAGING PERFORMED BY

Carlie Kolttek, RVT

HOSPITAL NAME

Tuxedo Animal
Hospital

REFERRING VET

Dr. Kristin Buchanan

INVOICE

72320

DATE

1/20/26

PRESENTING CLINICAL SIGNS

- Weight loss present - was 10.5kg in April 2024 (last time here)
- Has been progressively PU/PD over the last 6 months
- Would like to try to find reason for PU/PD, kidney values mildly elevated, but might be from concurrent UTI.
- **Dog kept urinating during scan - injected sterile saline into urinary bladder to dilate for better imaging/interpretation, but continued to urinate immediately after**

Abnormal PE/Chem/CBC/UA Results: Heart and lungs : grade 1 systolic murmur Grade 4 dental disease no palpable prostate enlargement non-painful abdominal palpation CBC: RBC 5.27 (5.65 - 8.87 x10¹²/L) HCT 0.355 (0.373 - 0.617 L/L) HGB 128 (131 - 205 g/L) Plateletcrit (0.57 0.14 - 0.46 %) CHEM: CREA 164 (44 - 159 μmol/L) BUN 18.2 (2.5 - 9.6 mmol/L) GLOB 48 (25 - 45 g/L)

ULTRASONOGRAPHIC EXAMINATION OF THE ABDOMEN

Urinary System

The urinary bladder is mildly distended with urine. The Bladder wall appears diffusely thickened and irregular, particularly in the apical region, where it measures at 1.18 cm in thickness. In the dorsal wall of the urinary bladder there is a focal irregular, shadowing, mineralized structure that could represent a stone with associated irregular tissue or possibly a mineralized mass effect/polyp. This measures 0.41 cm x 0.60 cm.

The prostate is prominent, measuring 1.07 cm.

The left kidney has a normal shape and size (4.78 cm) with occasional cortical mineralizations and cysts. There is pyelectasia at 0.29 cm. Overall echogenicity is slightly hyperechoic with mildly reduced corticomedullary distinction and a typical 1:3 cortex:medulla ratio. There is no evidence of focal perinephric inflammation or effusion. There is no evidence of infarcts or hydroureter. Renal vasculature is normal.

The right kidney has a normal shape and size (4.61 cm) with cortical medullary mineralization, and moderate pyelectasia at 0.64 cm. Overall echogenicity is slightly hyperechoic with mildly reduced corticomedullary distinction and a typical 1:3 cortex:medulla ratio. There is no evidence of focal perinephric inflammation or effusion. There is no evidence of infarcts or hydroureter. Renal vasculature is normal.

Adrenal Glands

The left adrenal gland is large, measuring 0.93 cm at the cranial pole and 1.08 cm at the caudal pole. It is observed in its normal position cranial to the left renal artery. It is normal in appearance (uniformly hypoechoic) and shape with no evidence of a mass effect.

The region of the right adrenal gland is evaluated. The exact margins of the adrenal are difficult to visualize, but it generally appears of normal shape and size/borderline "plump" (?). No evidence of a definitive mass effect visualized.



PATIENT

Goofy Alcaresz

SPECIES

Canine

BREED

Yorkie x

SEX

Neutered Male

AGE

16 Years

WEIGHT

8.3 kg

INTERPRETED BY

Kathleen Sennello DVM,
MS, Diplomate ACVIM
(Small Animal Internal
Medicine)

IMAGING PERFORMED BY

Carlie Kolttek, RVT

HOSPITAL NAME

Tuxedo Animal
Hospital

REFERRING VET

Dr. Kristin Buchanan

INVOICE

72320

DATE

1/20/26

Spleen

The spleen is subjectively normal in size (0.97 cm), echotexture is homogenous, and the splenic capsule is smooth with no irregularities. The blood flow through the hilus and splenic parenchyma appears normal. No focal parenchymal abnormalities are visualized.

Liver

The liver is subjectively normal in size, and echogenicity with smooth peripheral margins. The parenchyma is mildly heterogenous in echotexture with subtle, indistinct focal mottling. The visible portions of the vasculature and biliary tract appear normal. No focal nodules or cystic lesions are observed.

The gall bladder lumen is moderately distended. The wall of the gall bladder is not thickened and has a smooth mucosal surface. There is a moderate amount of non-organized echogenic debris. Some of the debris visualized is consistent with mineralized sandy debris/small stones. The cystic and common bile ducts are normal/not visible.

Gastrointestinal

The stomach contains minimal luminal contents. It measures at a normal thickness of <0.7cm with some variability due to the presence of rugal folds. The distinction of the gastric wall layers is adequate and there is no impression of reduced peristaltic activity. No masses or focal lesions were observed.

The visualized areas of duodenum, jejunum and ileum have a relatively uniform diameter with minimal fluid distension. Wall thickness is normal. Bowel loops follow a curvilinear path with distinct wall layering maintaining the typical 1:3 muscularis:mucosa layer ratio. Duodenum wall measures 0.33 cm. Jejunum wall measures 0.31 cm. Visualized peristalsis appears appropriate. There were no focal lesions consistent with obstruction or a mass effect observed.

Sections of colon are visualized with formed fecal material and gas shadowing distally. The descending colon wall is somewhat prominent with intact wall layering, measuring at 0.28 cm.

Pancreas

The area of the pancreas is normal and isoechoic to surrounding mesentery. There is no evidence of nodules or cystic lesions. There is no evidence of regional mesenteric inflammation or fluid.

Free Abdomen

Evaluation of the peritoneal cavity did not reveal any evidence of effusion, or subjective lymphadenomegaly. The Medial iliac nodes appear normal and there was no evidence of a caudal aortic thrombus at the bifurcation. The omentum is of normal uniform echogenicity.

PRIMARY FINDINGS

- Mildly distended urinary bladder with wall thickening and irregularity and a focal hyperechoic shadowing structure (stone versus mineralized tissue).
- Large left adrenal gland – Findings could be consistent with hyperplasia, less likely an early mass effect, etc.



PATIENT

Goofy Alcares

SPECIES

Canine

BREED

Yorkie x

SEX

Neutered Male

AGE

16 Years

WEIGHT

8.3 kg

INTERPRETED BY

Kathleen Sennello DVM,
MS, Diplomate ACVIM
(Small Animal Internal
Medicine)

IMAGING PERFORMED BY

Carlie Koltsek, RVT

HOSPITAL NAME

Tuxedo Animal
Hospital

REFERRING VET

Dr. Kristin Buchanan

INVOICE

72320

DATE

1/20/26

- Age related changes visualized associated with both kidneys, including bilateral pyelectasia – Pyelectasia of the kidney(s) could be consistent with pyelonephritis, chronic renal disease, secondary to PU/PD or fluid therapy (if applicable), other.
- Mildly heterogeneous liver – The diffuse hepatic changes are non-specific and could be consistent with vacuolar hepatopathy, nodular hyperplasia, inflammatory/immune-mediated disease, fibrosis, extramedullary hematopoiesis, toxic hepatopathy (e.g., copper), infiltrative neoplasia (less likely) or other hepatopathy.
- Moderate gallbladder debris with mineralized debris/small stones – The significance of the aggregated gallbladder debris is unclear. This could represent an early mucocele, cholestasis, or may be secondary to fasting but seems unlikely to be causing a current issue. Recommend continued monitoring.
- Prominent/thickened colon wall – Findings could be consistent with mild colitis.

SECONDARY FINDINGS

- Prominent prostate – Findings could be normal for a patient neutered after puberty. Recommend continued monitoring.

INTERPRETATION OF THE FINDINGS & FURTHER RECOMMENDATIONS

There is significant thickening and irregularity of the bladder wall. The bladder is not significantly distended, so full evaluation and interpretation is limited. Recommend a urine culture and a urinalysis, looking for possible severe cystitis. Additionally, there is bilateral pyelectasia, which could be an indicator of concurrent pyelonephritis. If there is no evidence of an active infection, then consider a traumatic catheterization of the bladder wall for cytologic evaluation, looking for a possible underlying neoplastic process. There is a focal shadowing structure visualized in the dorsal wall of the urinary bladder. At this time, it is difficult to differentiate a possible mineralized mass effect or a stone with associated irregular inflammatory tissue. If cystitis is present, consider reevaluation of the urinary bladder after treatment, as antibiotics should be continued until the bladder wall normalizes.

The left adrenal gland is large, and the margins of the right adrenal gland are difficult to clearly visualize. These changes could be consistent with bilateral hyperplasia or even an early mass effect visualized associated with the left adrenal gland. If signs of Cushing's are present, you could consider adrenal function testing, ideally after the bladder issues are resolved to try to prevent false positives secondary to concurrent illness.

There is a moderate amount of debris visualized within the gallbladder and some mineralized debris. Consider starting chronic Ursodiol therapy and continued monitoring of the gallbladder over time. The liver is mildly heterogeneous. This could be incidental, particularly if liver values are normal. Continued monitoring for the development of focal lesions or changes is recommended.



PATIENT

Goofy Alcares

SPECIES

Canine

BREED

Yorkie x

SEX

Neutered Male

AGE

16 Years

WEIGHT

8.3 kg

INTERPRETED BY

Kathleen Sennello DVM,
MS, Diplomate ACVIM
(Small Animal Internal
Medicine)

**IMAGING
PERFORMED BY**

Carlie Kolttek, RVT

HOSPITAL NAME

Tuxedo Animal
Hospital

REFERRING VET

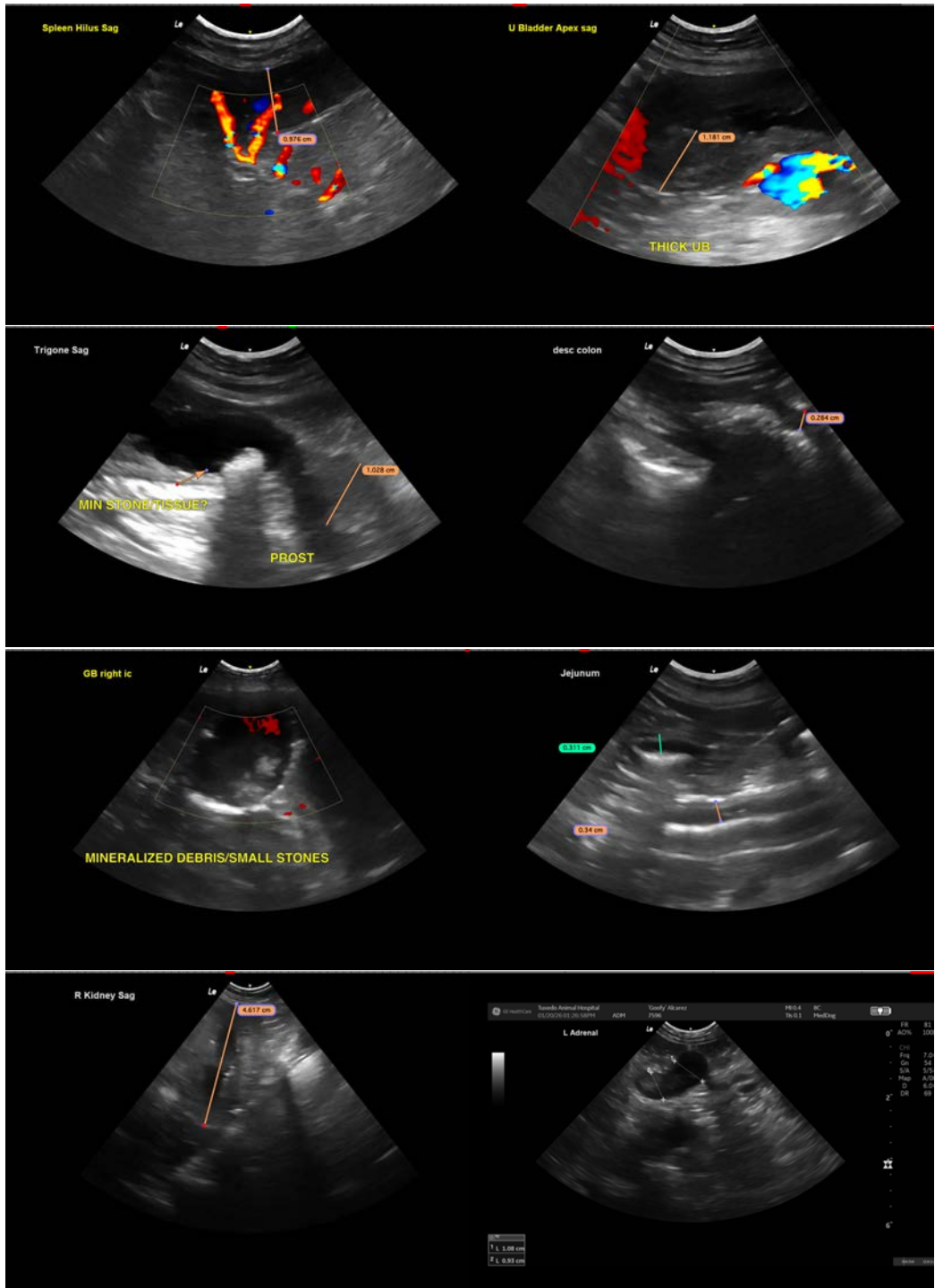
Dr. Kristin Buchanan

INVOICE

72320

DATE

1/20/26





PATIENT

Goofy Alcares

SPECIES

Canine

BREED

Yorkie x

SEX

Neutered Male

AGE

16 Years

WEIGHT

8.3 kg

INTERPRETED BY

Kathleen Sennello DVM,
MS, Diplomate ACVIM
(Small Animal Internal
Medicine)

IMAGING PERFORMED BY

Carlie Koltek, RVT

HOSPITAL NAME

Tuxedo Animal
Hospital

REFERRING VET

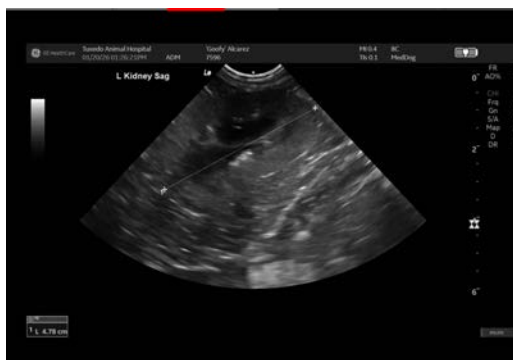Dr. Kristin Buchanan

INVOICE

72320

DATE

1/20/26



The information and recommendations provided are based on the images presented by the referring veterinarian/sonographer. No evaluation can be communicated regarding pathology that was not visible in the image/video clips provided.

Thank you for this referral. If the clinical or image interpretation does not parallel your findings or if I can be of any further assistance please contact me.

Kathleen Sennello DVM,MS, Diplomate ACVIM (Small animal Internal Medicine)

info@sonopath.com