

IMAGING PERFORMED BY

IntraPet.com



**SonoPath**

Clinical Sonography & Telecytology

EDUCATIONAL TELECONSULTATION SERVICES™

1-800-838-4268 info@sonopath.com SonoPath.com

**DATE PRESENTING CLINICAL SIGNS**

1/20/22 History: Pet ate the rubber end of a curtain rod on Monday Jan 10.  
Owner is sure that he has not pooped it out. No vomiting or diarrhea noted, and he is eating normally.

**PATIENT**

Colin Alexander

Lab Results: cbc/chem done Oct 2021 was normal.  
Date of Previous IntraPet Ultrasound: No previous IntraPet scans.  
Sedation: Not required to complete full diagnostic ultrasound.  
Stat Report: Requested/Approved.

**SPECIES**

Canine

**ULTRASONOGRAPHIC EXAMINATION OF THE ABDOMEN**

**BREED**

Yorkie

**Urinary System**

The urinary bladder is moderately distended with anechoic urine. The Bladder wall, trigone, ureteral papillae and visible urethra (to a depth of 2cm) appear normal with no evidence of wall thickening, mucosal irregularities, masses or cystic calculi.

**SEX**

Neutered Male

The prostate is normal in size (0.69 cm) and shape for this neutered male dog. The parenchyma is homogenous and the external margins are smooth. The prostatic urethra appears normal with no evidence of irregularity, invasion, mass effect or calculi.

**AGE**

9/10/09

The left kidney has a normal shape and size (3.83 cm) with small non-obstructive nephroliths. Overall echogenicity is slightly hyperechoic with poor corticomedullary distinction and a typical 1:3 cortex:medulla ratio. There is no evidence of perinephric inflammation or effusion. There is no evidence of pyelectasia, infarcts or hydronephrosis. Renal vasculature is normal.

**WEIGHT**

11.5 Pounds

The right kidney has a normal shape and size (4.33 cm) with non-obstructive nephroliths. Overall echogenicity is slightly hyperechoic with poor corticomedullary distinction and a typical 1:3 cortex:medulla ratio. There is no evidence of perinephric inflammation or effusion. There is no evidence of pyelectasia, infarcts or hydronephrosis. Renal vasculature is normal.

**INTERPRETED BY**

Kathleen Sennello DVM,  
MS, Diplomate ACVIM  
(Small Animal Internal  
Medicine)

**Adrenal Glands**

The left adrenal gland is normal in size measuring 0.45 cm at the caudal pole. It is observed in its normal position cranial to the left renal artery. It is normal in appearance (uniformly hypoechoic) and shape with no evidence of a mass effect.

**IMAGING PERFORMED BY**

Stephanie Pearce  
RDMS, RVT

The right adrenal gland is normal in size measuring 0.47 cm at the caudal pole. It is observed in its normal position between the cranial aspect of the right kidney and the caudal vena cava. It is normal in appearance (uniformly hypoechoic) and shape with no evidence of a mass effect.

**HOSPITAL NAME**

BPH of White Marsh

**Spleen**

The spleen is subjectively normal in size, echotexture is homogenous, and the splenic capsule is smooth with no irregularities. The blood flow through the hilus and splenic parenchyma appears normal. No focal parenchymal abnormalities are visualized.

**REFERRING VET**

Dr. Esdaile

**Liver**

The liver is subjectively normal in size, and echogenicity with smooth peripheral margins. The parenchyma is homogenous echotexture. The visible portions of the vasculature and biliary tract appear normal. No focal nodules or cystic lesions are observed.

**INVOICE**

34383

The gallbladder lumen is moderately distended. The wall of the gall bladder is not thickened and has a smooth mucosal surface. Luminal contents are primarily anechoic. The cystic and common bile ducts are normal/not visible.

### ***Gastrointestinal***

The stomach is minimally distended with ingesta. The gastric wall appears normal, measuring <0.7 cm in thickness with intact layering. There is an intraluminal shadowing foreign body visualized, which is distinctly rounded, likely consistent with the reported rubber stopper recently ingested. There is no evidence of current obstruction or gastric lesions.

The visualized areas of duodenum, jejunum and ileum have a relatively uniform diameter with minimal fluid distension. Wall thickness is normal. Bowel loops follow a curvilinear path with distinct wall layering maintaining the typical 1:3 muscularis:mucosa layer ratio. Jejunum wall measured 0.28 cm. Visualized peristalsis appears appropriate. There were no focal lesions consistent with obstruction or a mass effect observed.

The ileocecal junction was visualized and exhibited normal intact wall layering and is subjectively of normal thickness. Sections of colon are visualized with formed fecal material and gas shadowing distally. There is no observed focal or generalized colon wall thickening or loss of layering.

### ***Pancreas***

The pancreas is normal and isoechoic to surrounding mesentery. There is no evidence of nodules or cystic lesions. There is no evidence of regional mesenteric inflammation or fluid.

### ***Free Abdomen***

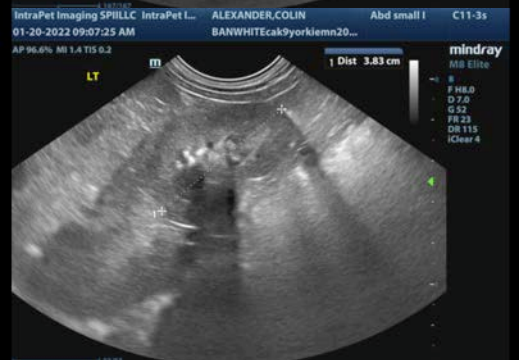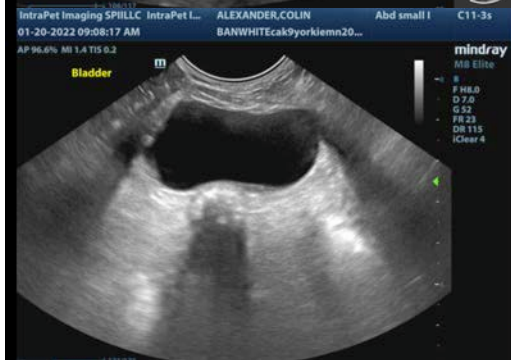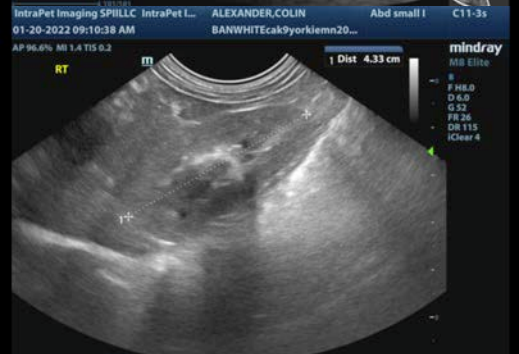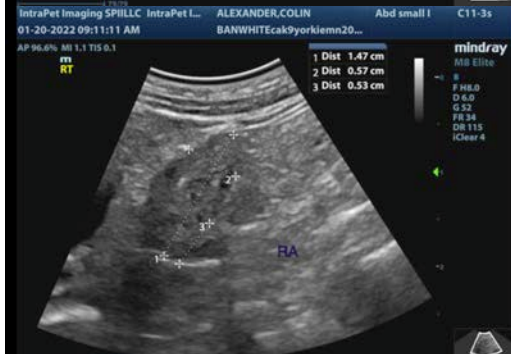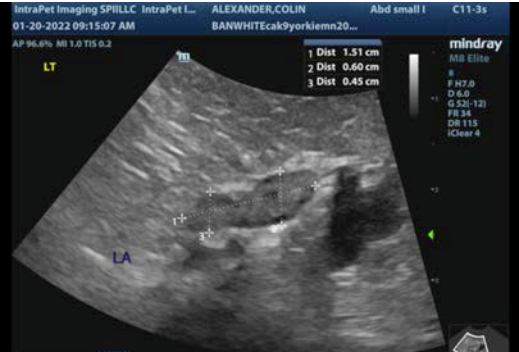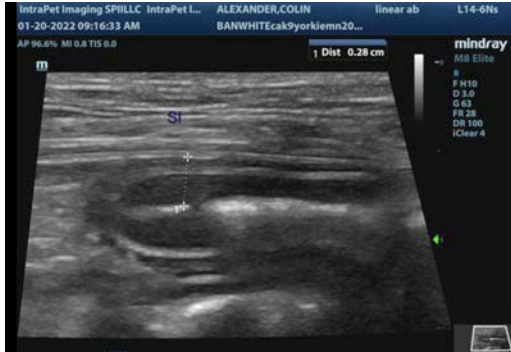Evaluation of the peritoneal cavity did not reveal any evidence of effusion, or subjective lymphadenomegaly. The Medial iliac nodes appear normal and there was no evidence of a caudal aortic thrombus at the bifurcation. The omentum is of normal uniform echogenicity.

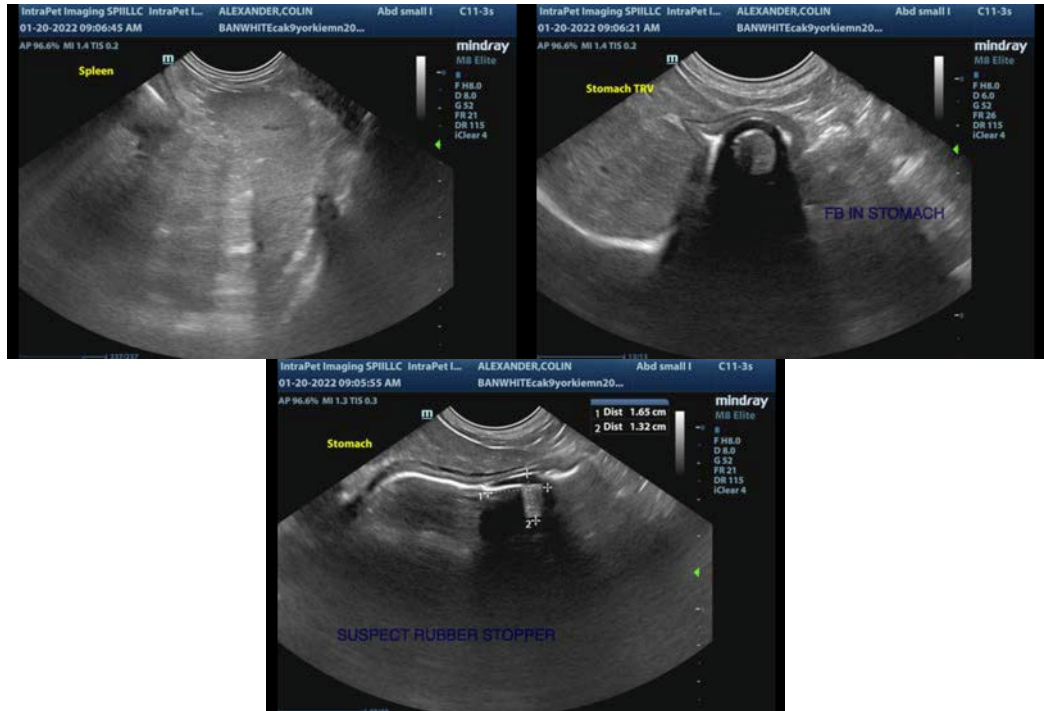
## **ULTRASONOGRAPHIC FINDINGS**

- Gastric foreign body visualized – There is no evidence of a current obstruction, but a distinct foreign object is visualized.
- Decreased corticomedullary distinction in both kidneys with small non-obstructive nephroliths – The bilateral renal findings are consistent with age-related change.

## **INTERPRETATION OF THE FINDINGS & FURTHER RECOMMENDATIONS**

There is a distinct structure visualized within the gastric lumen, most consistent with the suspected rubber stopper that was ingested. Based on the nature of the object, you could consider inducing emesis, upper GI endoscopy, or gastrotomy. I suspect this material is too large to pass, but it is difficult to say for sure.





The information and recommendations provided are based on the images presented by the referring veterinarian. No evaluation can be communicated regarding pathology that was not visible in the image/video clips provided.

Thank you for this referral. If the clinical or image interpretation does not parallel your findings or if I can be of any further assistance please contact me.

Kathleen Sennello DVM,MS, Diplomate ACVIM (Small animal Internal Medicine)  
kathleen.sennello@sonopath.com