



PATIENT

Simba Theodore Toole

SPECIES

Feline

BREED

DLH

SEX

Neutered Male

AGE

11 Years

WEIGHT

6.7 kg

INTERPRETED BY

Kathleen Sennello DVM,
MS, Diplomate ACVIM
(Small Animal Internal
Medicine)

IMAGING PERFORMED BY

Kari Wilson, DVM

HOSPITAL NAME

Animal Emergency
Hospital Deland

REFERRING VET

Kari Wilson, DVM

INVOICE

72907

DATE

1/2/26

PRESENTING CLINICAL SIGNS

Patient has a history of on and off urinary issues. he started to strain last night with little urine production. he is now vomiting. Pet hospitalized.

Abnormal PE/Chem/CBC/UA Results: CBC. NSF Chemistry. calcium 7.7 EPOC. potassium 3.1, BE -6.8
Other: UA. spg > 1.050, proteinuria, cocci, hematuria, pyuria. no crystals noted FpLi. abnormal
Radiograph conclusion : CONCLUSIONS: Small left kidney. This is likely related to chronic kidney
disease. There is no evidence of significant urinary bladder distention or mineral opaque urinary bladder
calculi. Splenomegaly. This is a nonspecific finding and could represent normal individual variation.
Alternative differentials for splenomegaly include congestion, inflammation (splenitis caused by
toxoplasmosis, hemobartonella, or FIP), hyperplasia, extramedullary hematopoiesis or neoplasia. The
mild bronchial pattern is suggestive of lower airway disease.

ULTRASONOGRAPHIC EXAMINATION OF THE ABDOMEN

Urinary System

The urinary bladder is subjectively mildly overdistended with anechoic urine. The Bladder wall, trigone, ureteral papillae and visible urethra (to a depth of 2cm) appear normal with no evidence of wall thickening, mucosal irregularities, masses or cystic calculi.

The left kidney is normal in size but slightly irregular in shape (likely due to previous infarct at the cranial pole), measuring 3.81 cm. The cortex is increased in echogenicity with adequate corticomedullary distinction and a typical 1:3 cortex:medulla ratio. There is no evidence of focal perinephric inflammation or effusion. There is no evidence of pyelectasia, nephroliths, infarcts or hydroureter. Renal vasculature is normal.

The right kidney has a normal shape and size (4.19 cm). The cortex is increased in echogenicity with adequate corticomedullary distinction and a typical 1:3 cortex:medulla ratio. There is no evidence of focal perinephric inflammation or effusion. There is no evidence of pyelectasia, nephroliths, infarcts or hydroureter. Renal vasculature is normal.

Adrenal Glands

The region of left adrenal (Cranial to left renal artery) is unremarkable but the adrenal is not distinctly visualized. No evidence of a mass effect is visualized.

The right adrenal gland is normal in size measuring 0.40 cm at the caudal pole. It is observed in its normal position between the cranial aspect of the right kidney and the caudal vena cava. It is normal in appearance (uniformly hypoechoic) and shape with no evidence of a mass effect.

Spleen

The spleen is subjectively normal in size (0.96 cm), echotexture is homogenous, and the splenic capsule is smooth with no irregularities. The blood flow through the hilus and splenic parenchyma appears normal. No focal parenchymal abnormalities are visualized.



PATIENT

Simba Theodore Toole

SPECIES

Feline

BREED

DLH

SEX

Neutered Male

AGE

11 Years

WEIGHT

6.7 kg

INTERPRETED BY

Kathleen Sennello DVM,
MS, Diplomate ACVIM
(Small Animal Internal
Medicine)

IMAGING PERFORMED BY

Kari Wilson, DVM

HOSPITAL NAME

Animal Emergency
Hospital Deland

REFERRING VET

Kari Wilson, DVM

INVOICE

72907

DATE

1/2/26

Liver

The liver is subjectively normal in size, and echogenicity with smooth peripheral margins. The parenchyma is homogenous echotexture. The visible portions of the vasculature and biliary tract appear normal. No focal nodules or cystic lesions are observed.

The gall bladder lumen is moderately distended. The wall of the gall bladder is not thickened and has a smooth mucosal surface. Luminal contents are mild and likely incidental at this time. The cystic and common bile ducts are normal/not visible.

Gastrointestinal

The stomach contains minimal luminal contents. It measures at a normal thickness of <0.36cm with some variability due to the presence of rugal folds. The distinction of the gastric wall layers is adequate and there is no impression of reduced peristaltic activity. No masses or focal lesions were observed.

The visualized areas of duodenum, jejunum and ileum have a relatively uniform diameter with minimal fluid distension. Wall thickness is normal. Bowel loops follow a curvilinear path with distinct wall layering maintaining the typical 1:3 muscularis:mucosa layer ratio. Jejunum wall measures 0.21 cm. Visualized peristalsis appears appropriate. There were no focal lesions consistent with obstruction or a mass effect observed.

Sections of colon are visualized with formed fecal material and gas shadowing distally. There is no observed focal or generalized colon wall thickening or loss of layering.

Pancreas

The area of the pancreas is normal and isoechoic to surrounding mesentery. There is no evidence of nodules or cystic lesions. There is no evidence of regional mesenteric inflammation or fluid.

Free Abdomen

Evaluation of the peritoneal cavity did not reveal any evidence of effusion. There is no evidence of a significant mesenteric lymphadenopathy. A prominent gastric lymph node is visualized measuring 0.58 cm x 1.33 cm. The omentum is normal in echogenicity.

ULTRASONOGRAPHIC FINDINGS

- Mildly irregular left kidney – Findings are likely due to a previous infarct in the cranial pole.
- Prominent gastric lymph node – This likely represents a reactive lymph node.

INTERPRETATION OF THE FINDINGS & FURTHER RECOMMENDATIONS

No focal lesions are visualized to explain the lower urinary tract symptoms described. Unfortunately, there are many causes for lower urinary tract symptoms (mucus plugs, stricture, cystitis, small urethral calculi, etc.), which cannot be diagnosed by ultrasound alone. Correlate findings with urine culture and consider gently passing a red rubber catheter to ensure urethral patency. The urinary bladder appears somewhat overdistended, but this could be due to not wanting to urinate in the hospital(?) versus being unable to urinate. If an obstruction is ruled out, then consider treatment for interstitial cystitis while awaiting culture results, with close monitoring of urine production.



PATIENT

Simba Theodore Toole

SPECIES

Feline

BREED

DLH

SEX

Neutered Male

AGE

11 Years

WEIGHT

6.7 kg

INTERPRETED BY

Kathleen Sennello DVM,
MS, Diplomate ACVIM
(Small Animal Internal
Medicine)

**IMAGING
PERFORMED BY**

Kari Wilson, DVM

HOSPITAL NAME

Animal Emergency
Hospital Deland

REFERRING VET

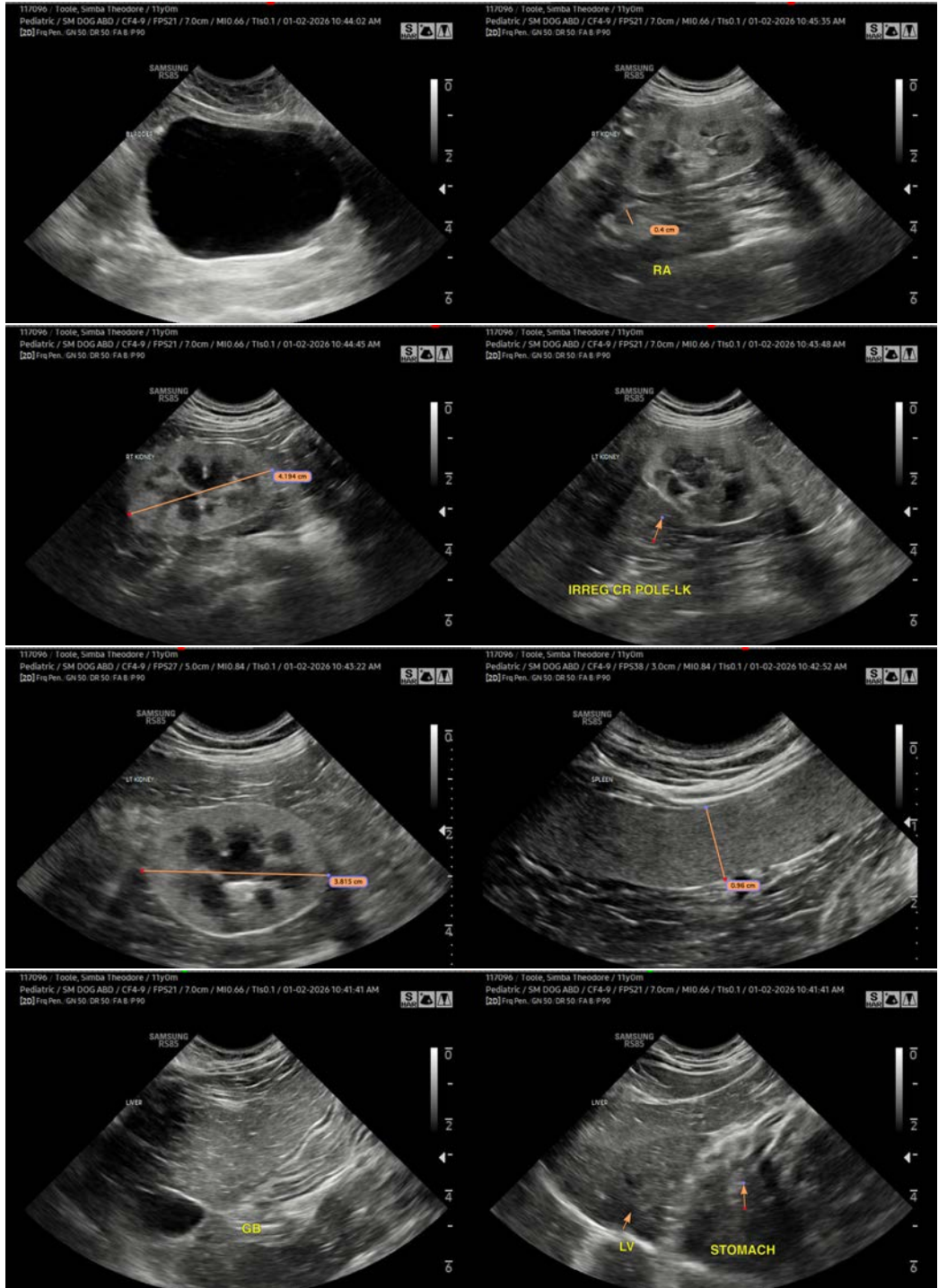
Kari Wilson, DVM

INVOICE

72907

DATE

1/2/26





PATIENT

Simba Theodore Toole

SPECIES

Feline

BREED

DLH

SEX

Neutered Male

AGE

11 Years

WEIGHT

6.7 kg

INTERPRETED BY

Kathleen Sennello DVM,
MS, Diplomate ACVIM
(Small Animal Internal
Medicine)

IMAGING PERFORMED BY

Kari Wilson, DVM

HOSPITAL NAME

Animal Emergency
Hospital Deland

REFERRING VET

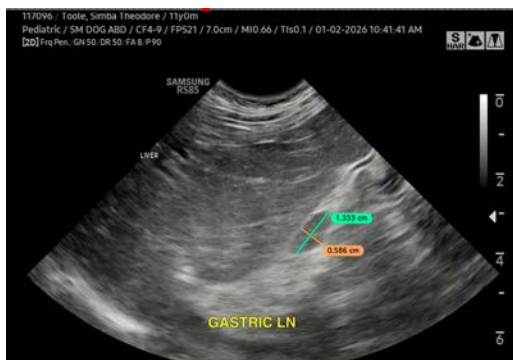
Kari Wilson, DVM

INVOICE

72907

DATE

1/2/26



The information and recommendations provided are based on the images presented by the referring veterinarian/sonographer. No evaluation can be communicated regarding pathology that was not visible in the image/video clips provided.

Thank you for this referral. If the clinical or image interpretation does not parallel your findings or if I can be of any further assistance please contact me.

Kathleen Sennello DVM,MS, Diplomate ACVIM (Small animal Internal Medicine)

info@sonopath.com